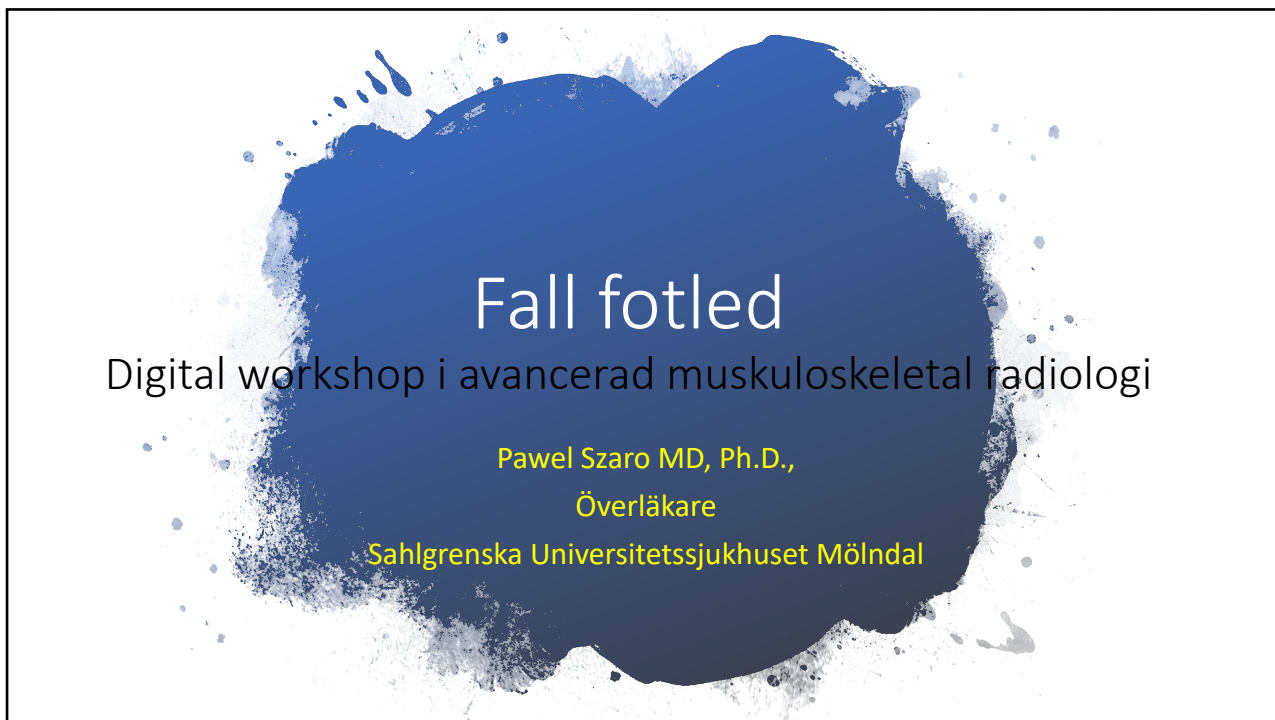



1



2

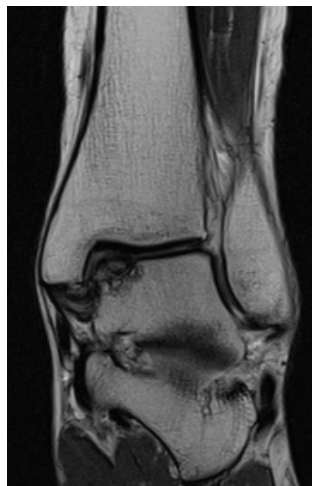Diagnosis?

- A. AVN
- B. OCD
- C. subchondral fracture
- D. stress/insufficiency fracture

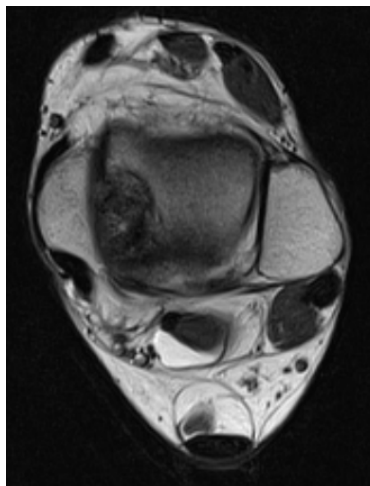
3

OCD

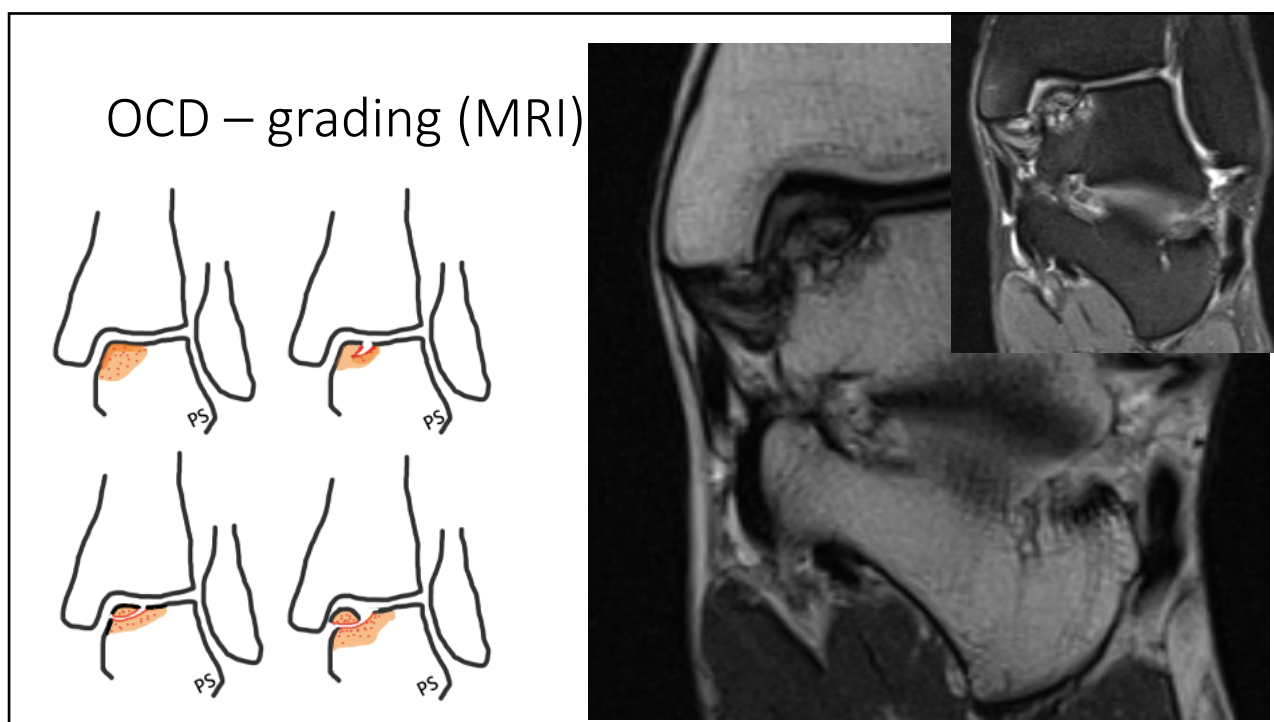
- posteromedial**
- deeper
 - cup-shaped



- anterolateral**
- shallower
 - wafer-shaped



4

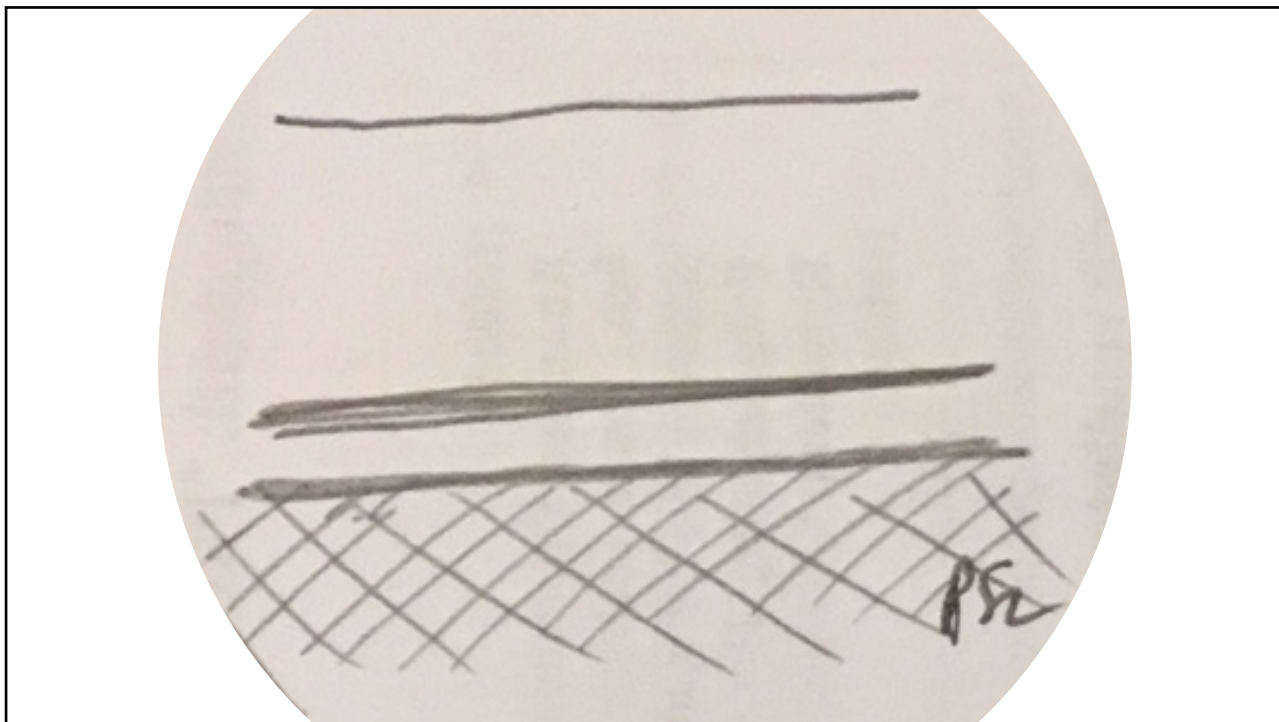


5

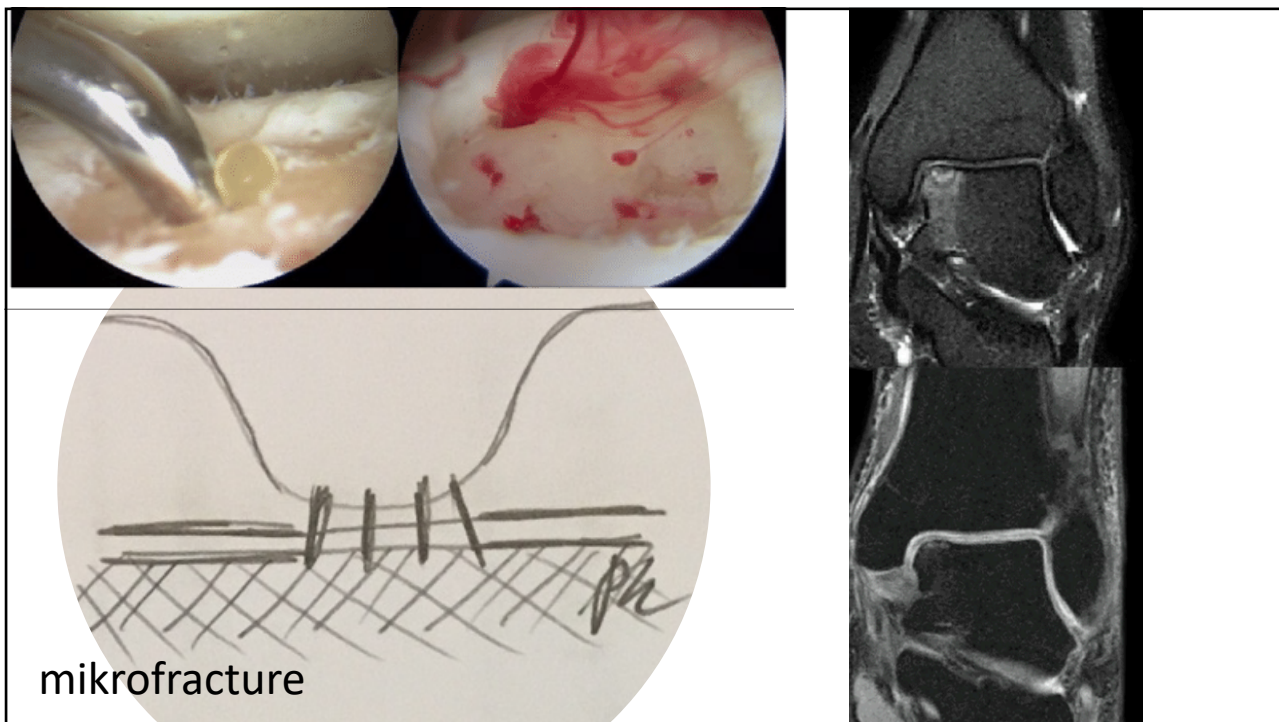
Utlåtande

- lokalisering
- storlek i 2D
- Stabil eller inte?
 - vuxna
 - barn
- subchondral reaktion
 - bme
 - cysor

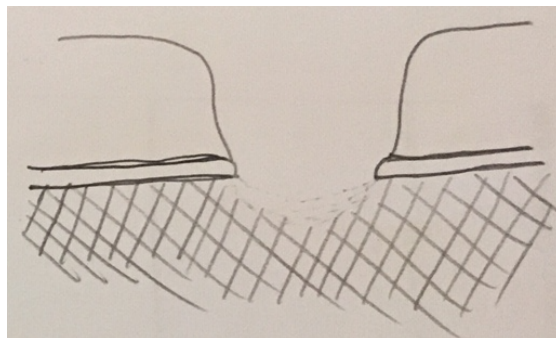
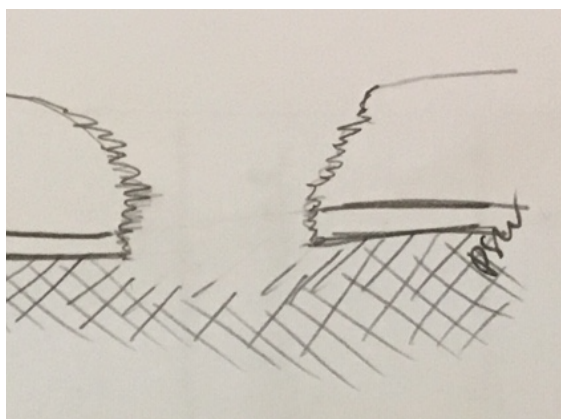
6



7

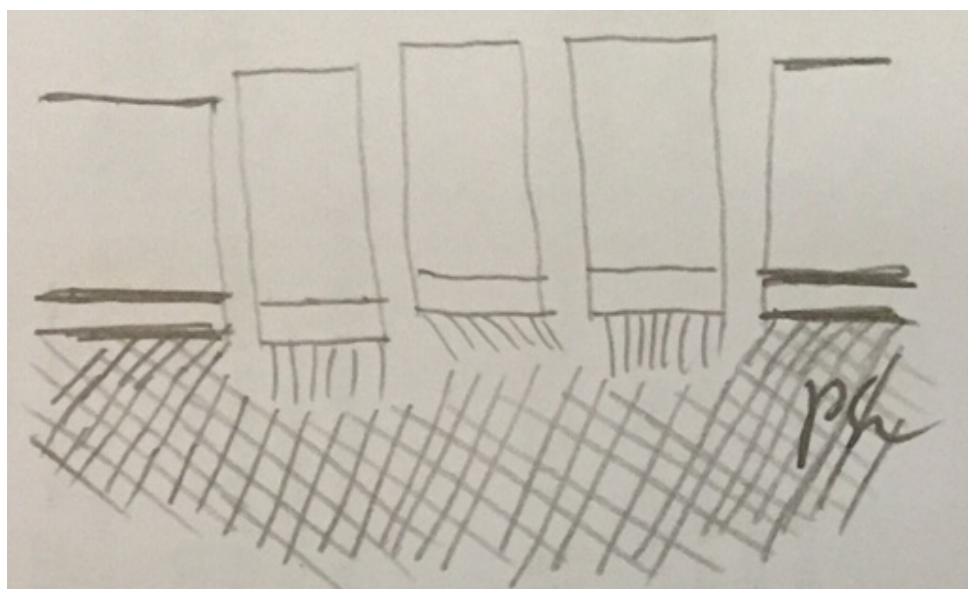


8

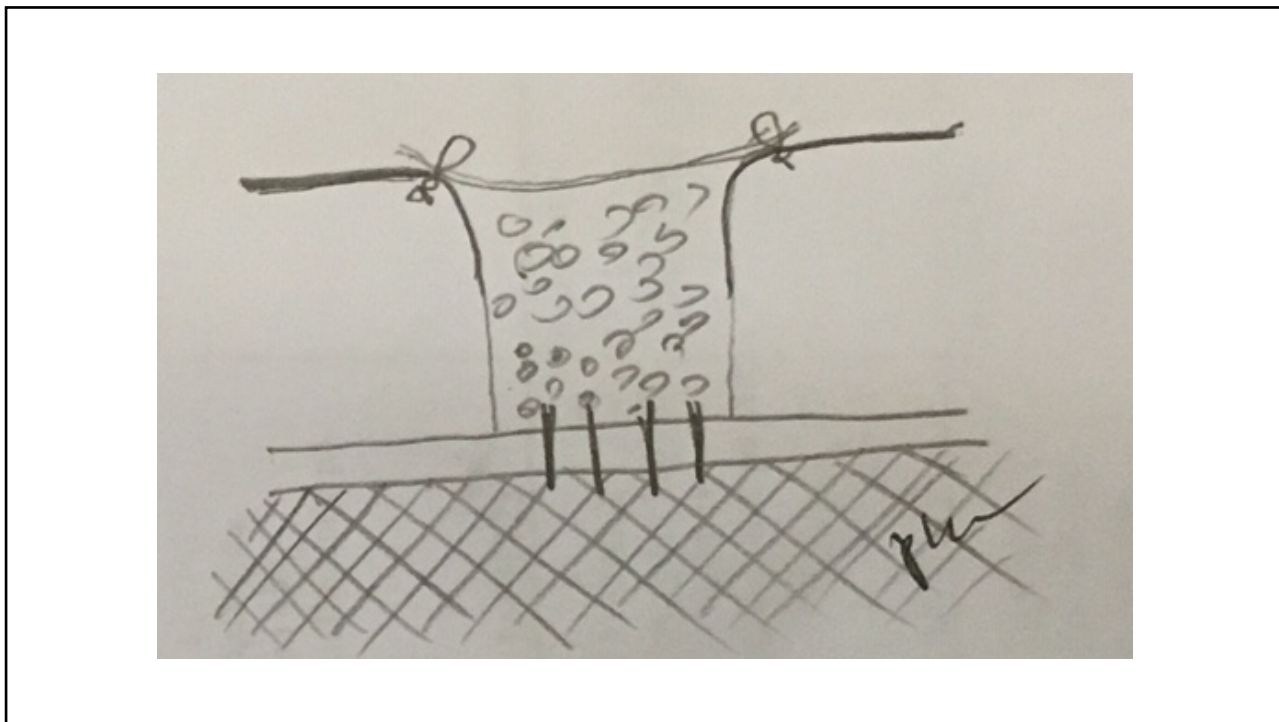


mikrofracture

9



10



11



12

ATFL

- A. normal
- B. grade 1
- C. grade 2
- D. grade 3

13

CFL

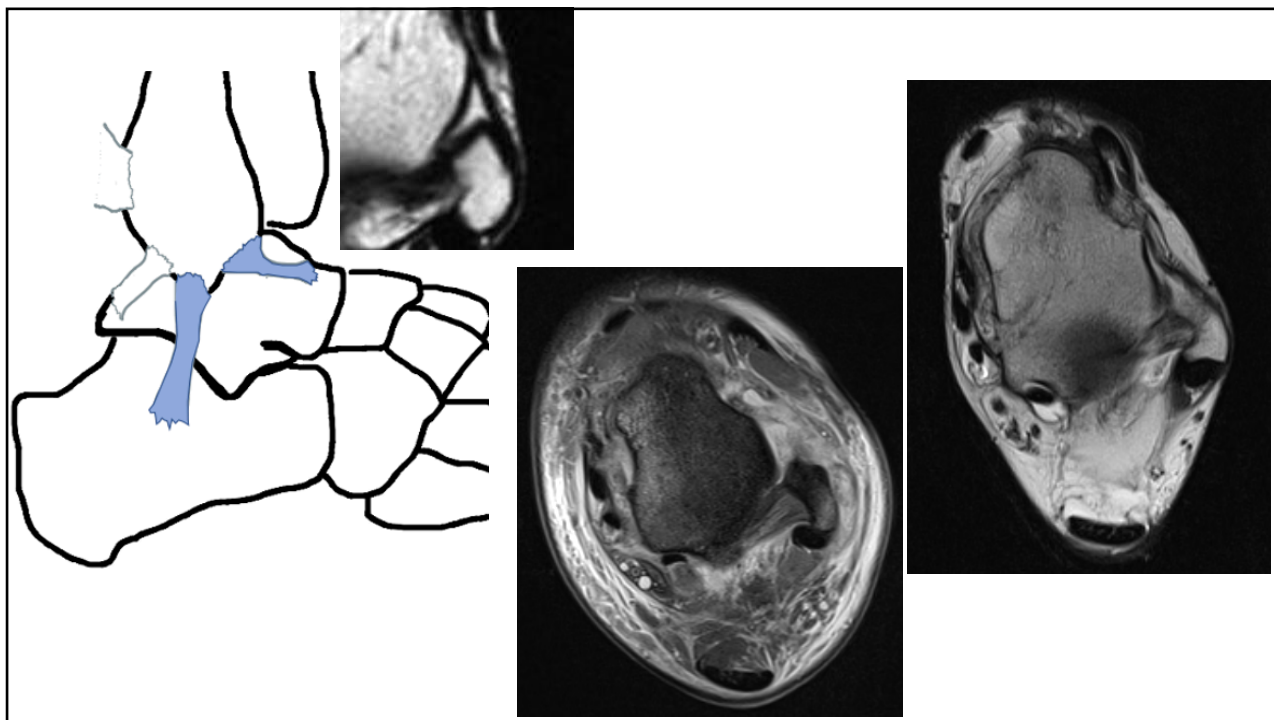
- A. normal
- B. grade 1
- C. grade 2
- D. grade 3

14

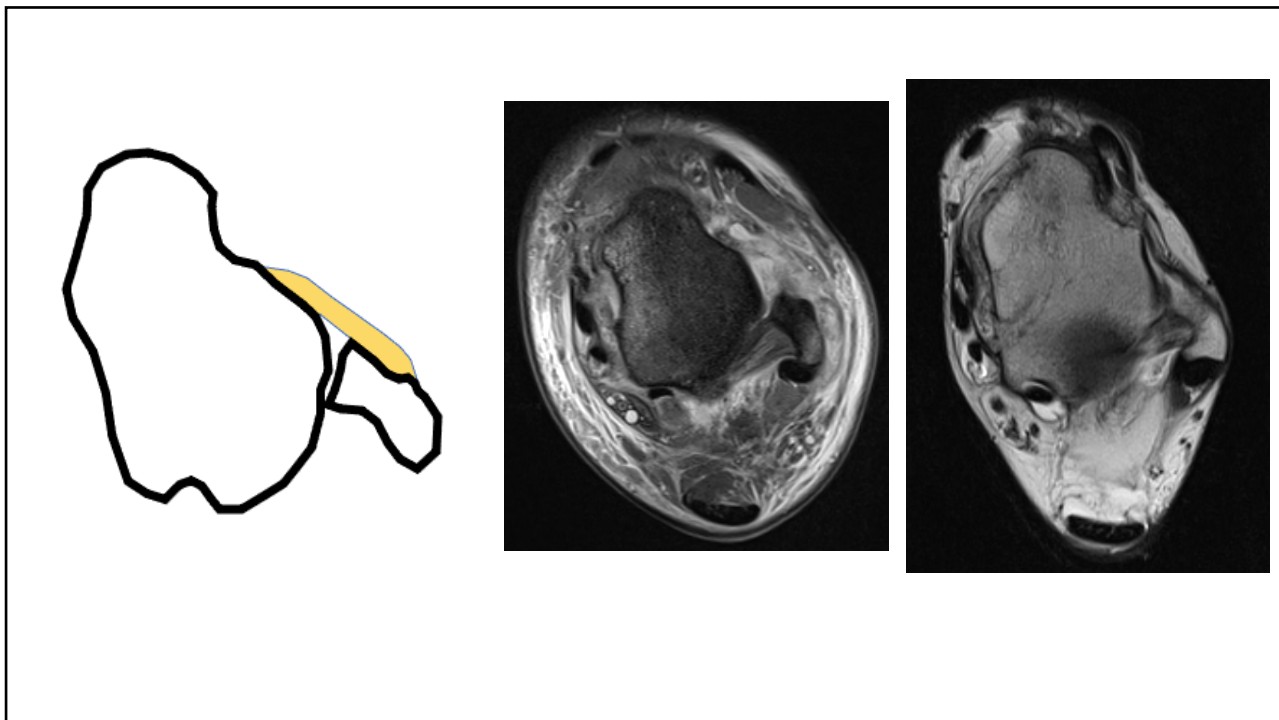
PTFL

- A. normal
- B. grade 1
- C. grade 2
- D. grade 3

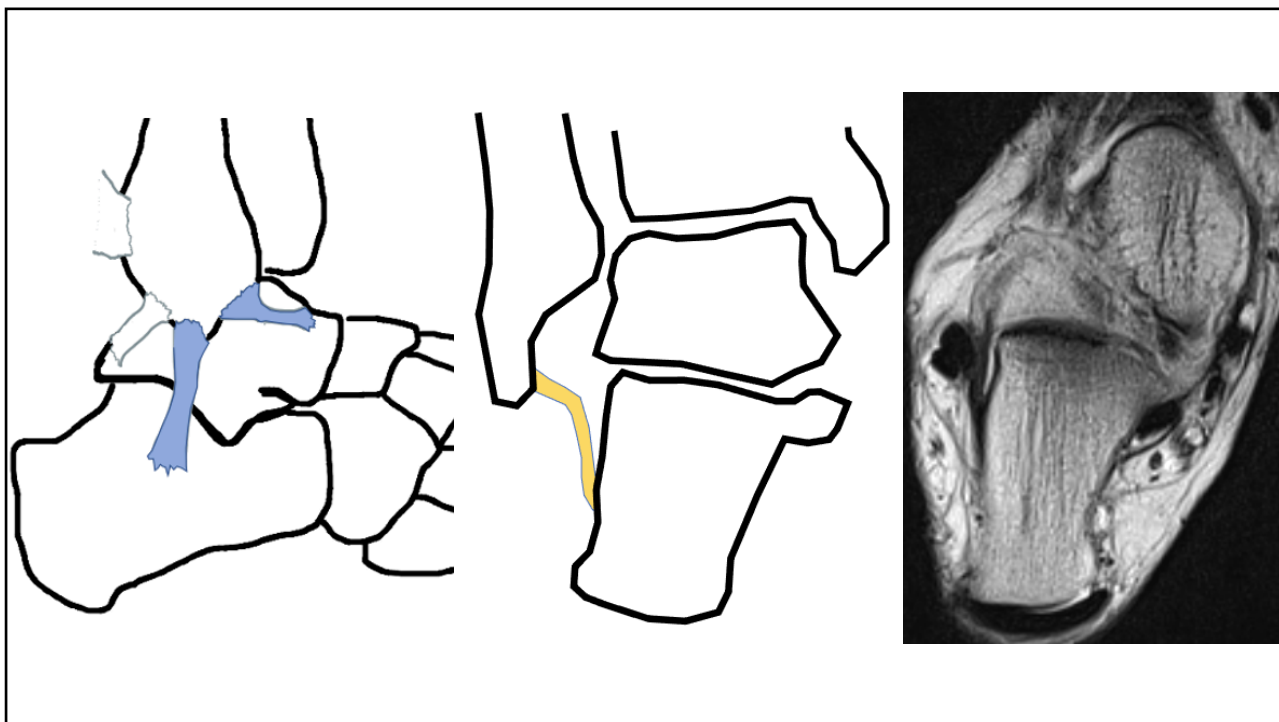
15



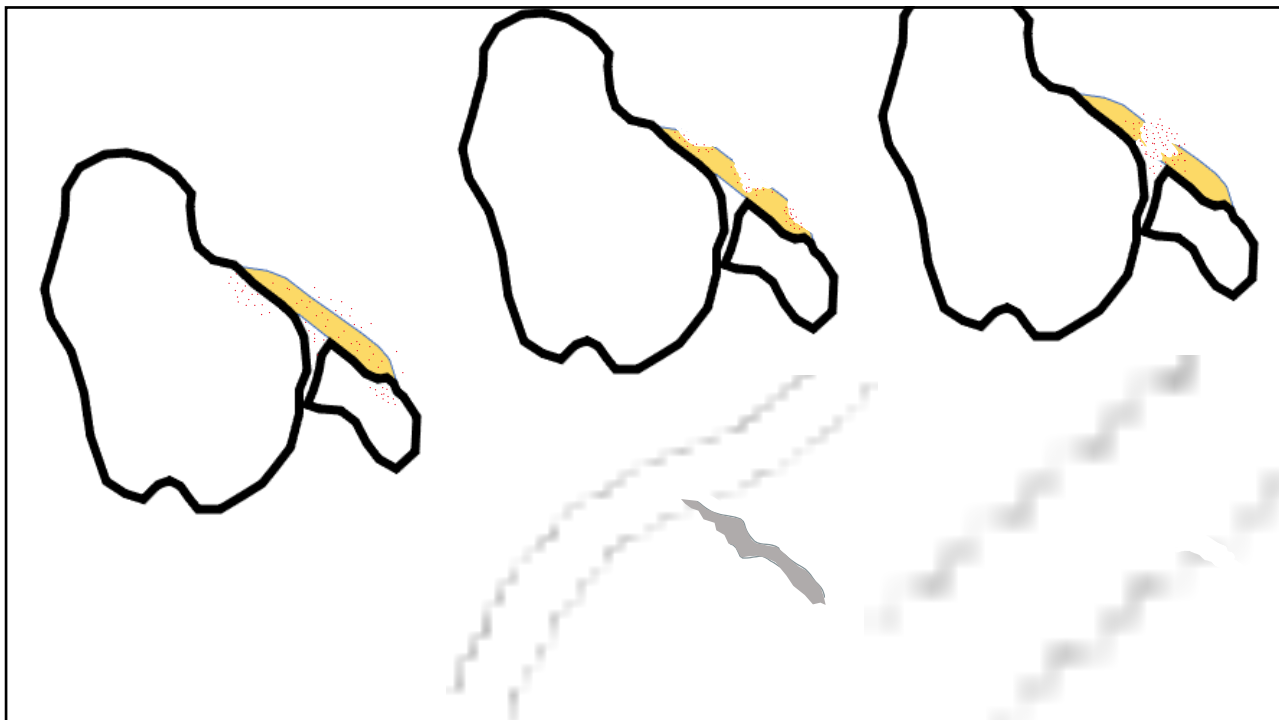
16



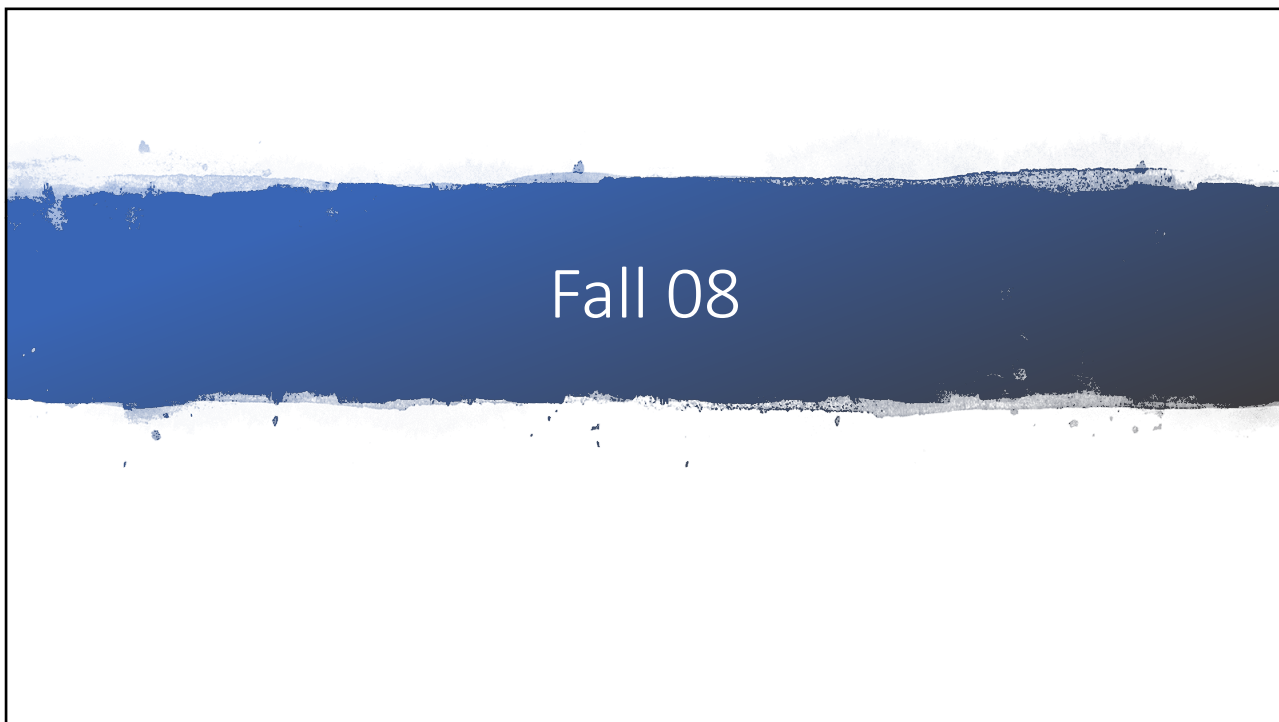
17



18



19

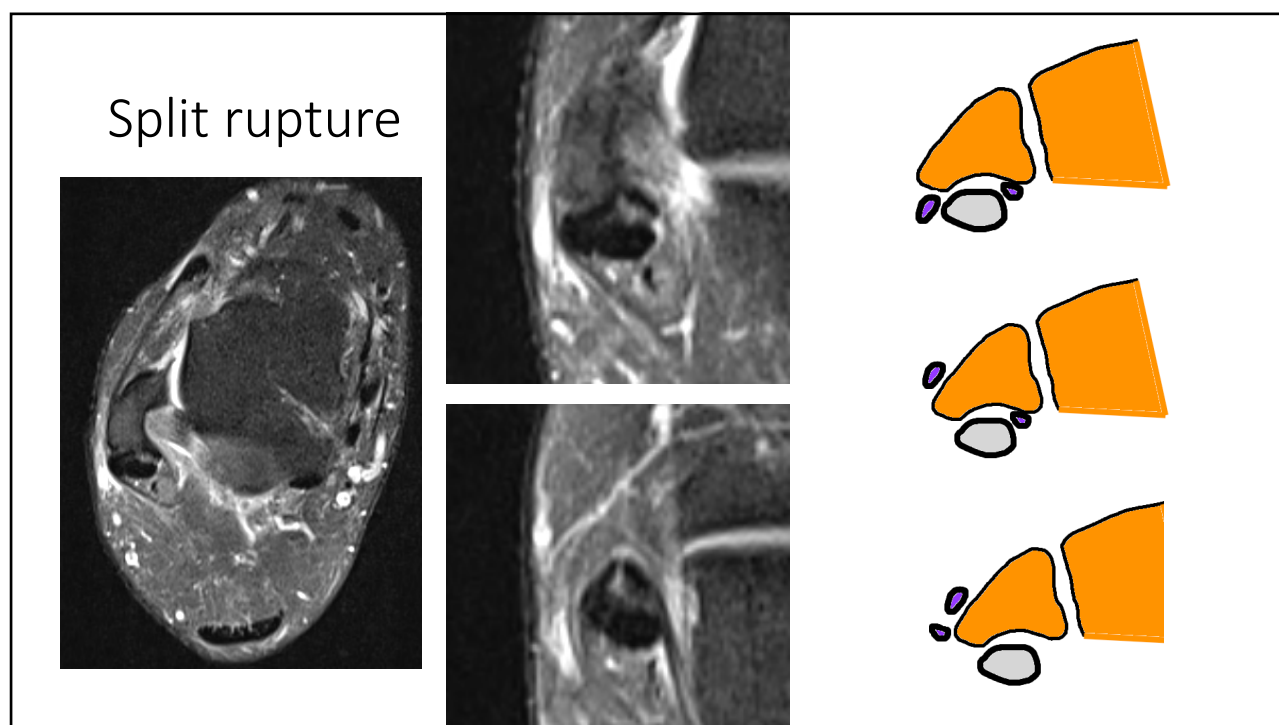


20

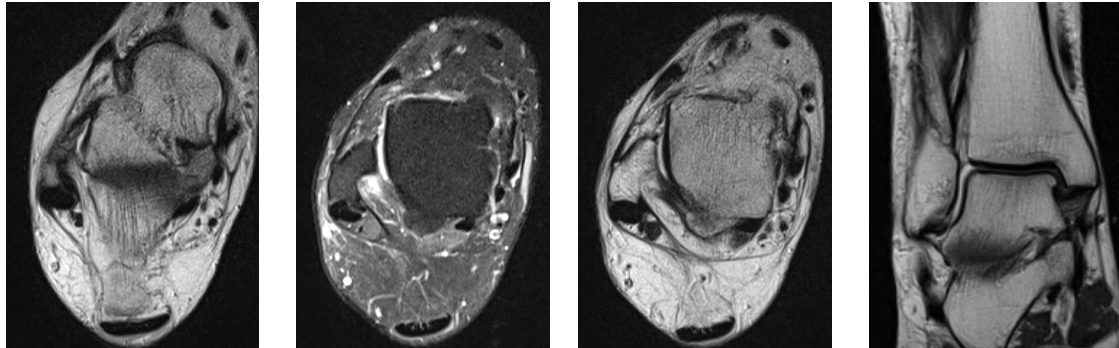
Vilken struktur är skadad?

- A. ATFL
- B. CFL
- C. superior peroneal retinaculum
- D. peroneus brevis

21



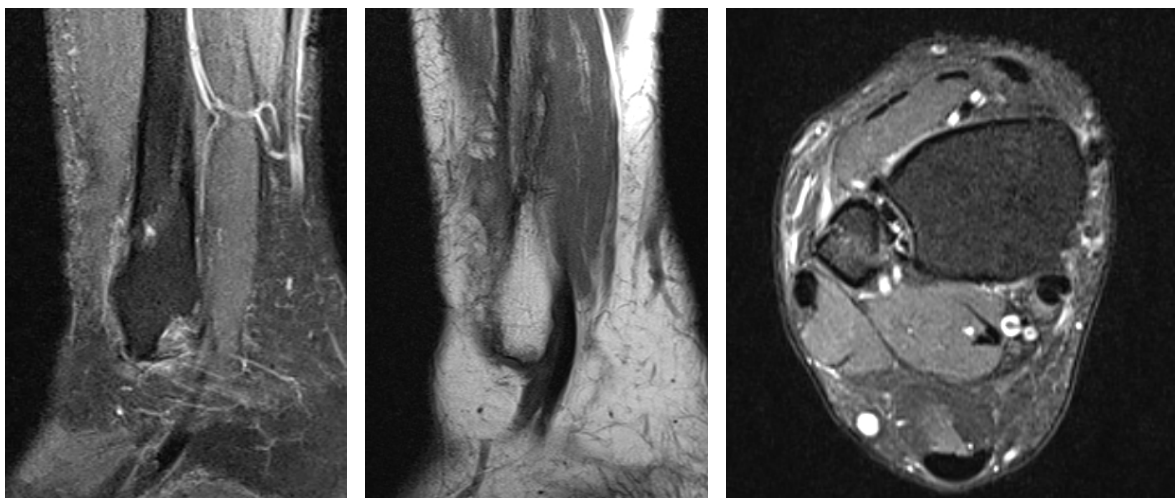
22



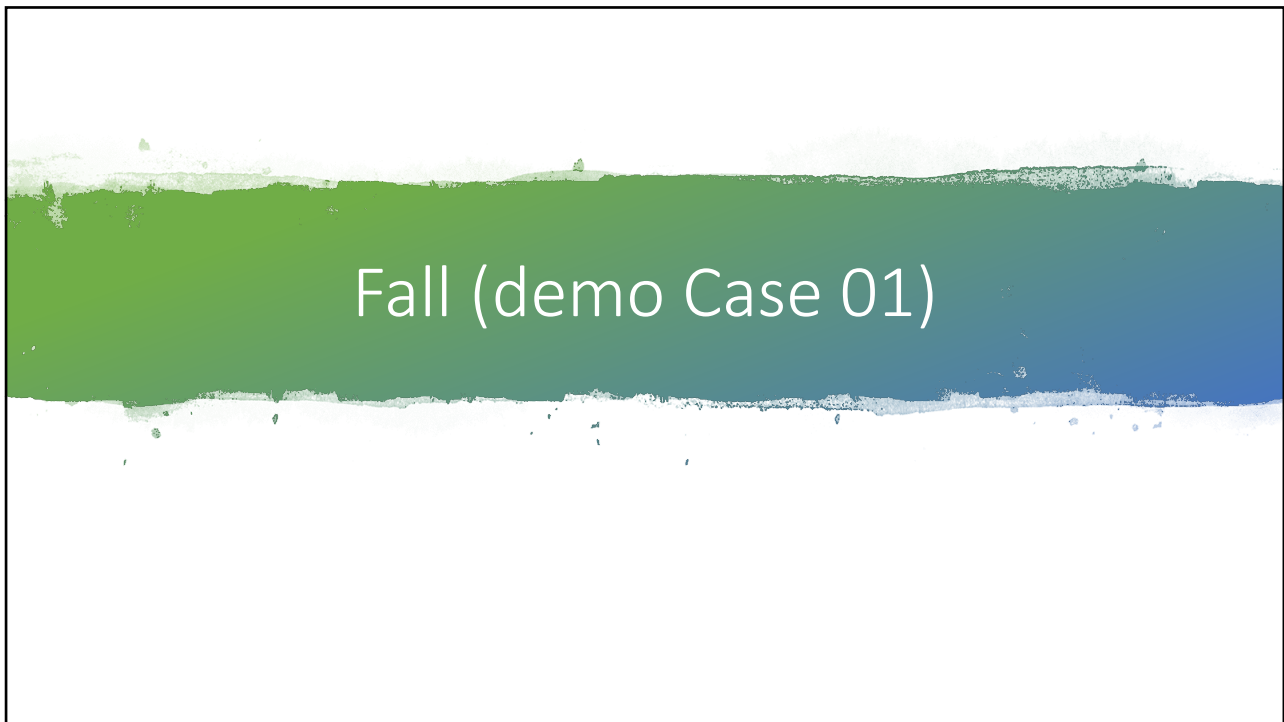ATFL, superior peroneal retinaculum

23

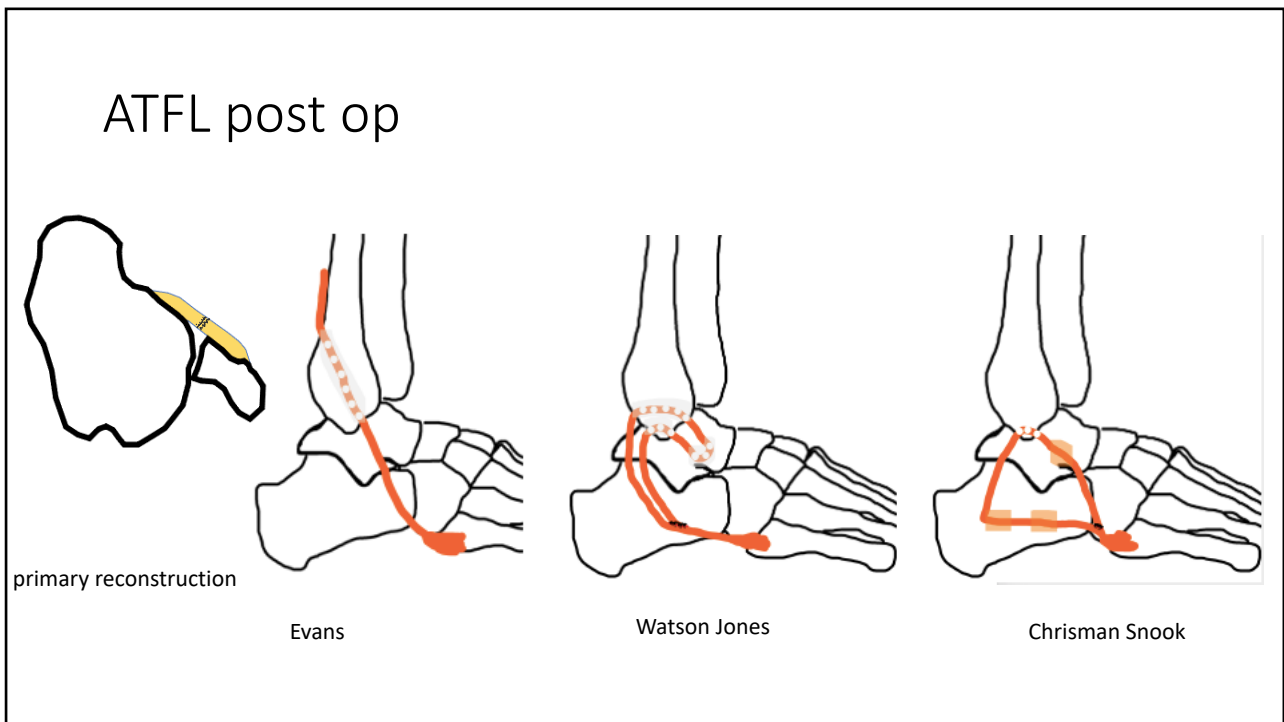
Fracture



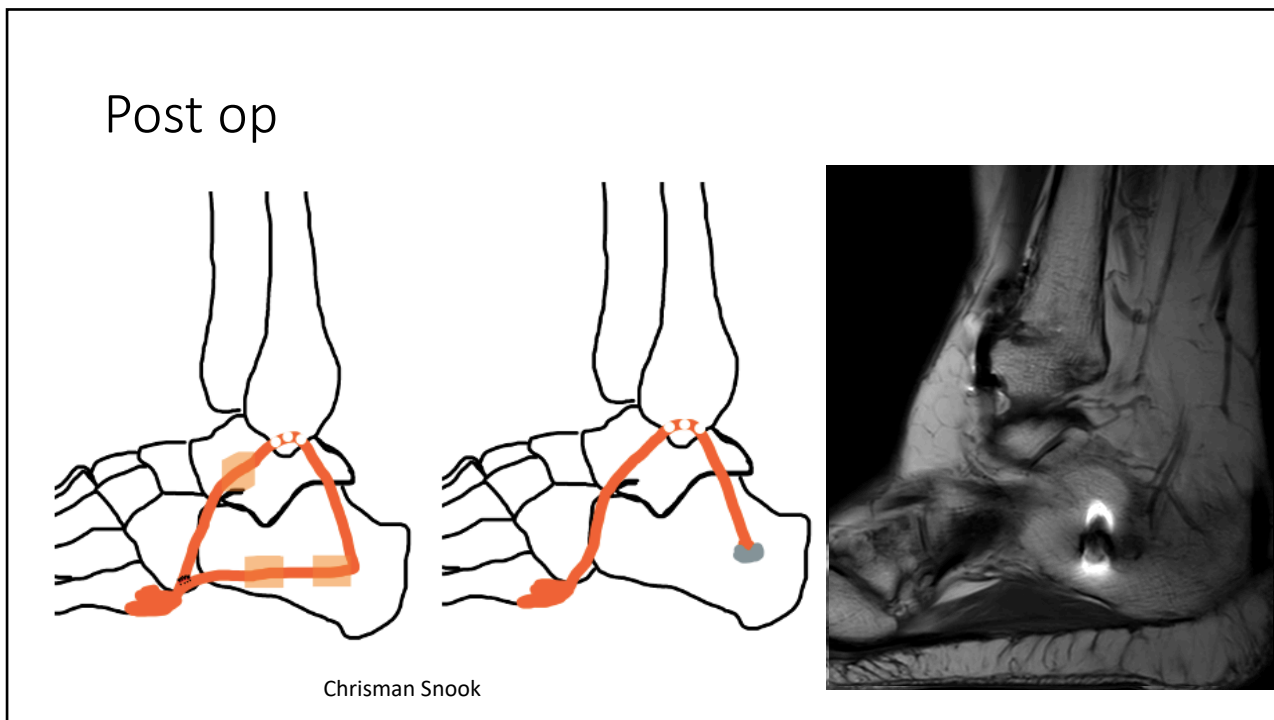
24



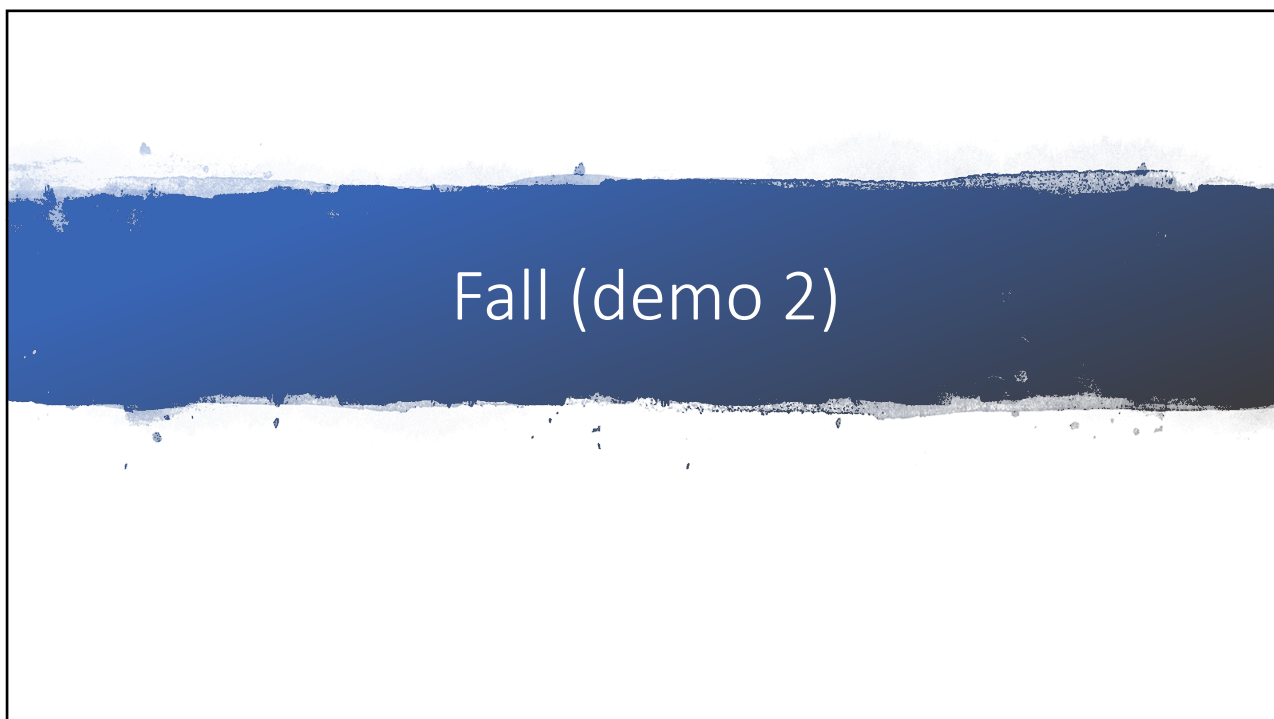25



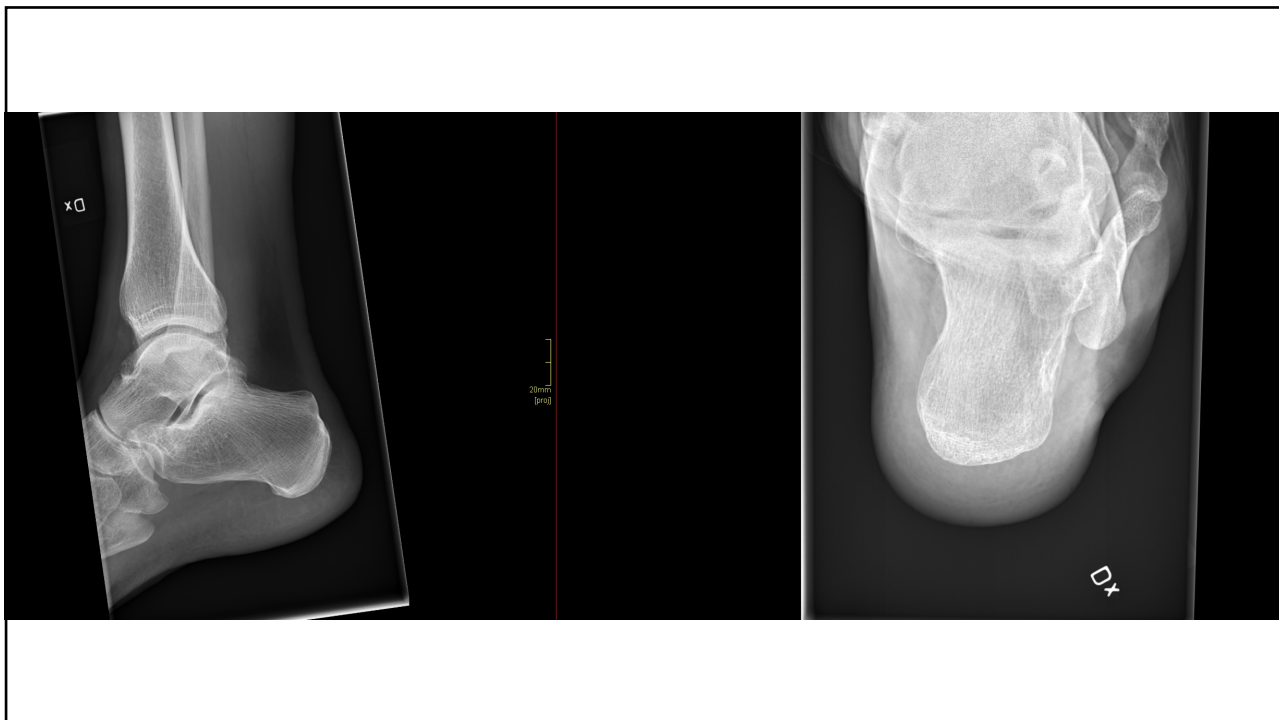26



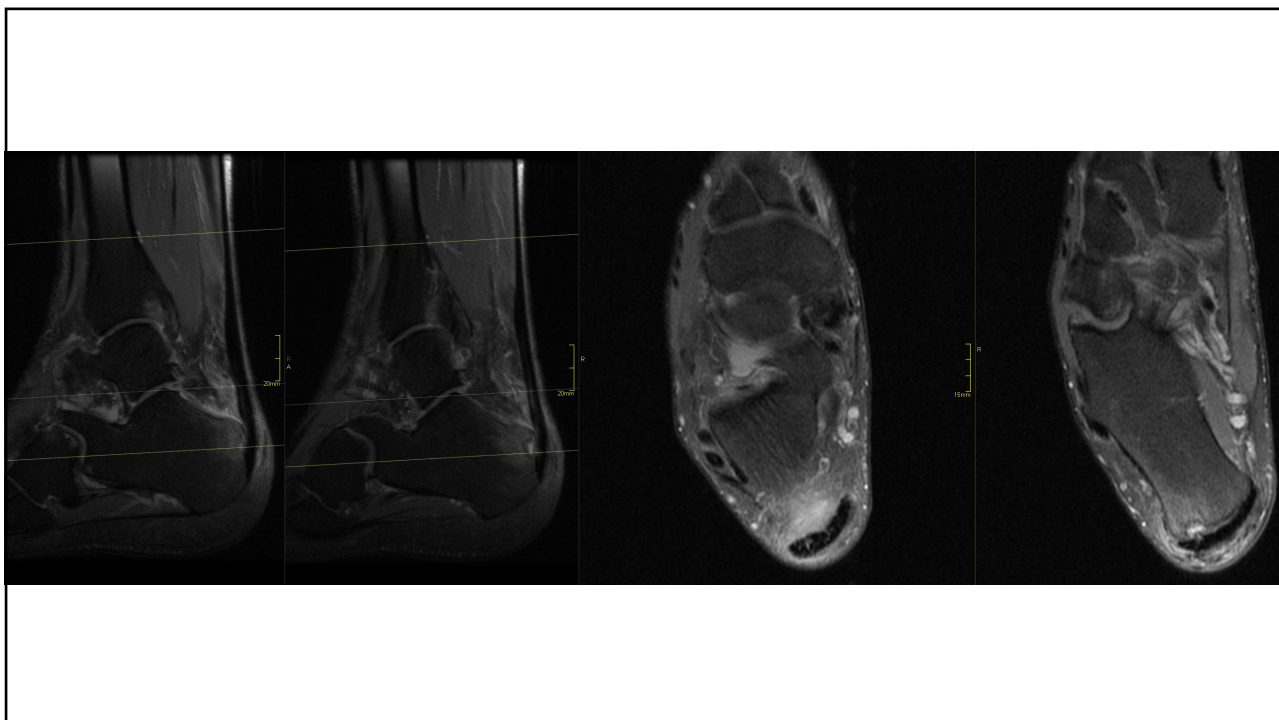27



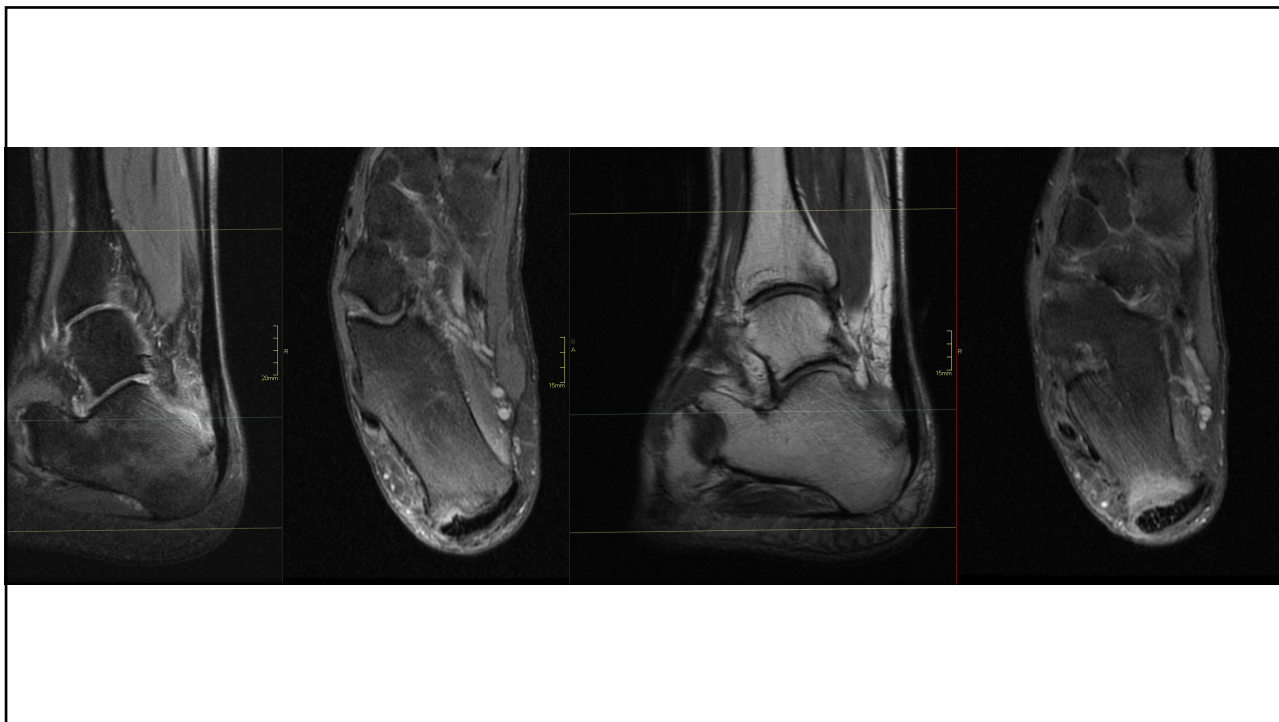28



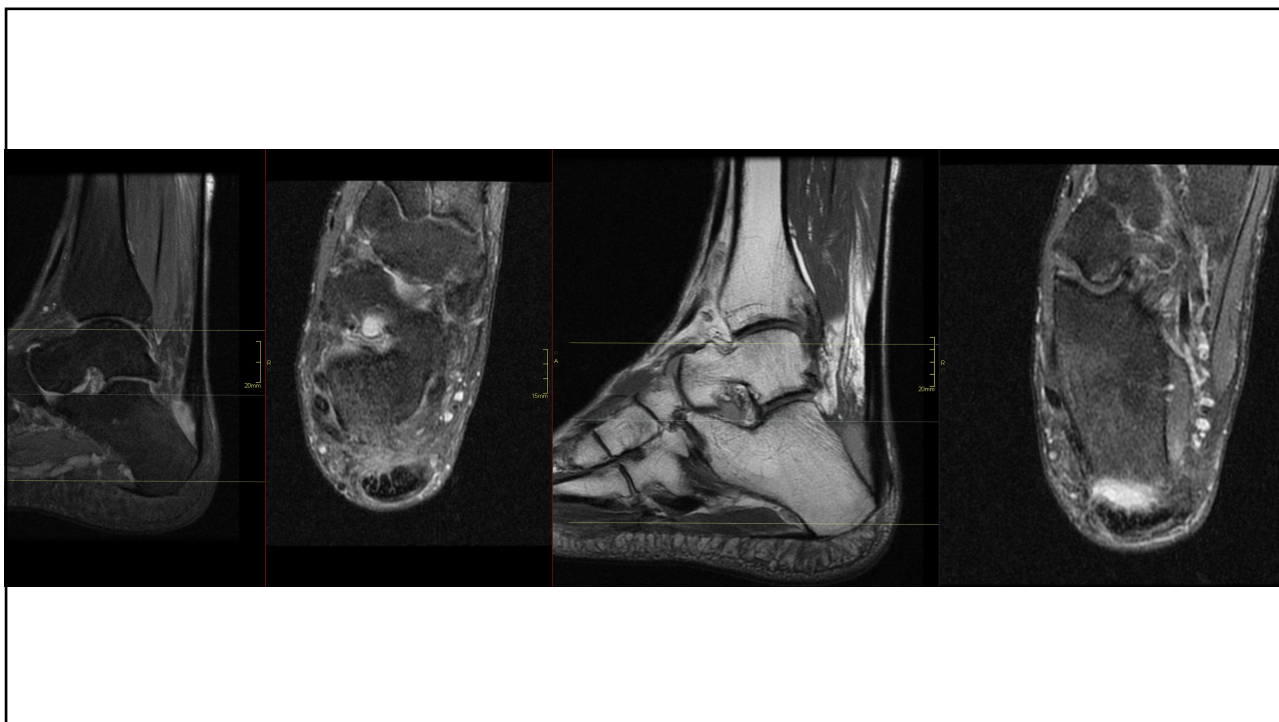
29



30



31



32