

# MR Axel

## Digital workshop i avancerad muskuloskeletal radiologi

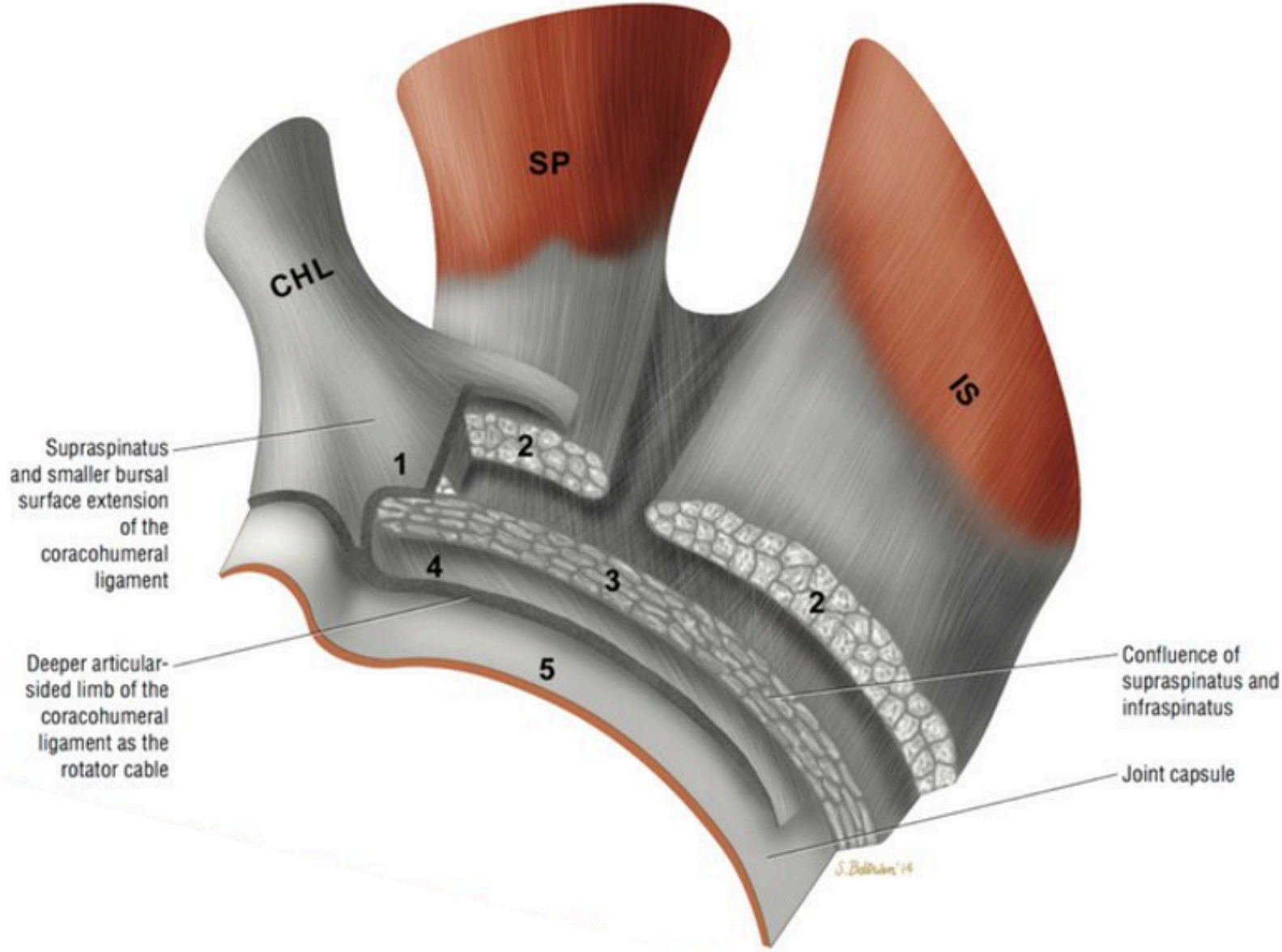
Pawel Szaro MD, Ph.D.,

Överläkare

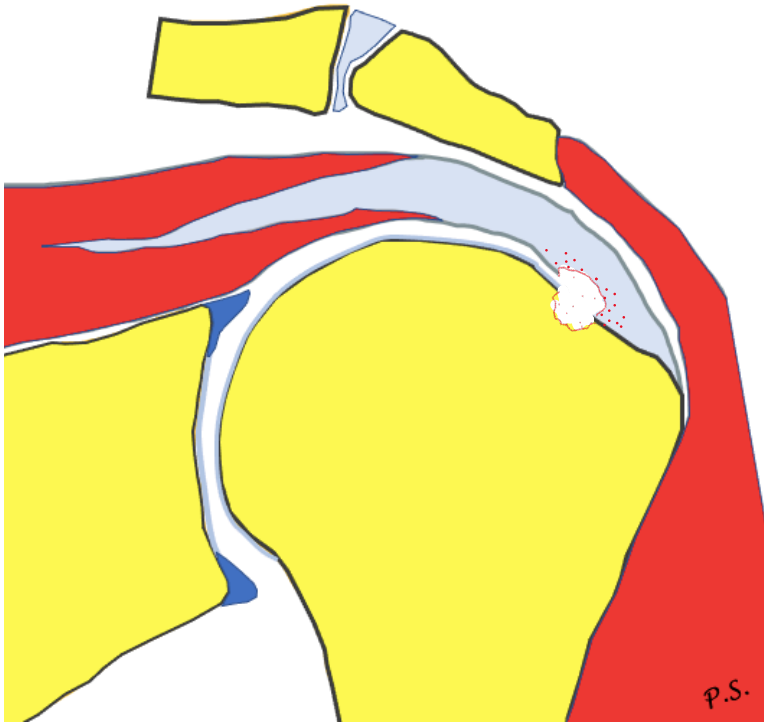
Sahlgrenska Universitetssjukhuset Mölndal



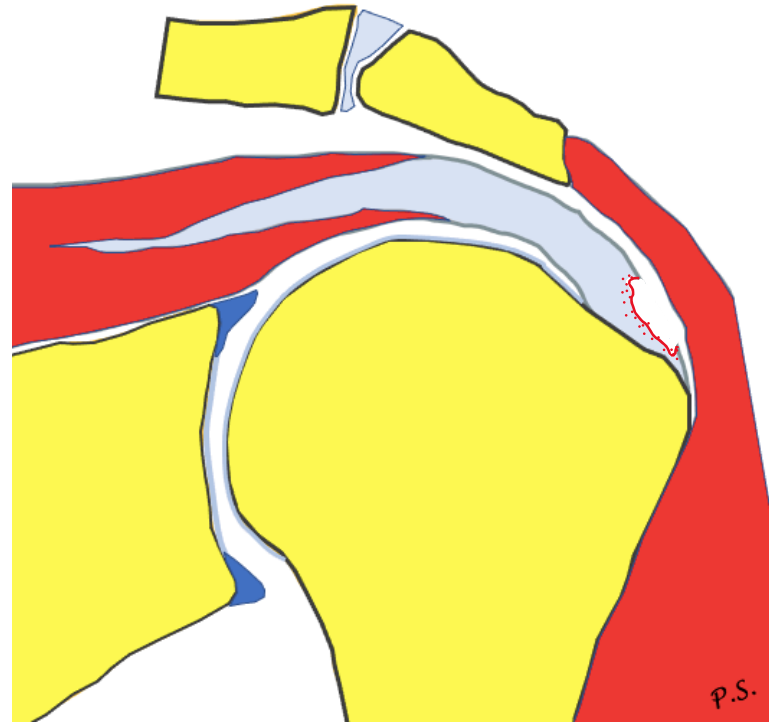
# Rotator cuff



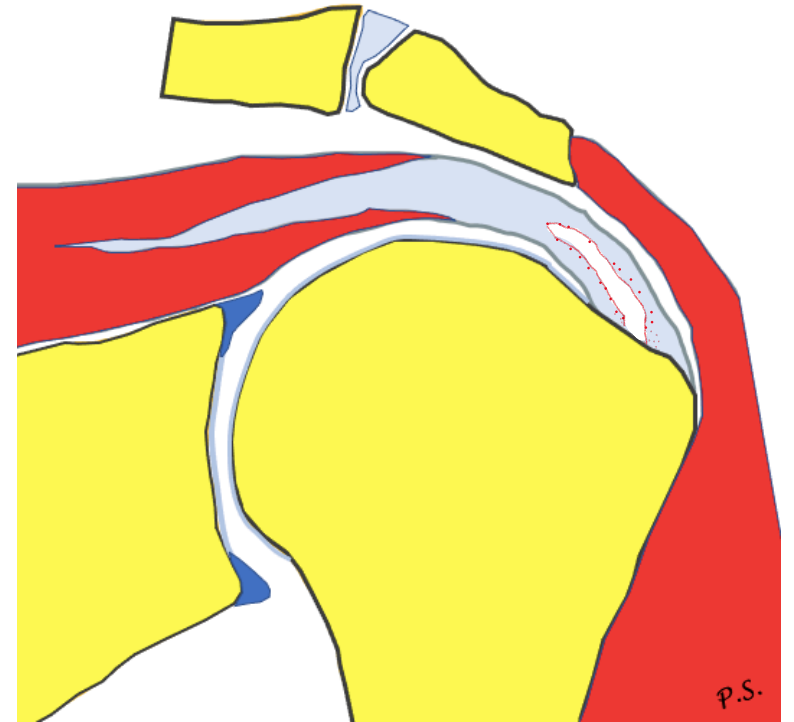
# Rupture



articular side  
rim rent

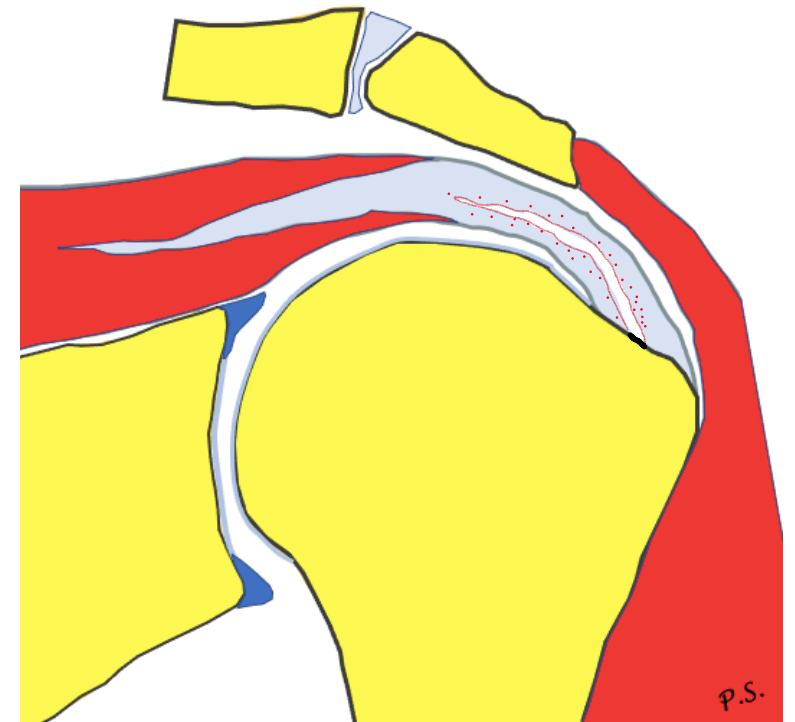
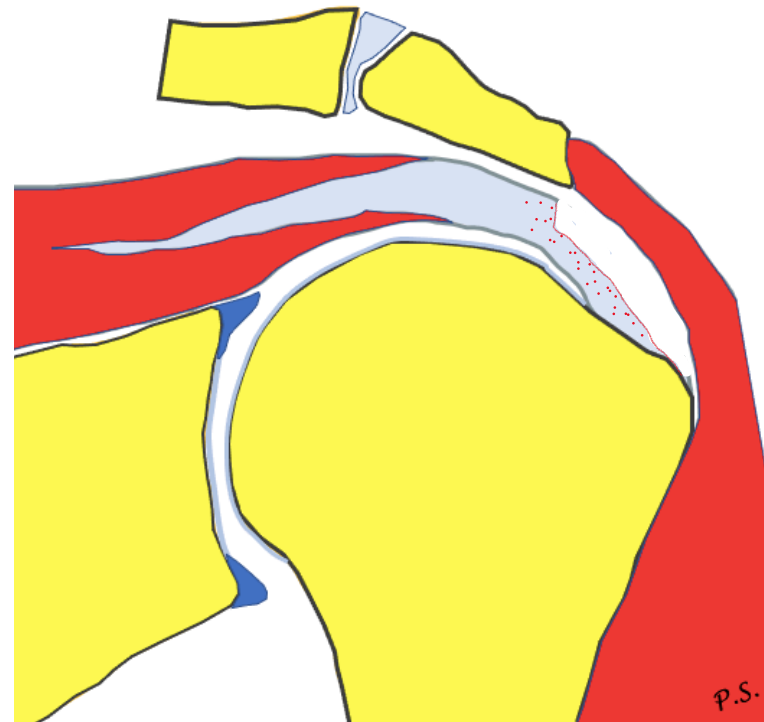
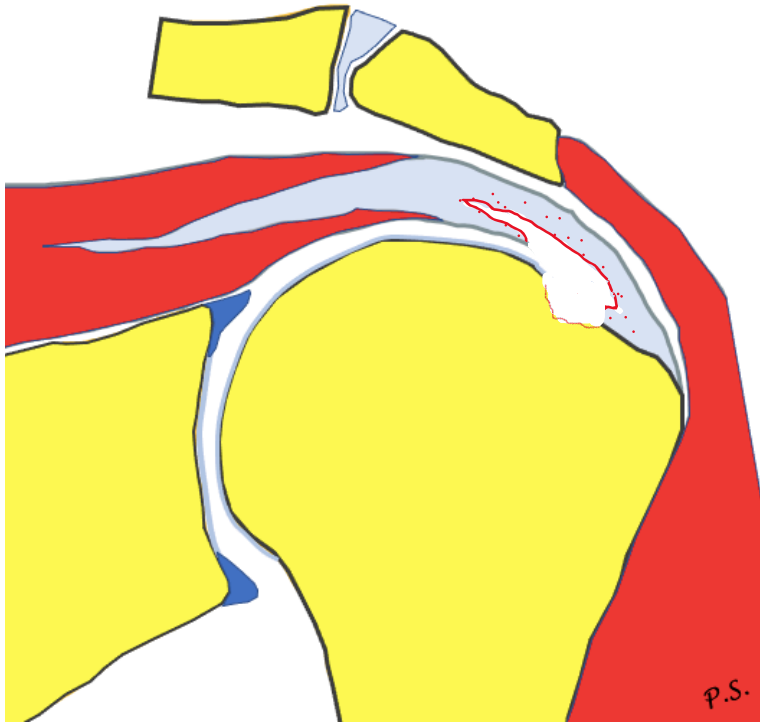


bursal side



intrasubstance

# Rupture



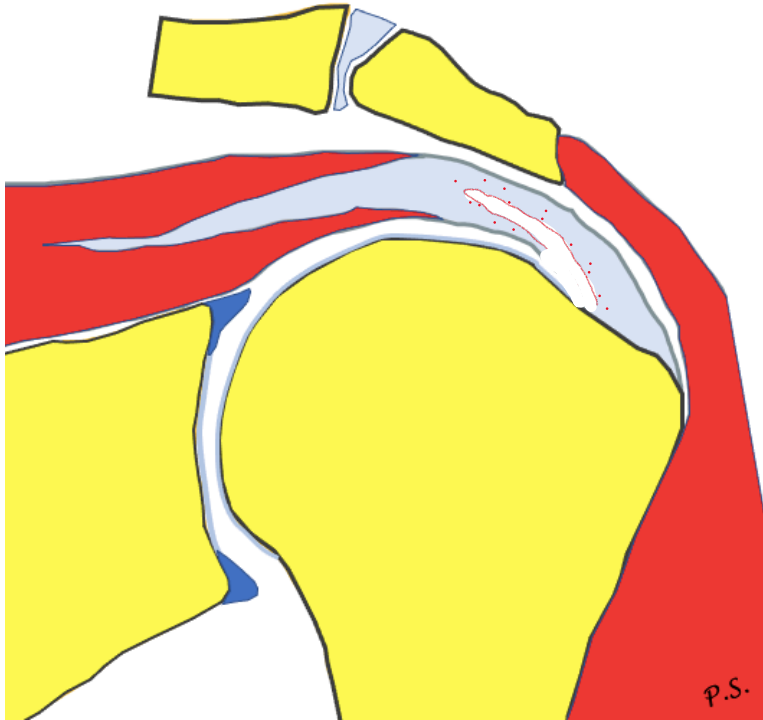
PASTA

partial articular supraspinatus  
tendon avulsion

Reverse PASTA

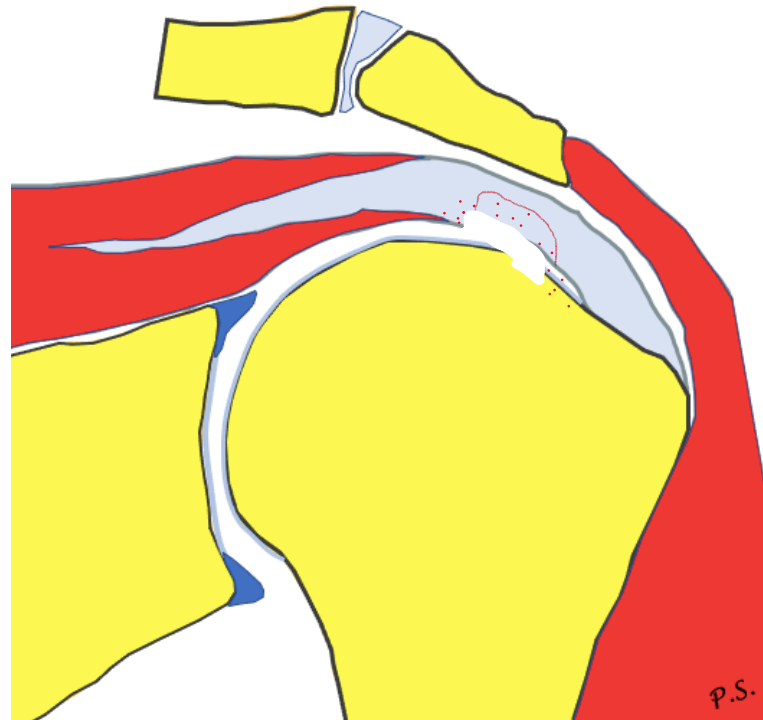
PITA

# Rupture



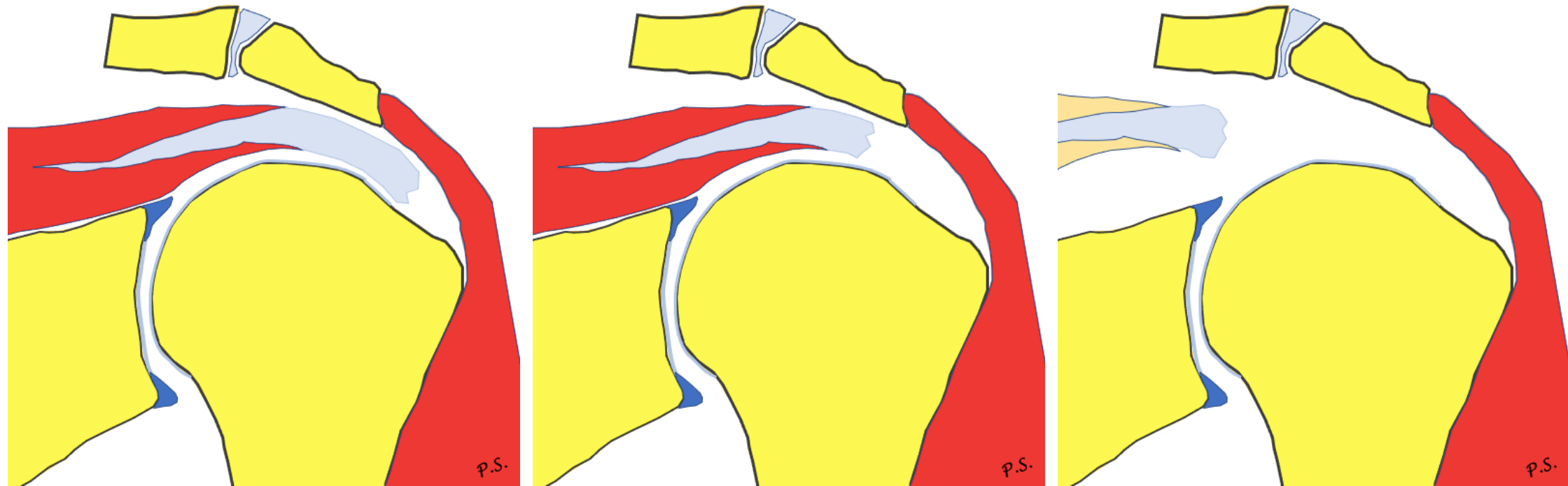
PAINT

partial articular-sided  
with interstitial extension

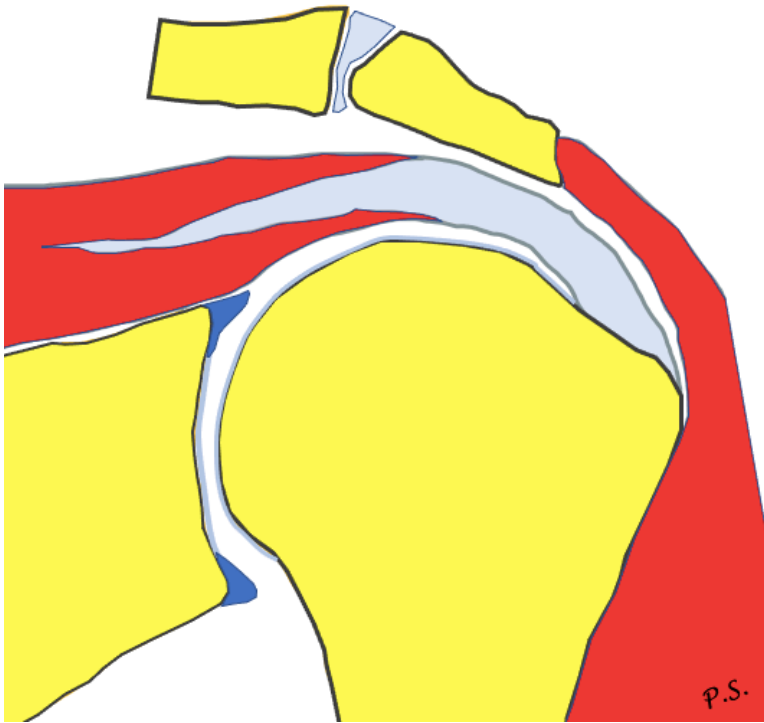


STAS

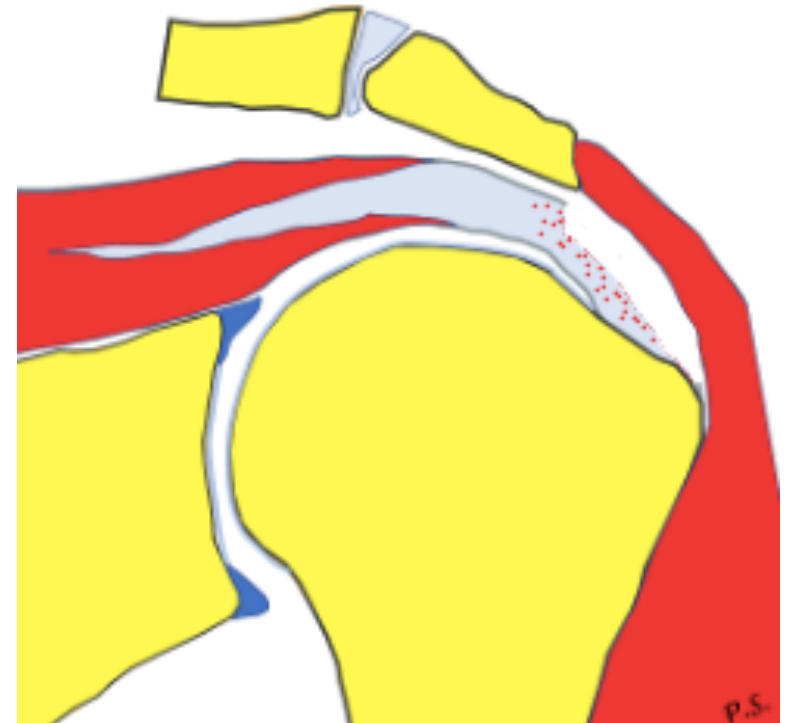
# Retraction (Patte)



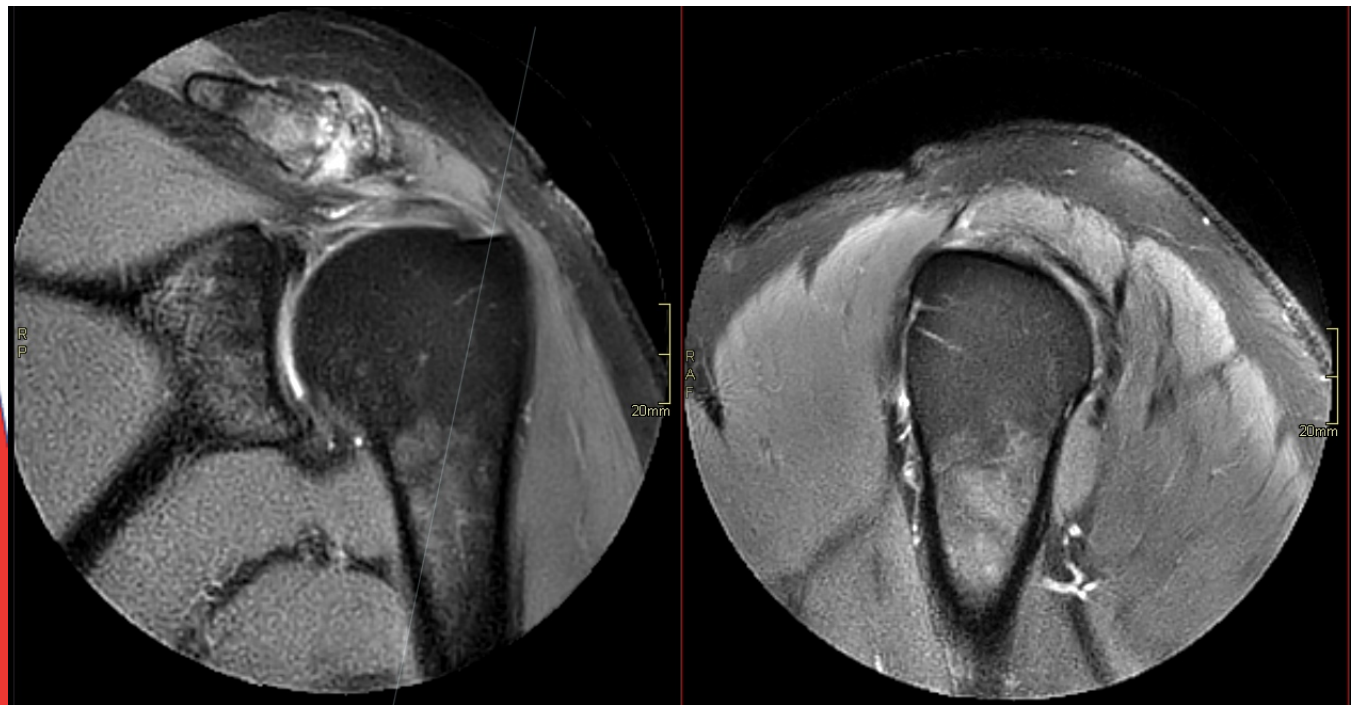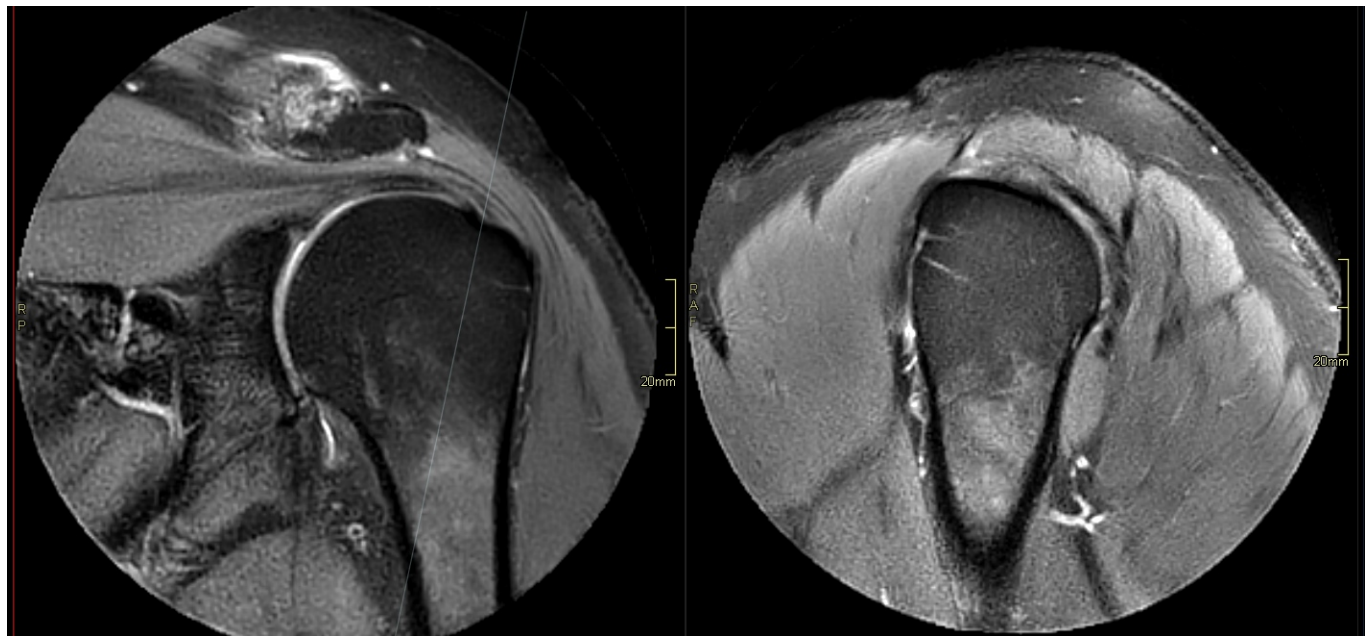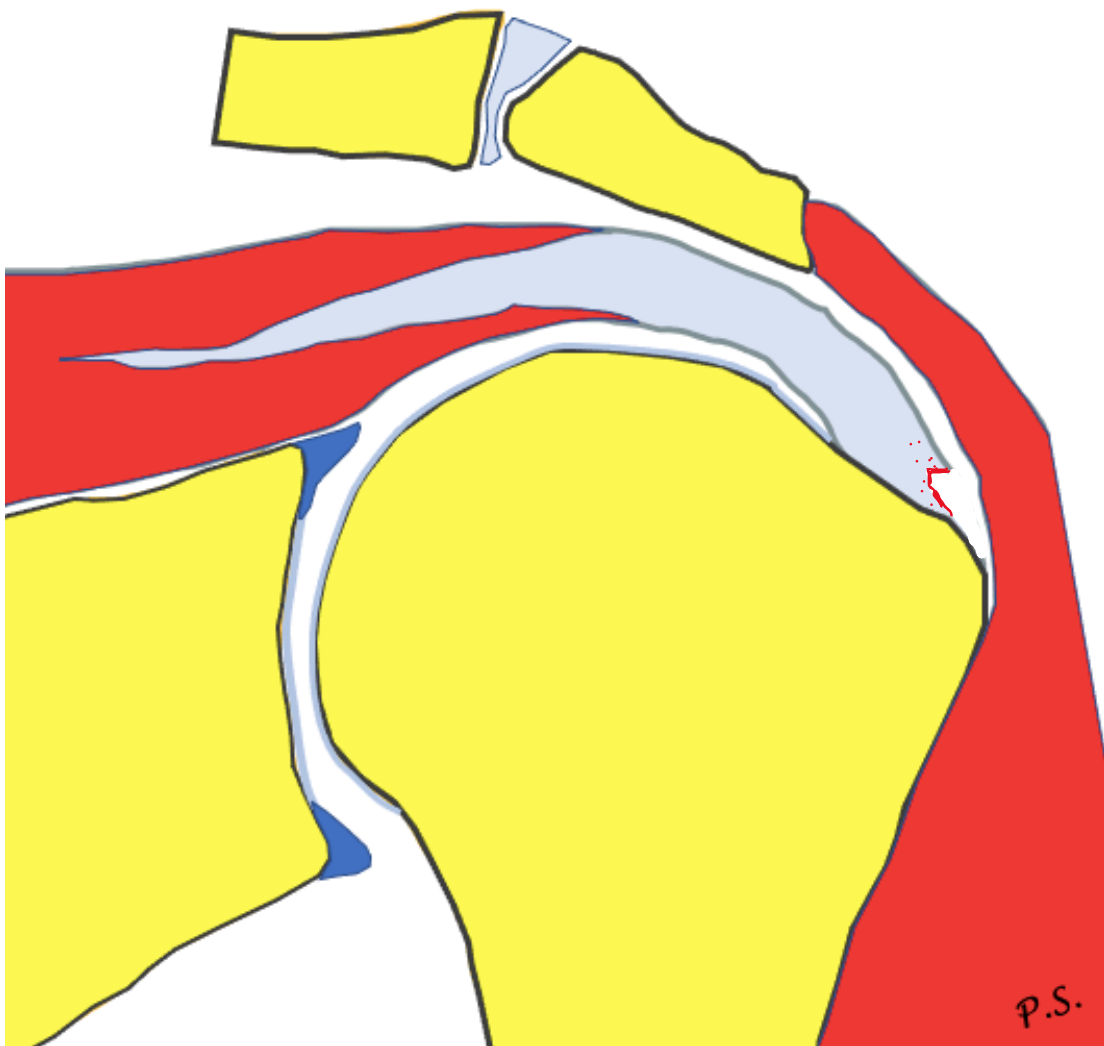
# Grading



1.  $<3$  mm
2. 3-6 mm
3.  $>6$  mm

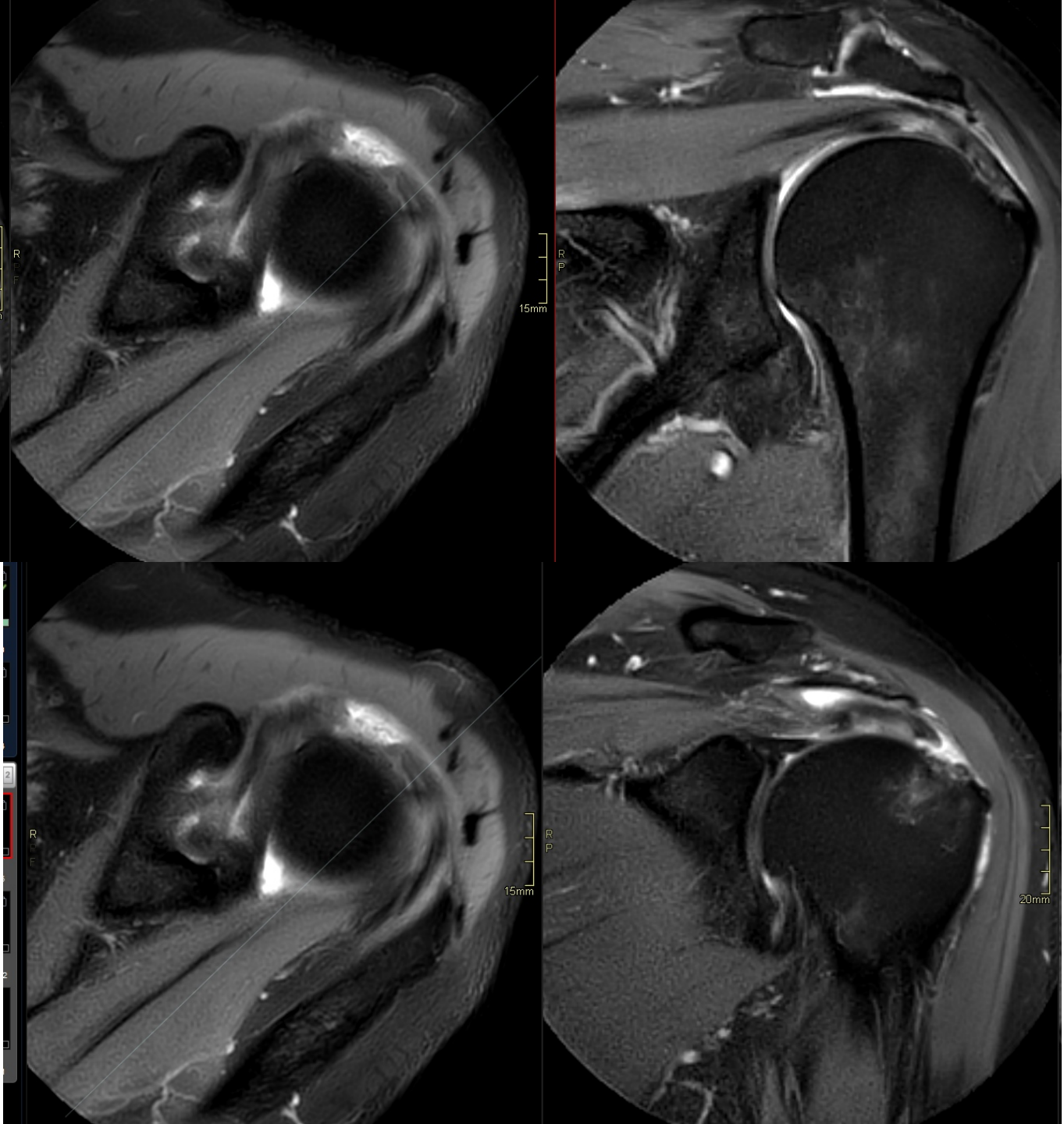
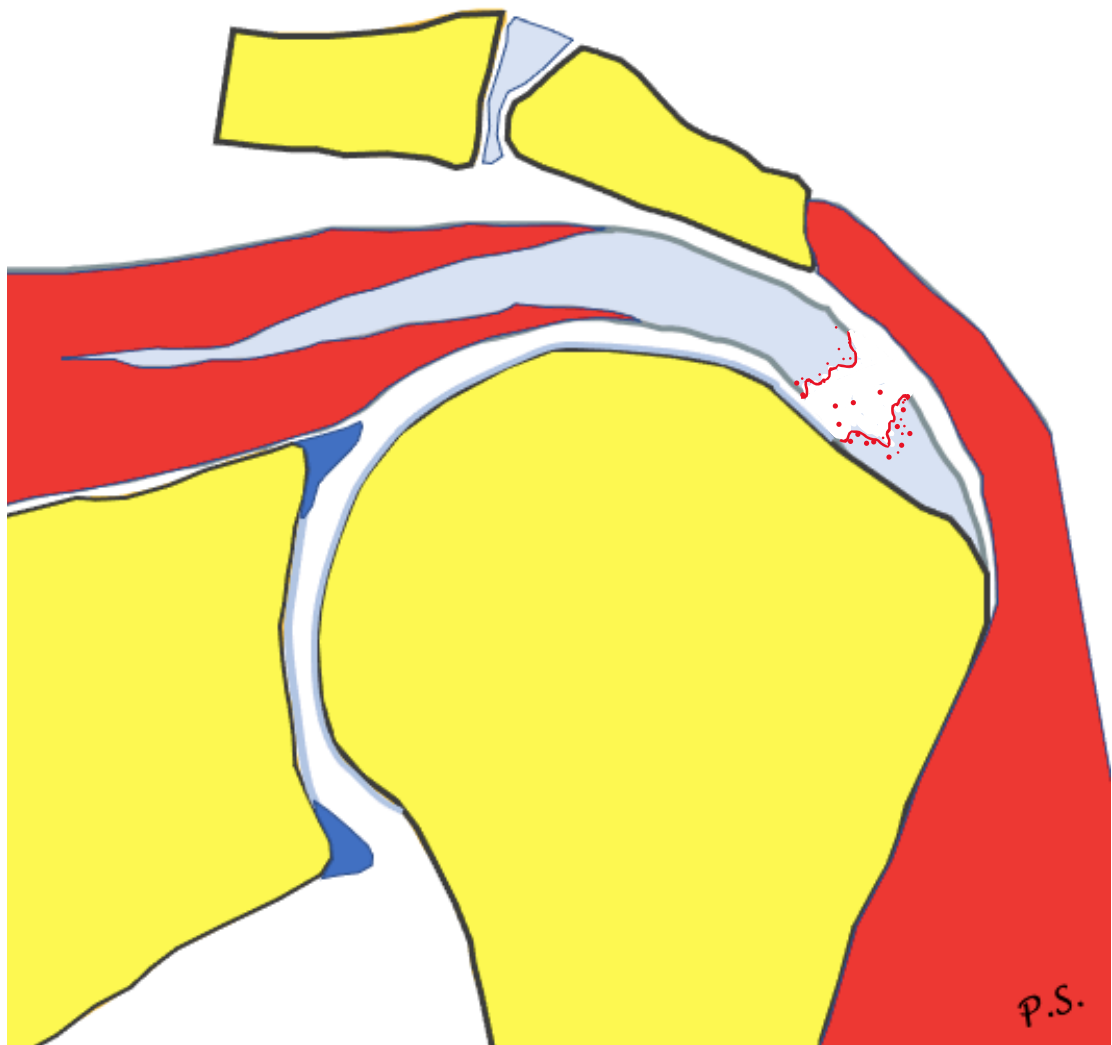


# Rupture


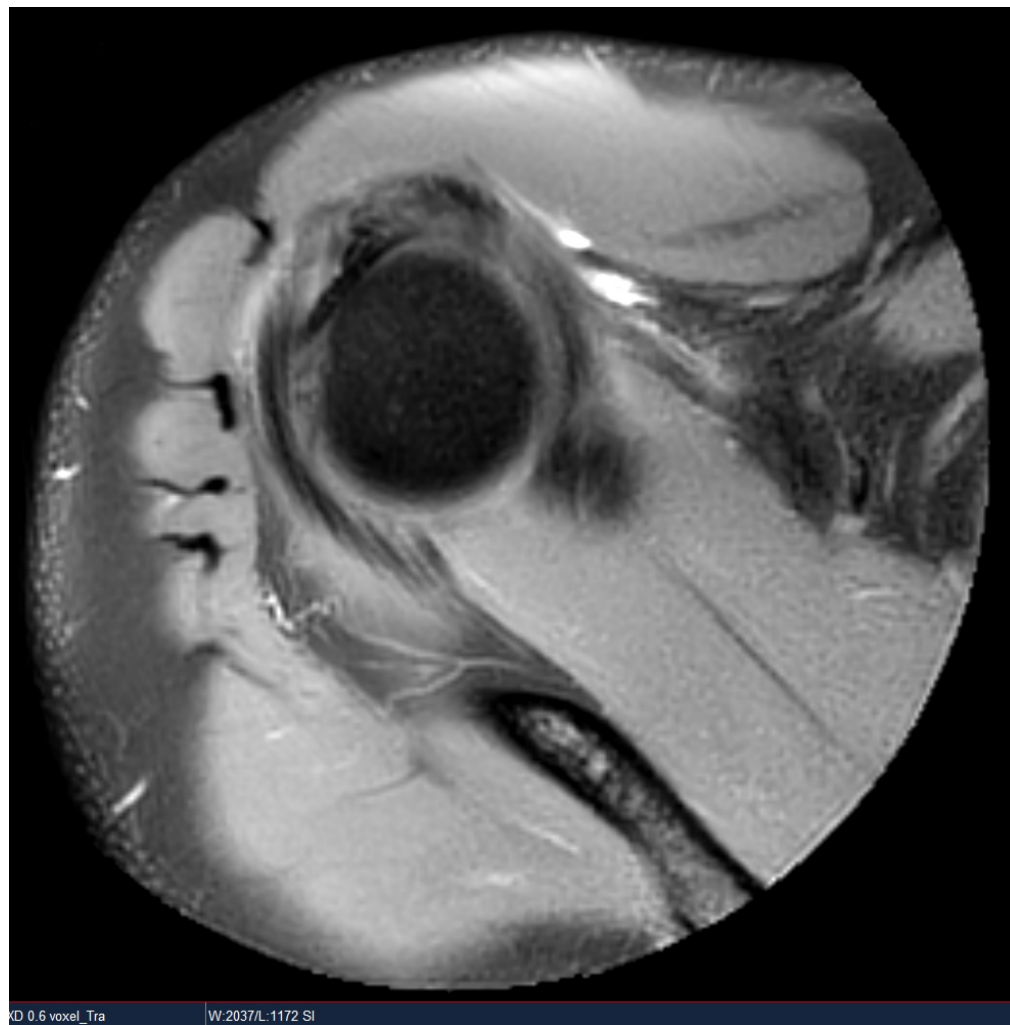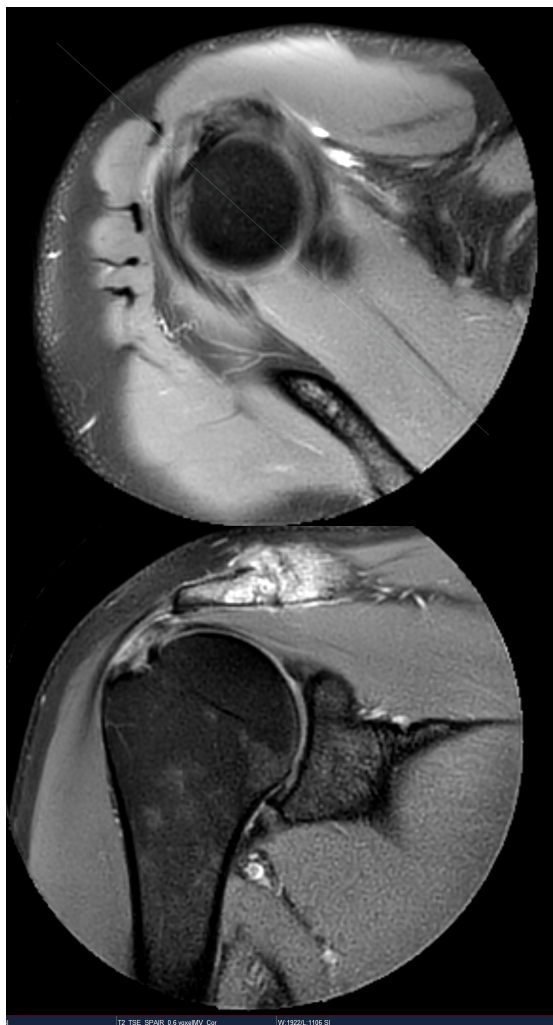




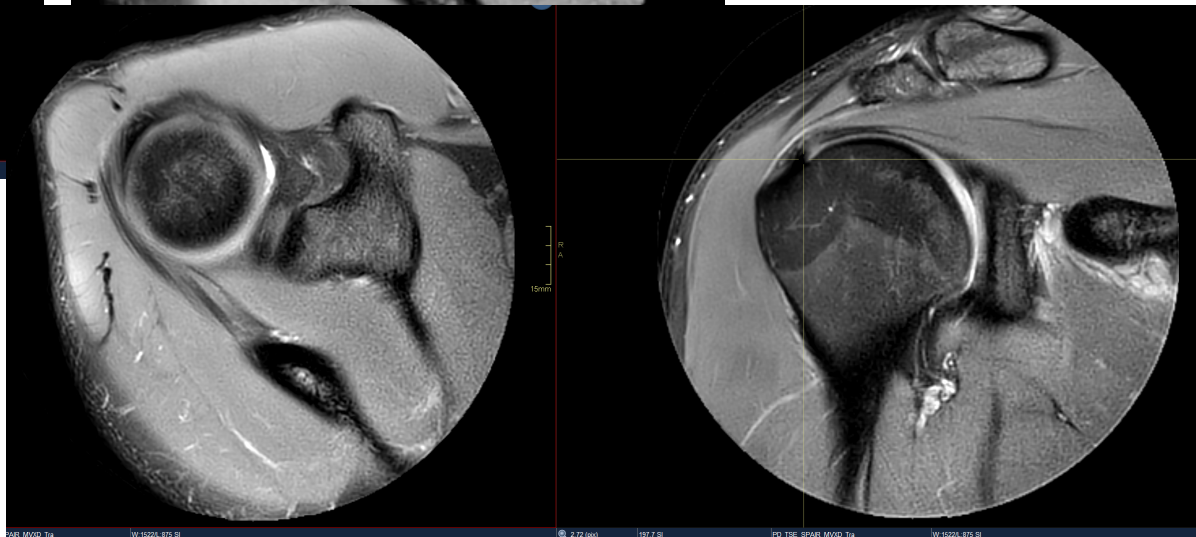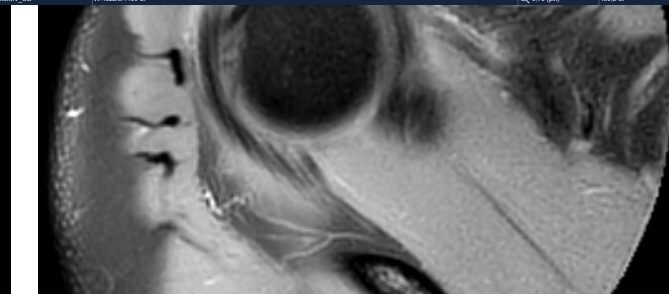
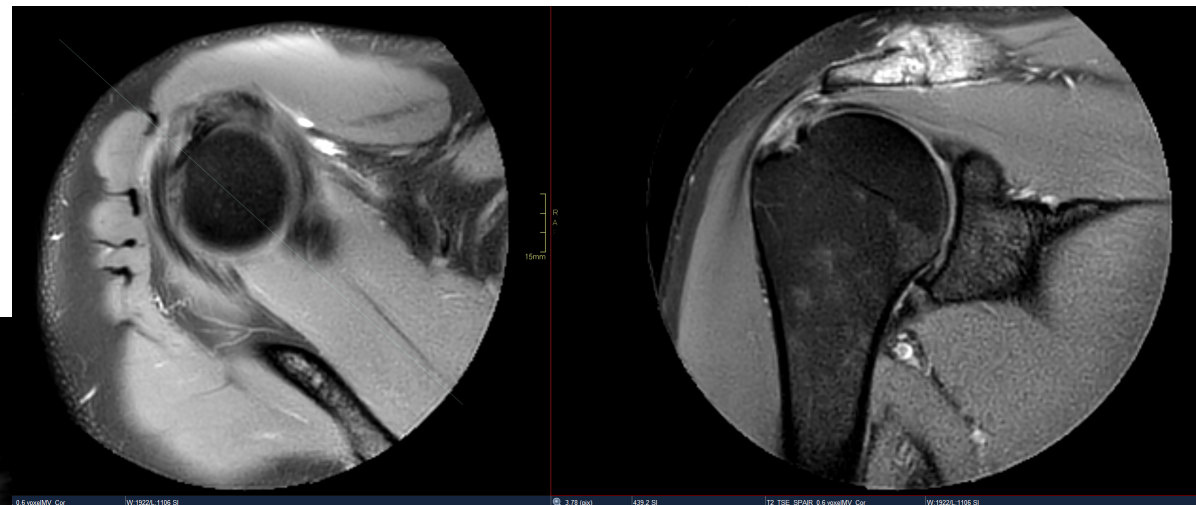
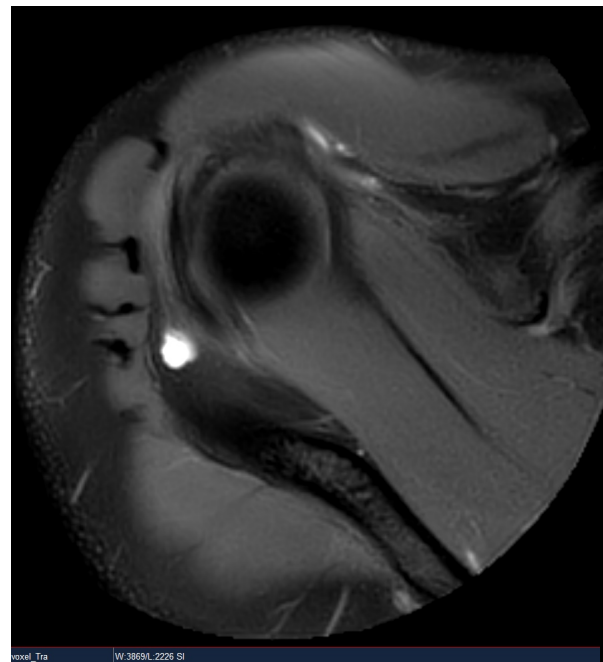
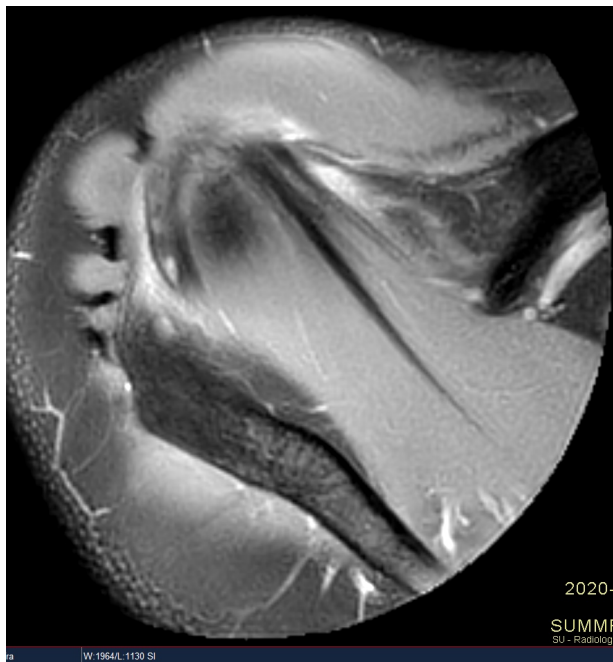
# Ruptur



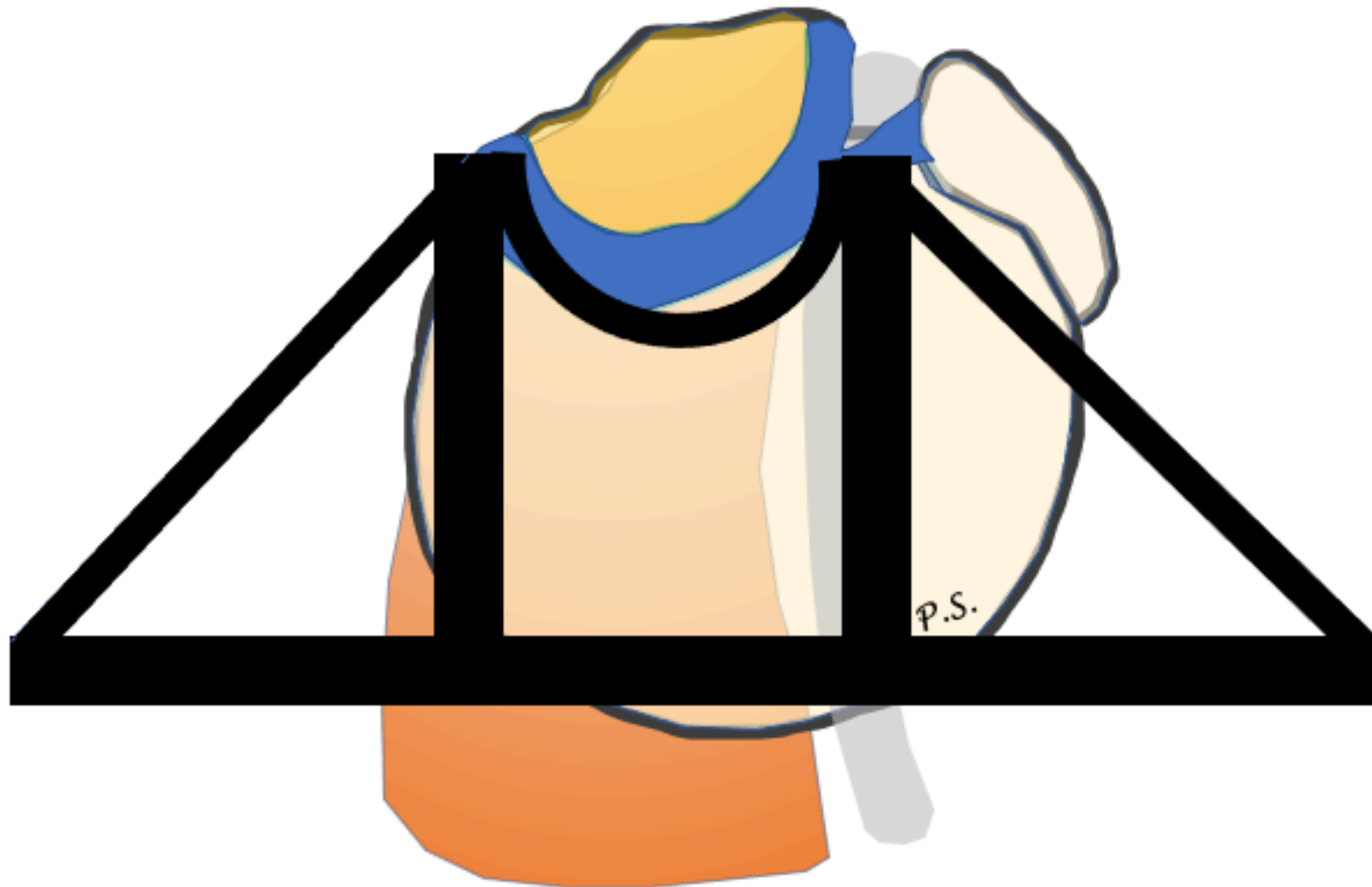# Rotator cable




# Rotator cable




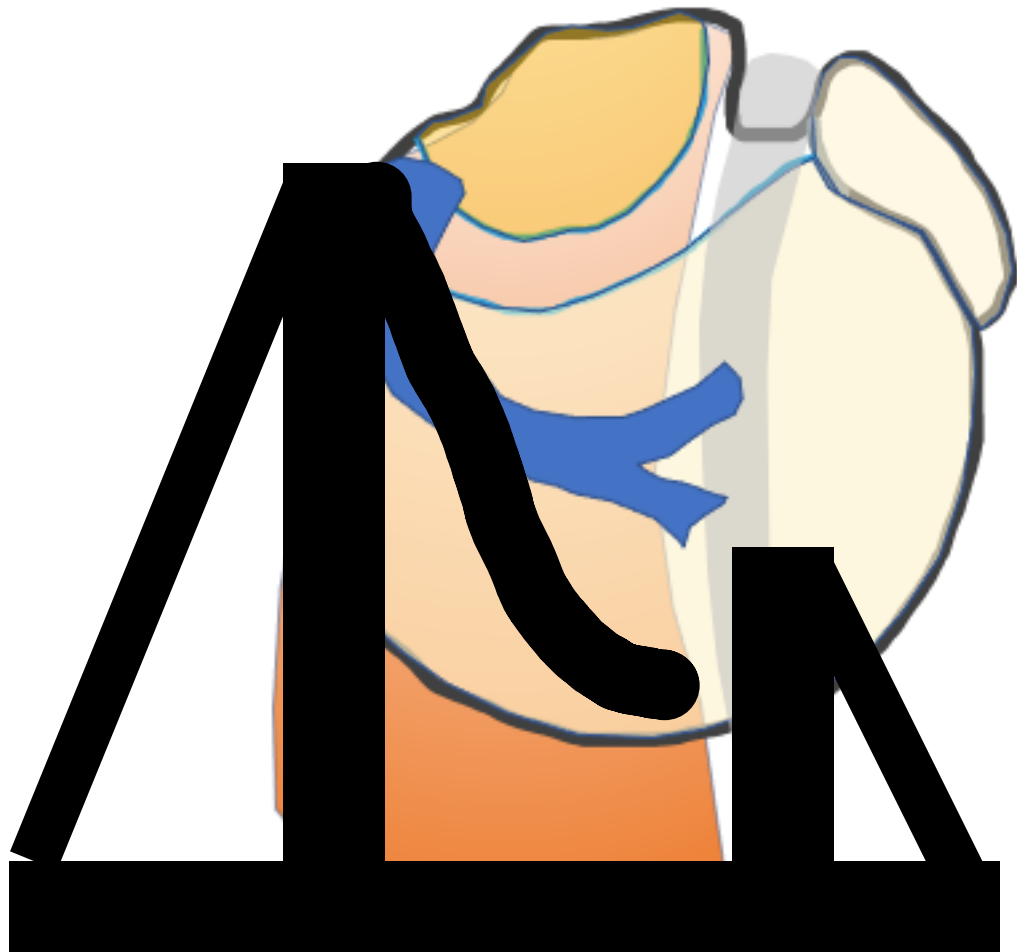
# Biomechanical suspension-bridge model for a rotator cuff tear



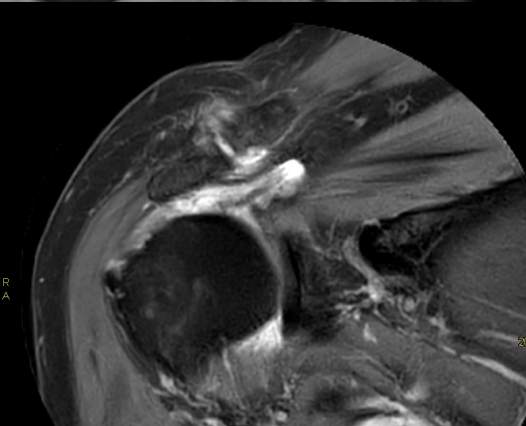
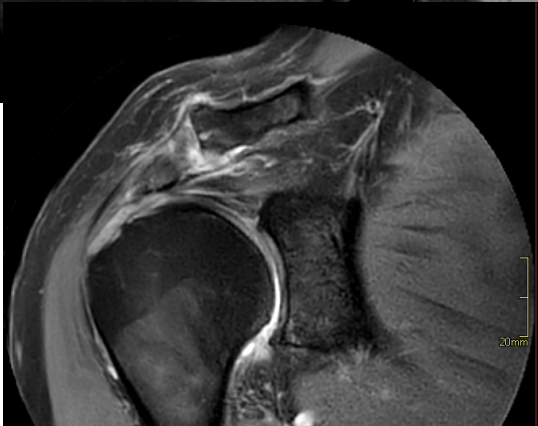
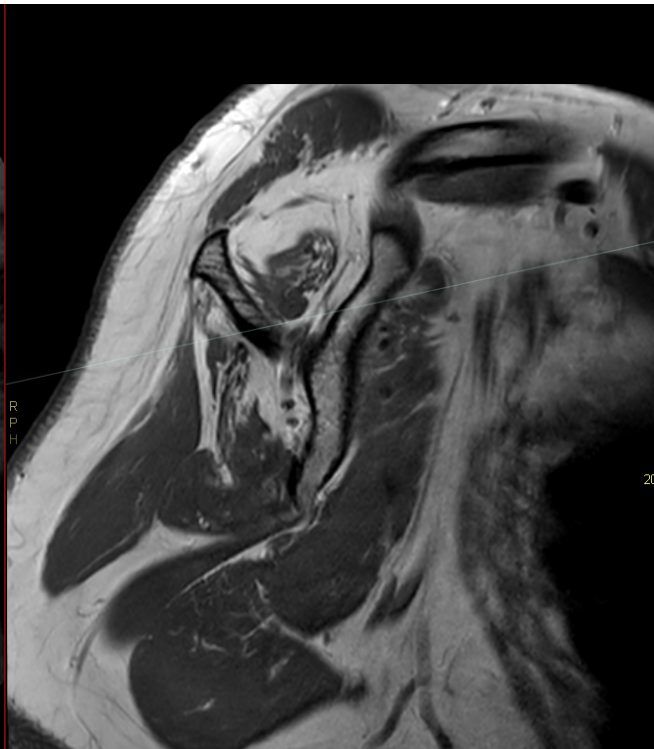
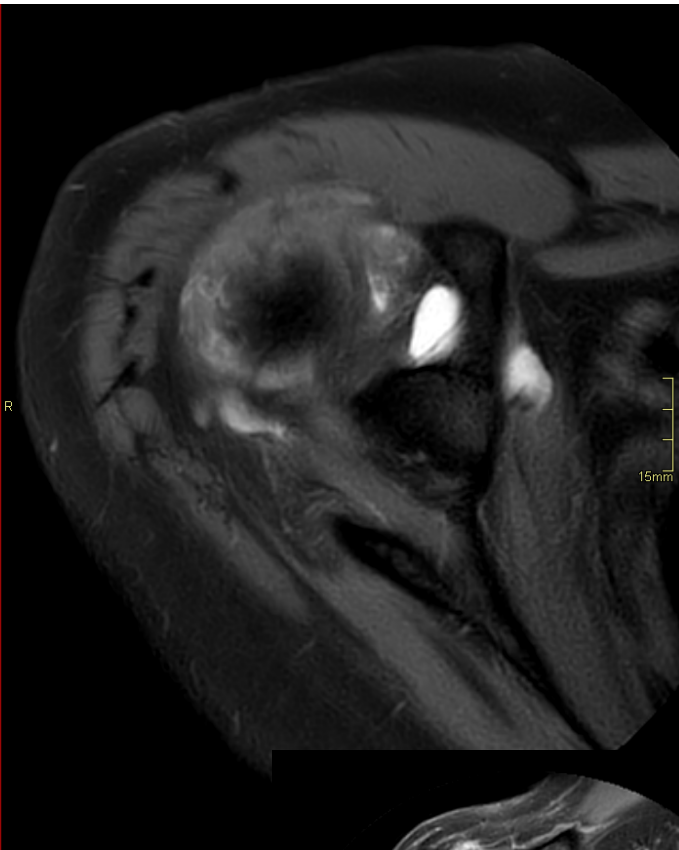
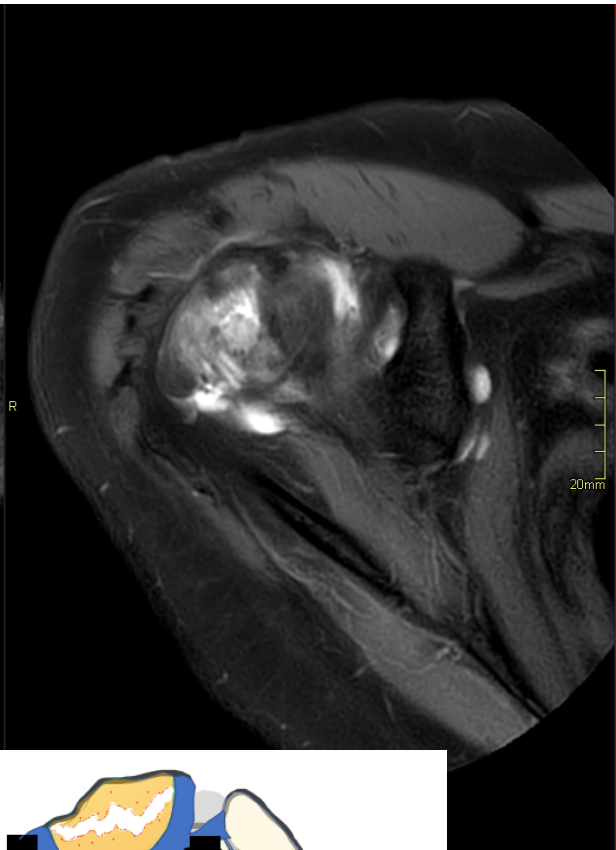
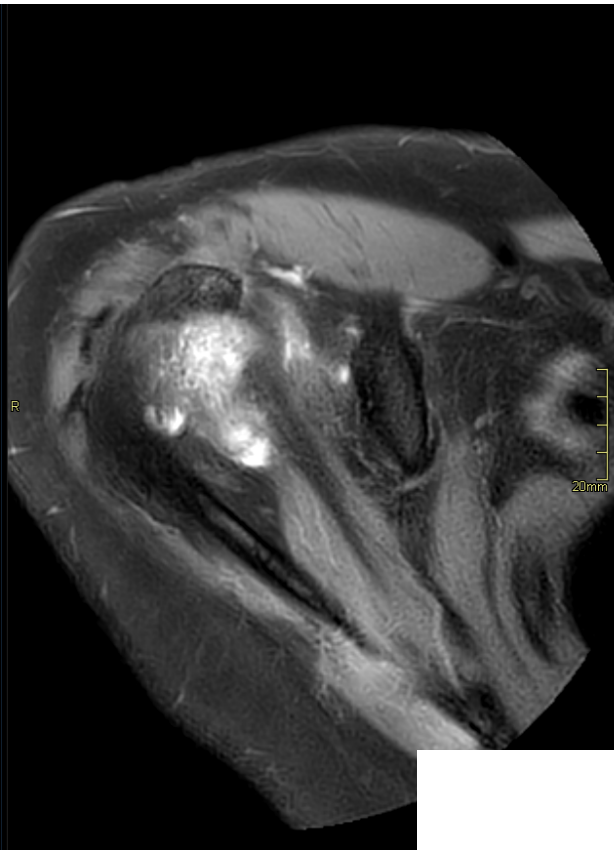
# Biomechanical suspension-bridge model for a rotator cuff tear



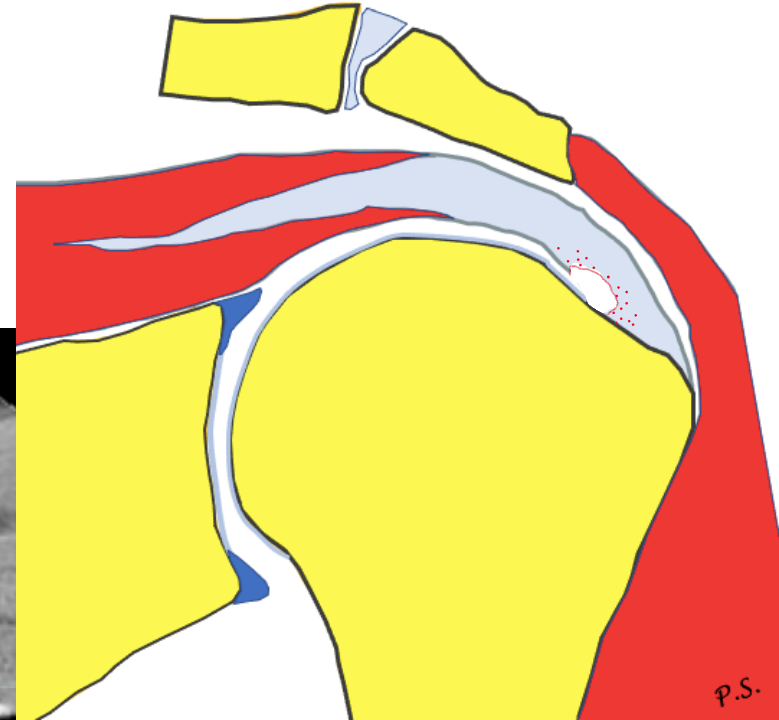
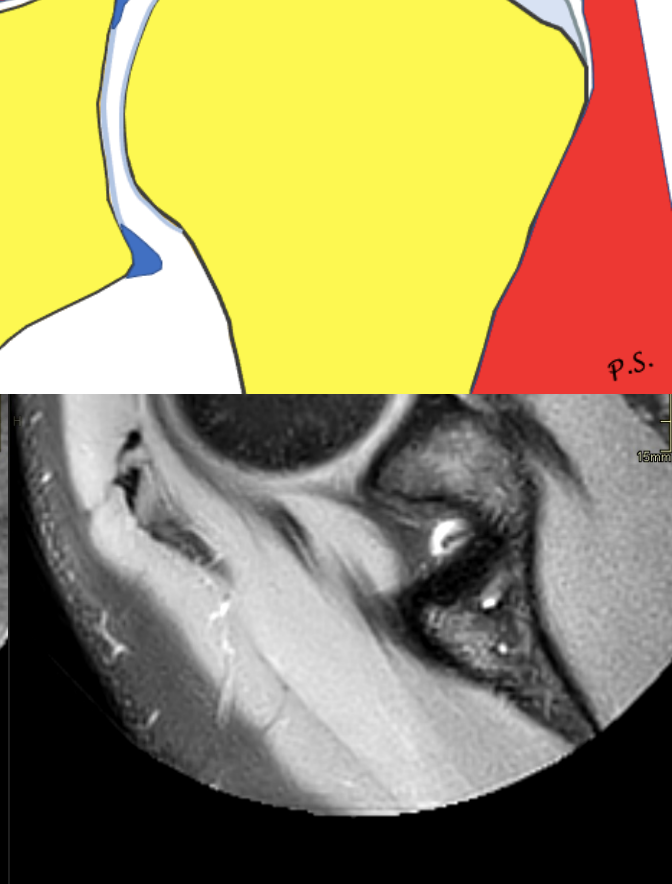
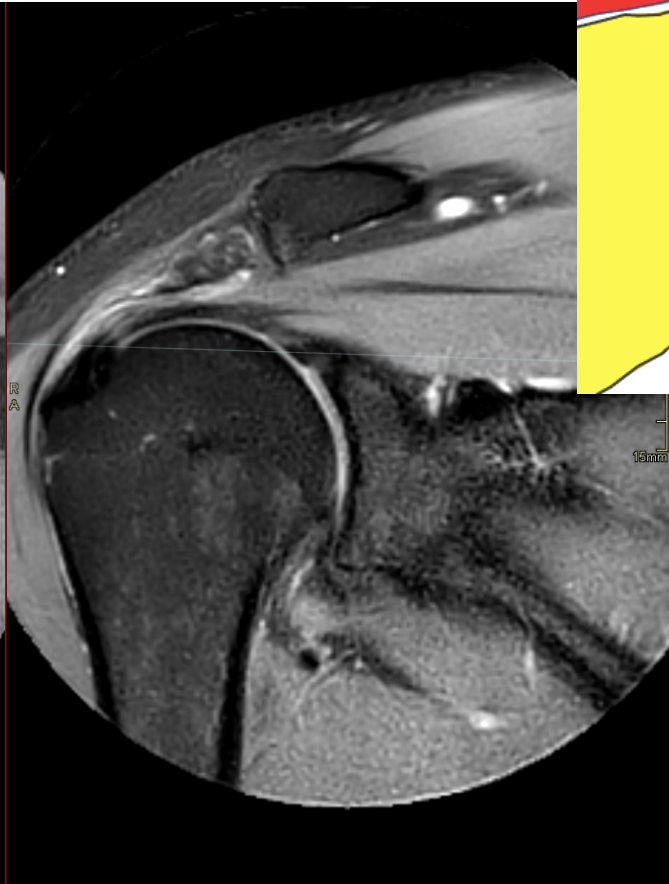
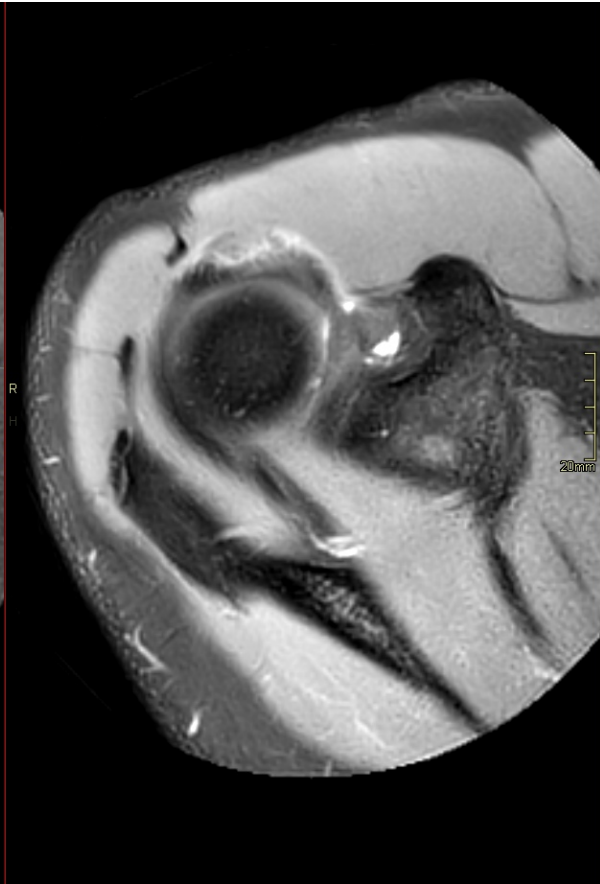
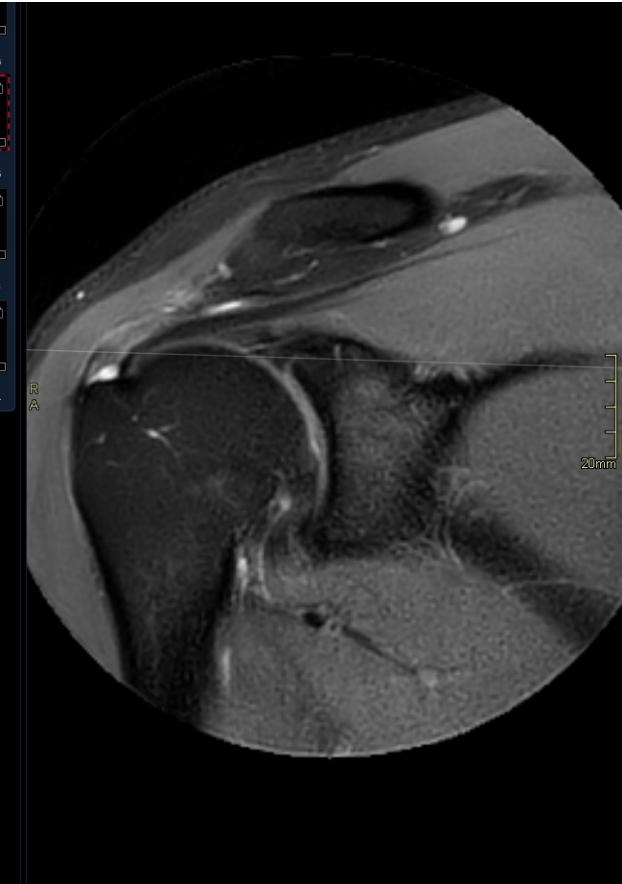
# Biomechanical suspension-bridge model for a rotator cuff tear



# Kabel

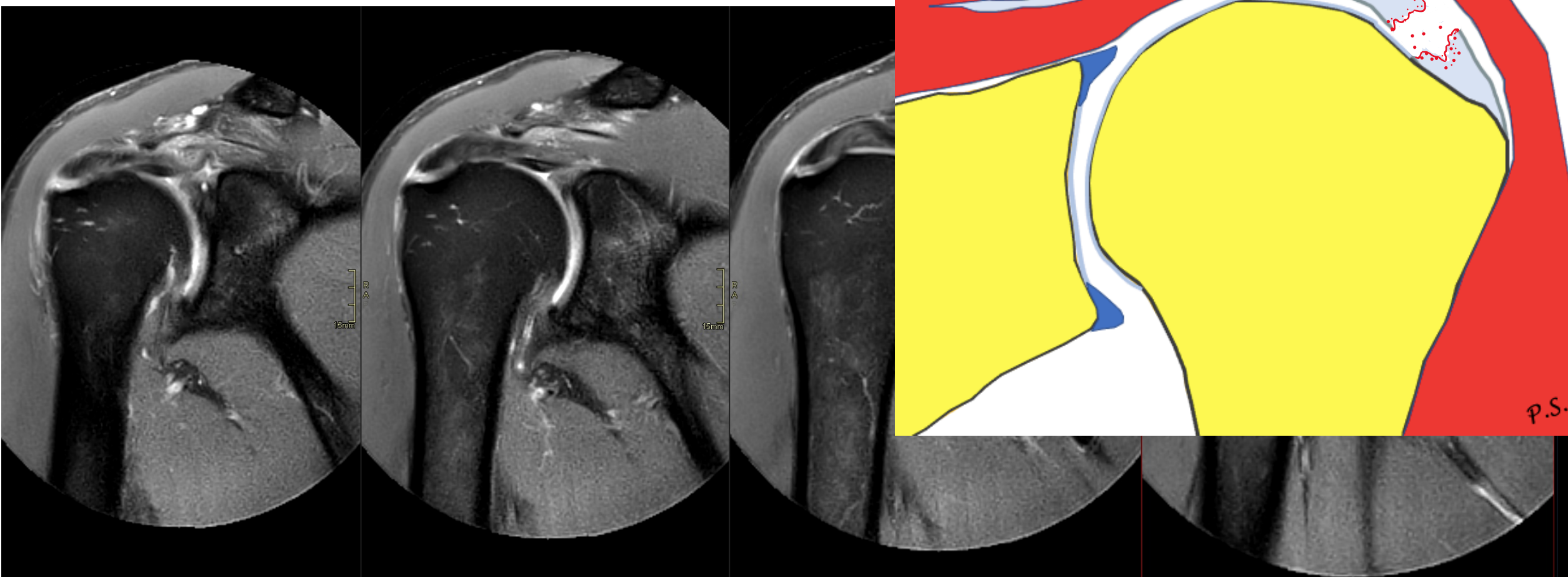


# Rupture

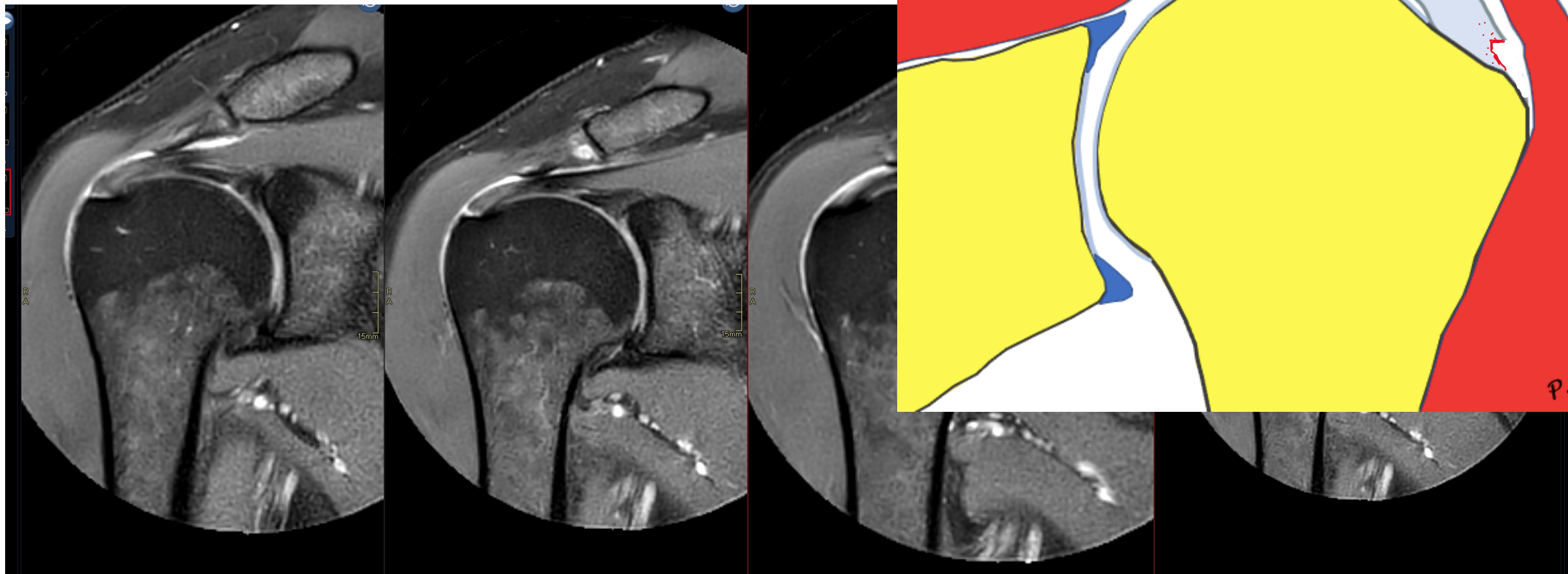




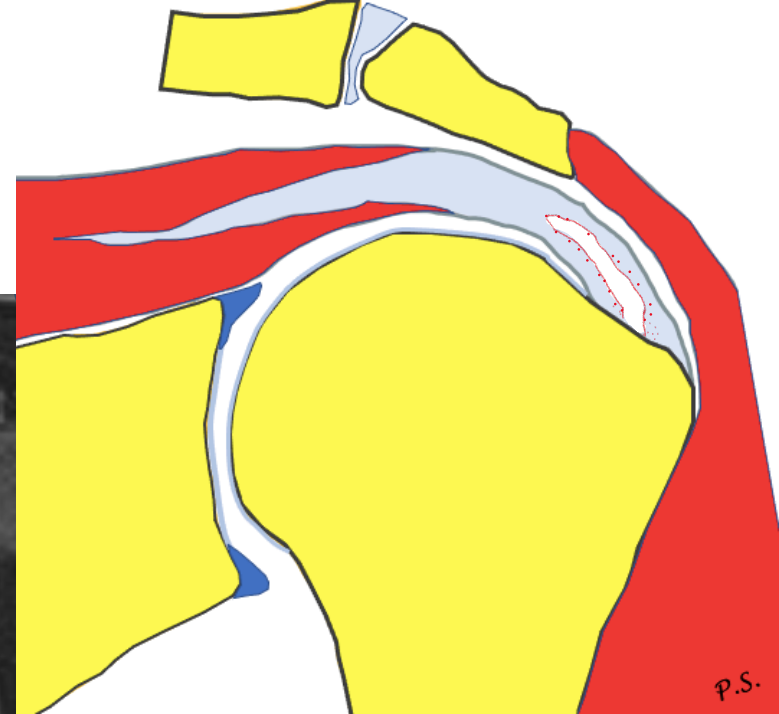

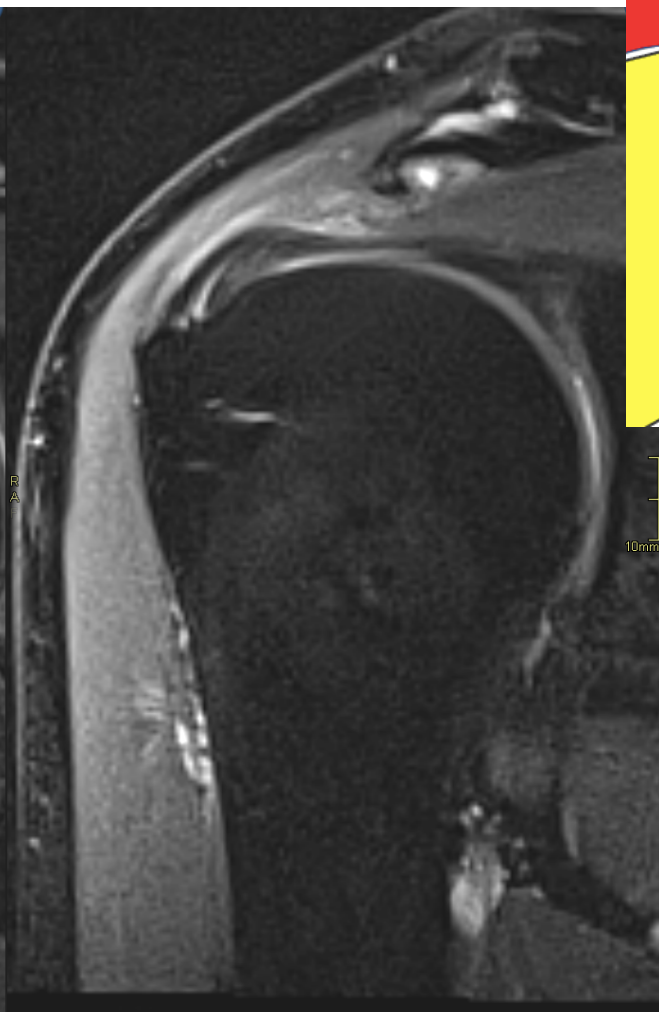
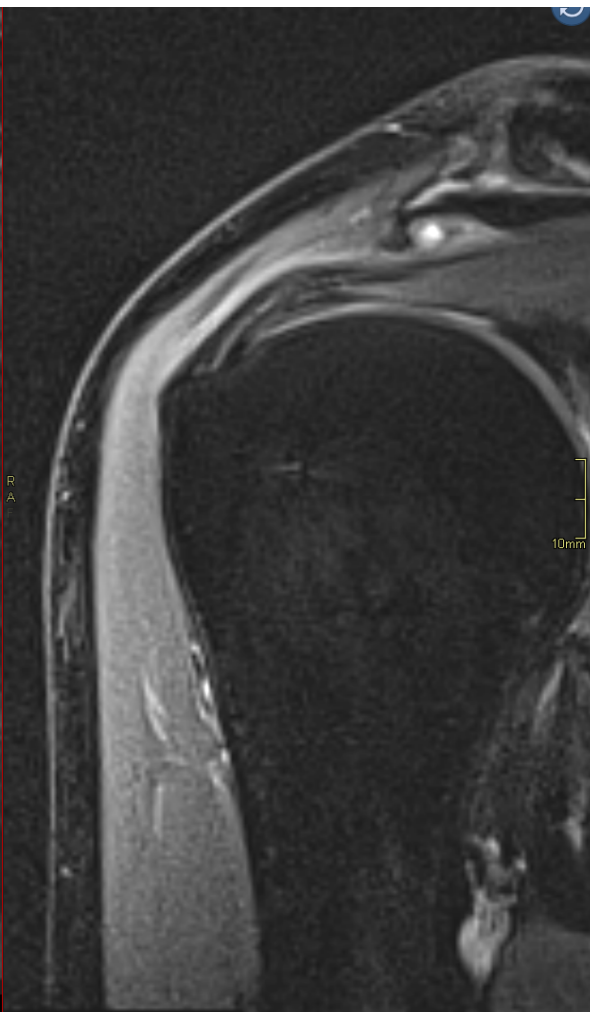
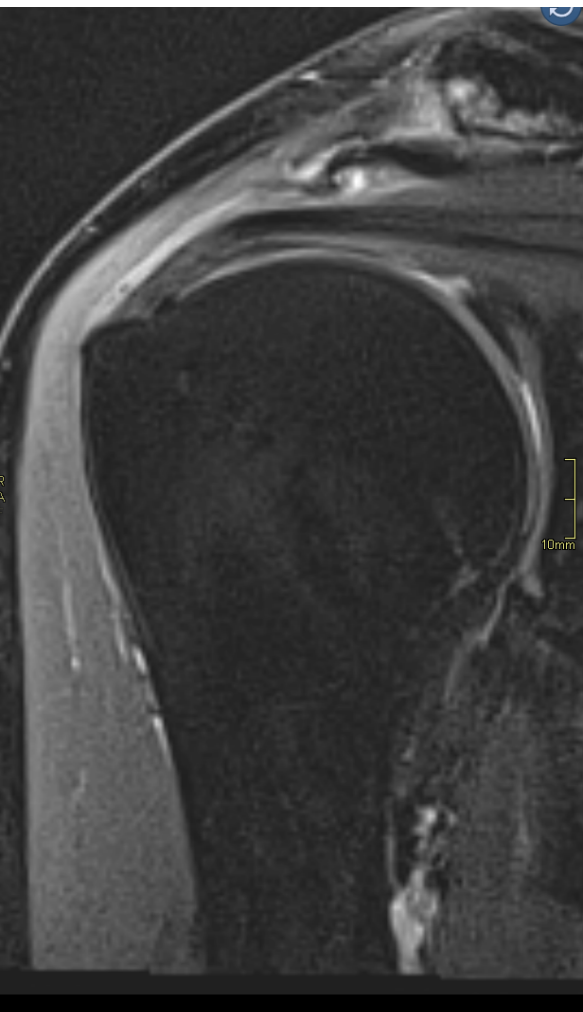
# Rupture



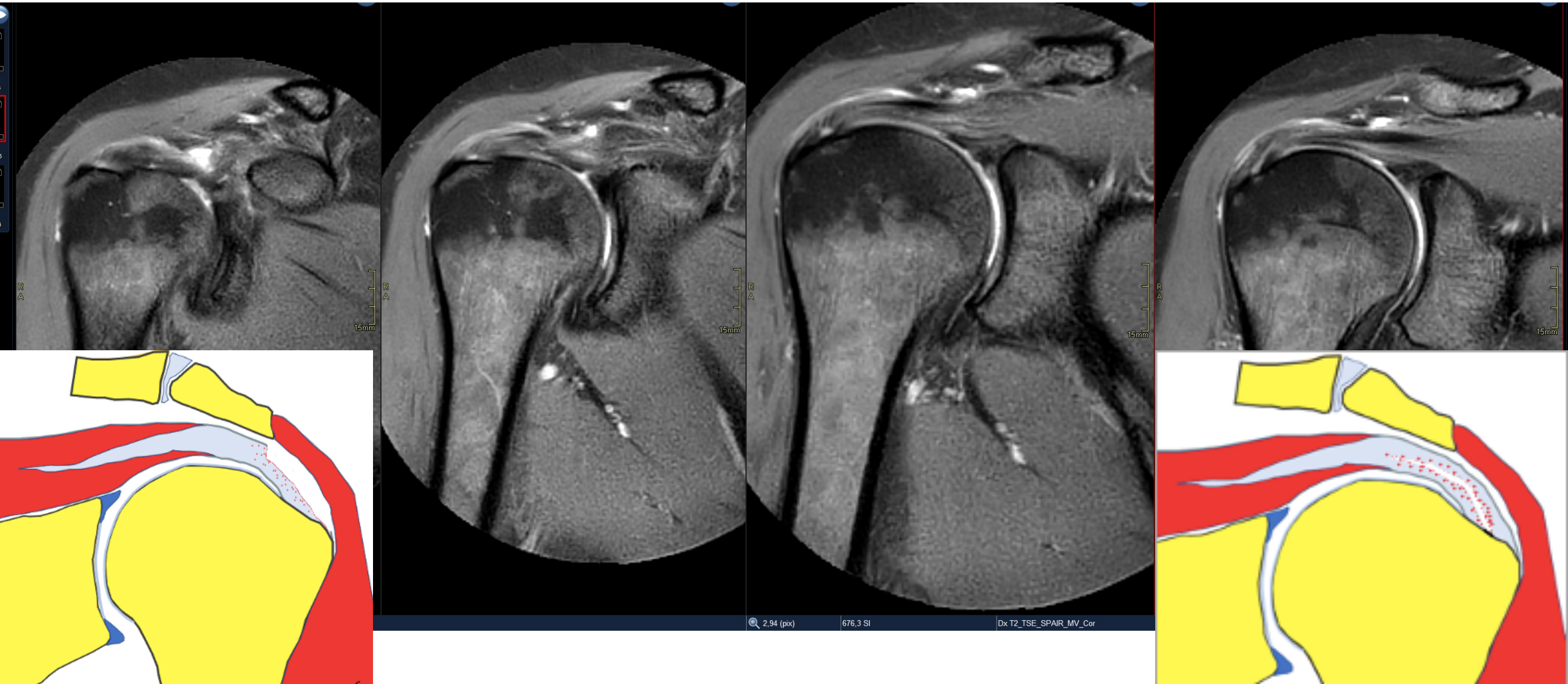
# Rupture



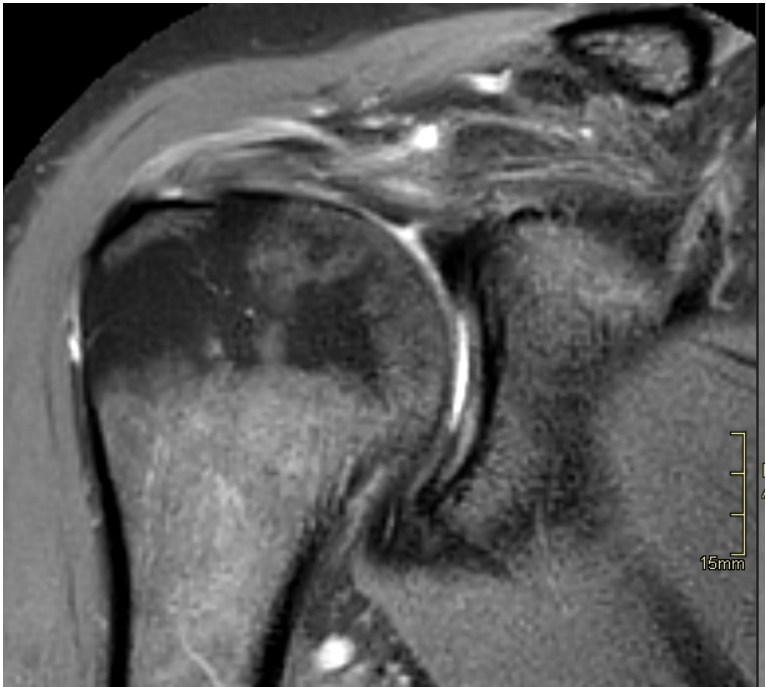
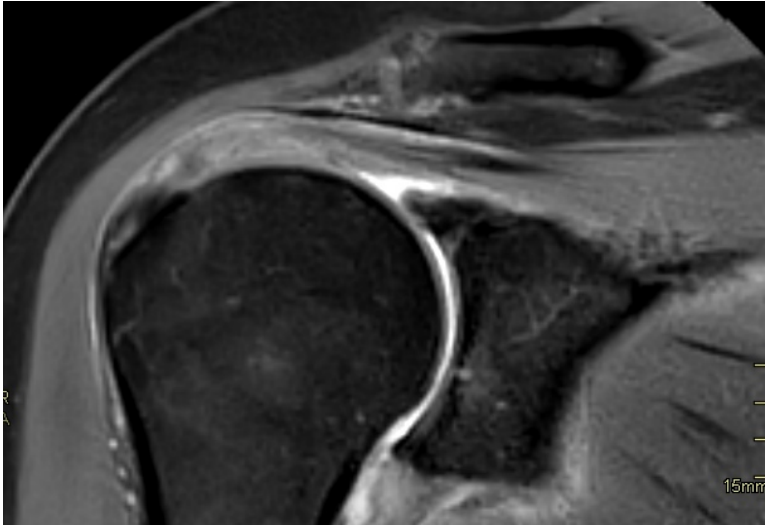
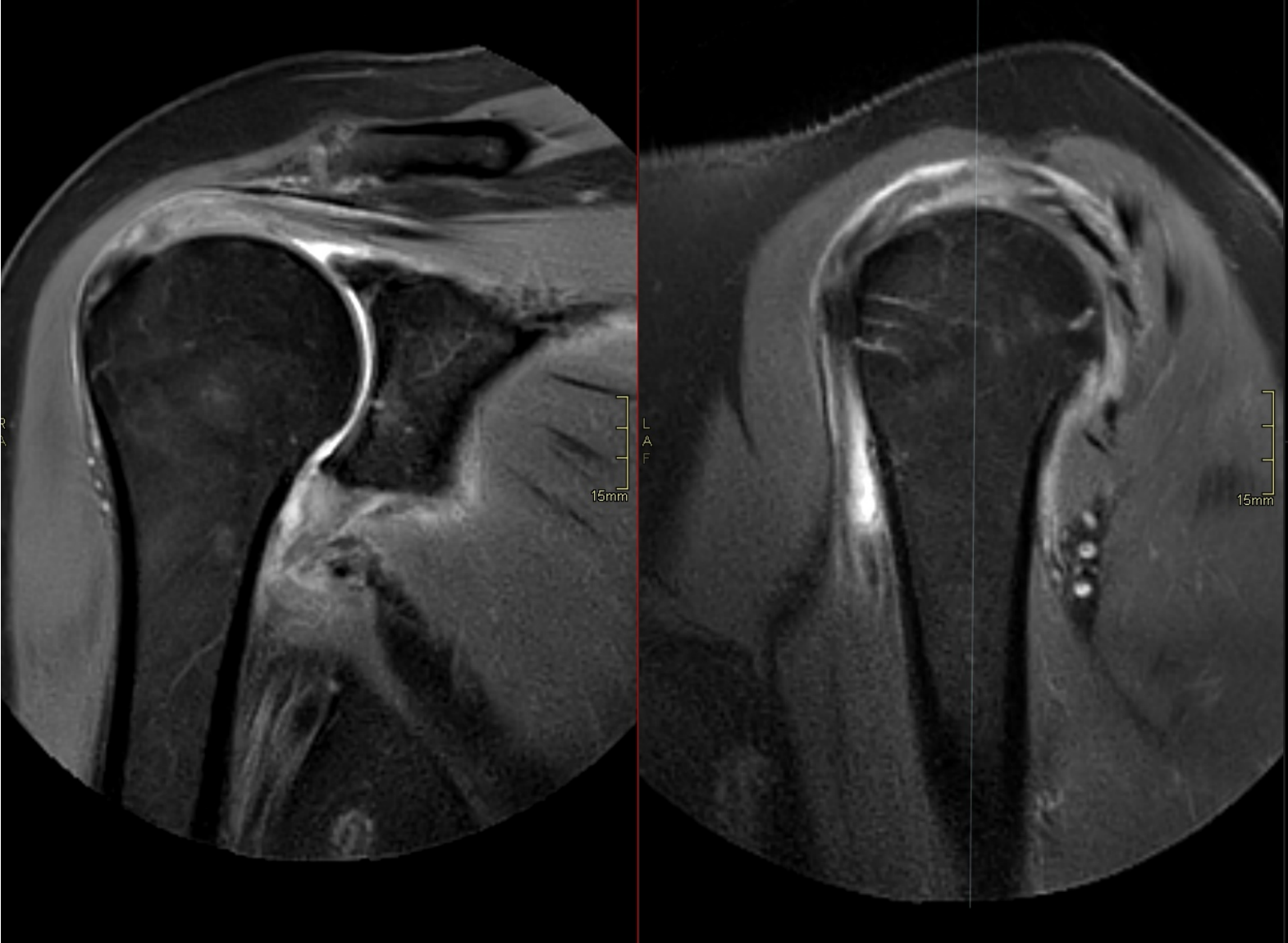
# Rupture



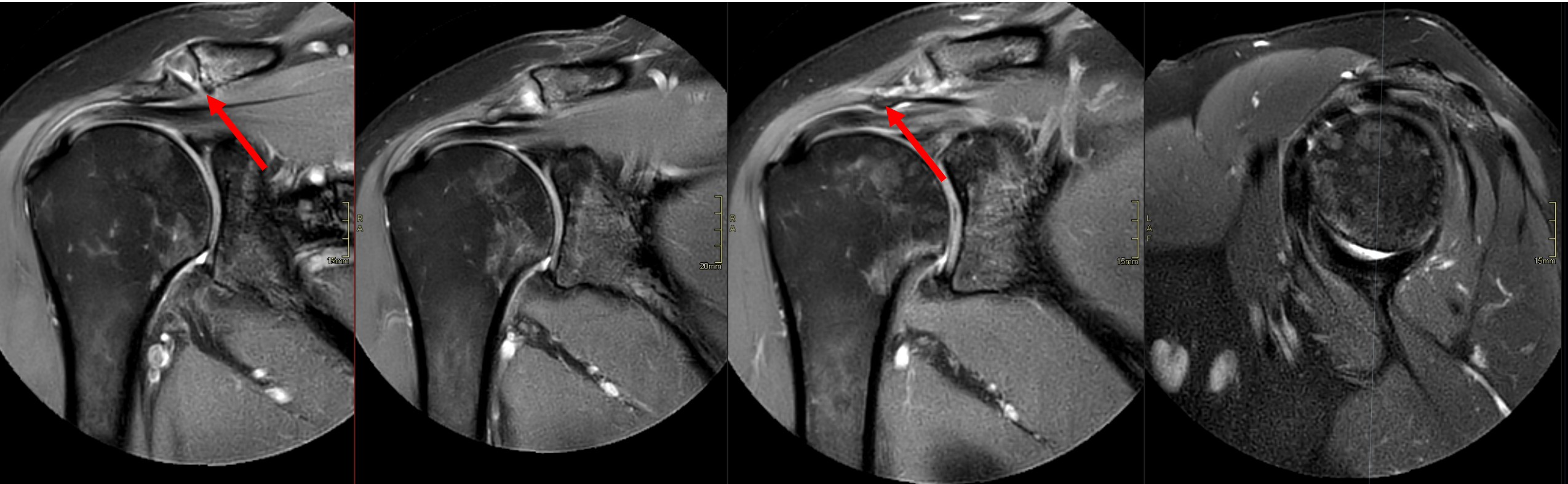
# Rupture



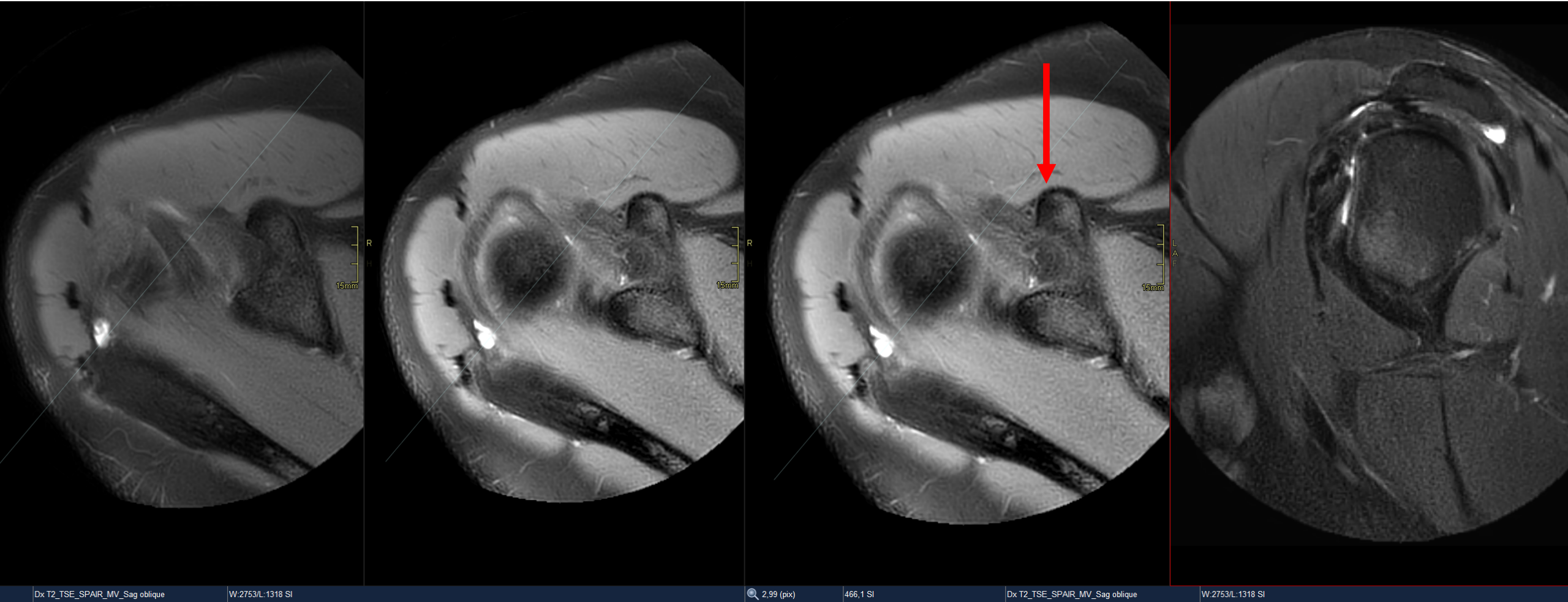
# Tendinosis



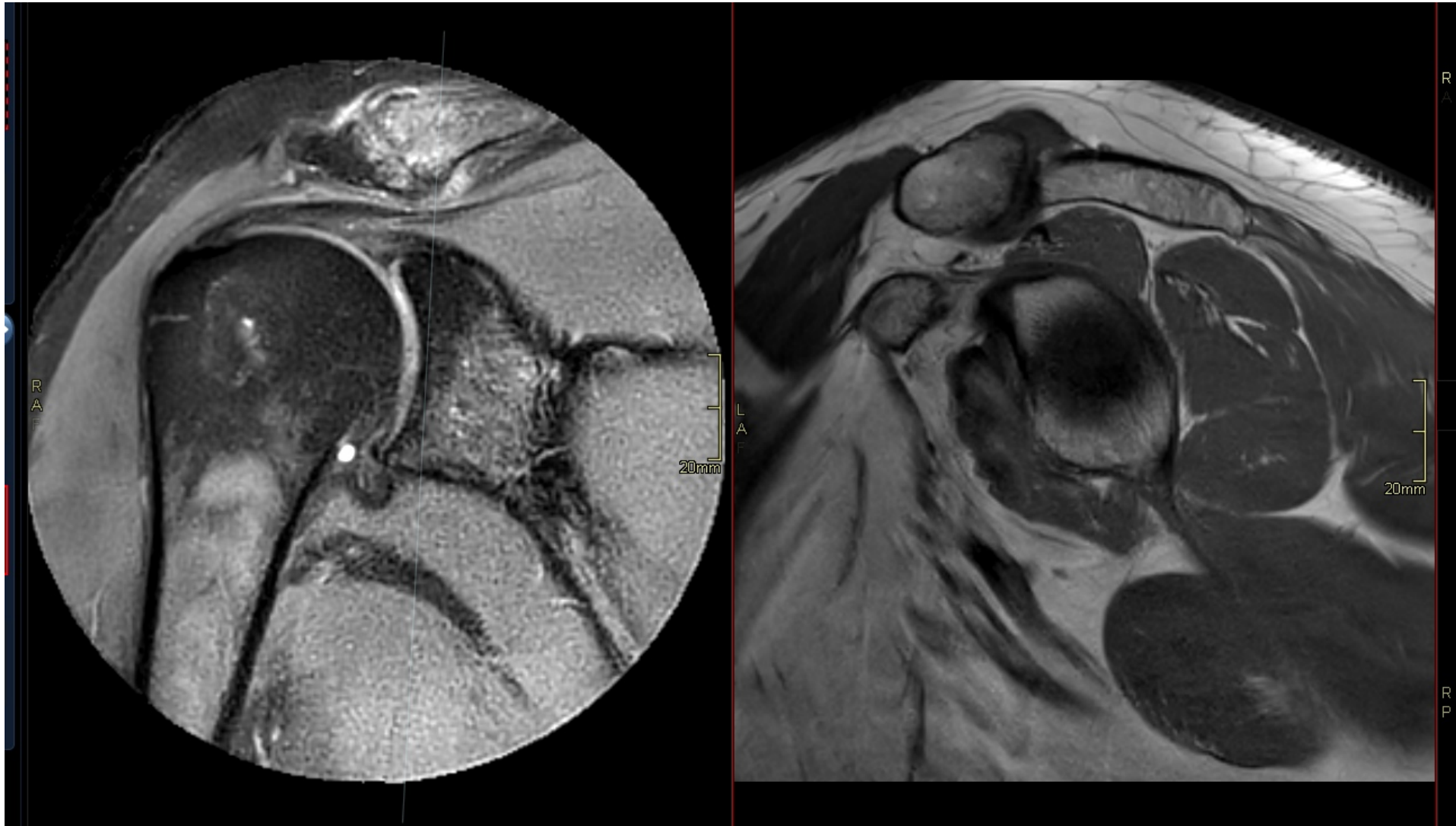
# Impingement



# Impingement

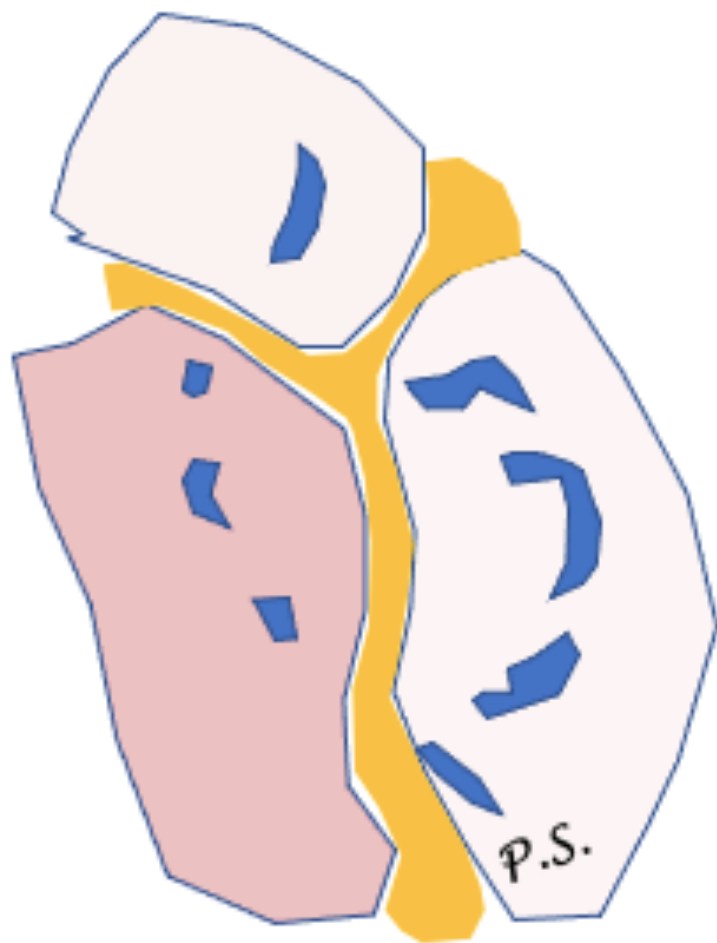


# Impingement

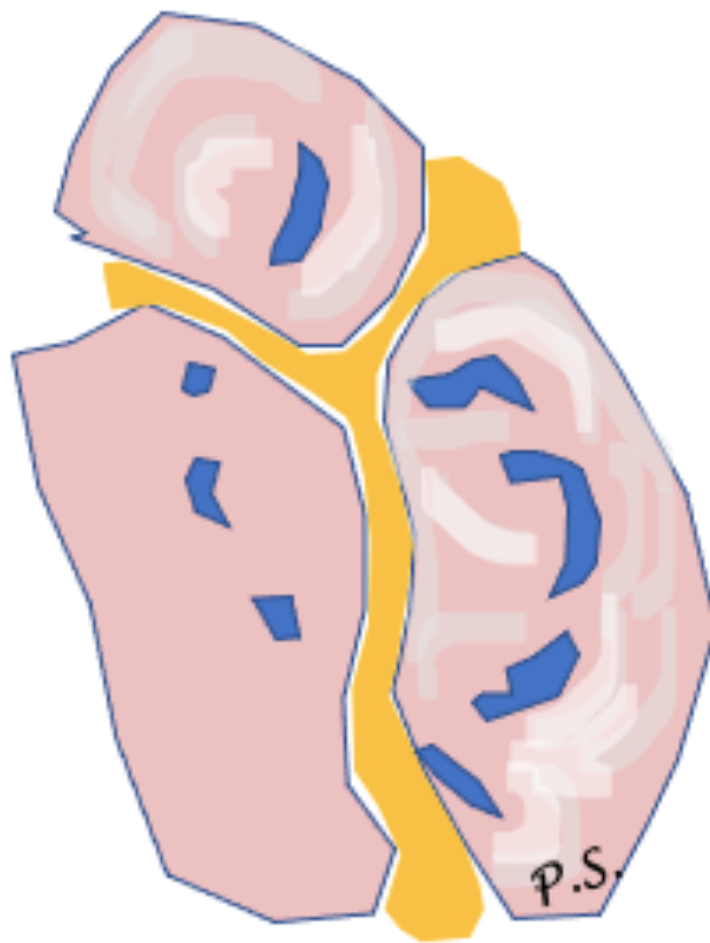




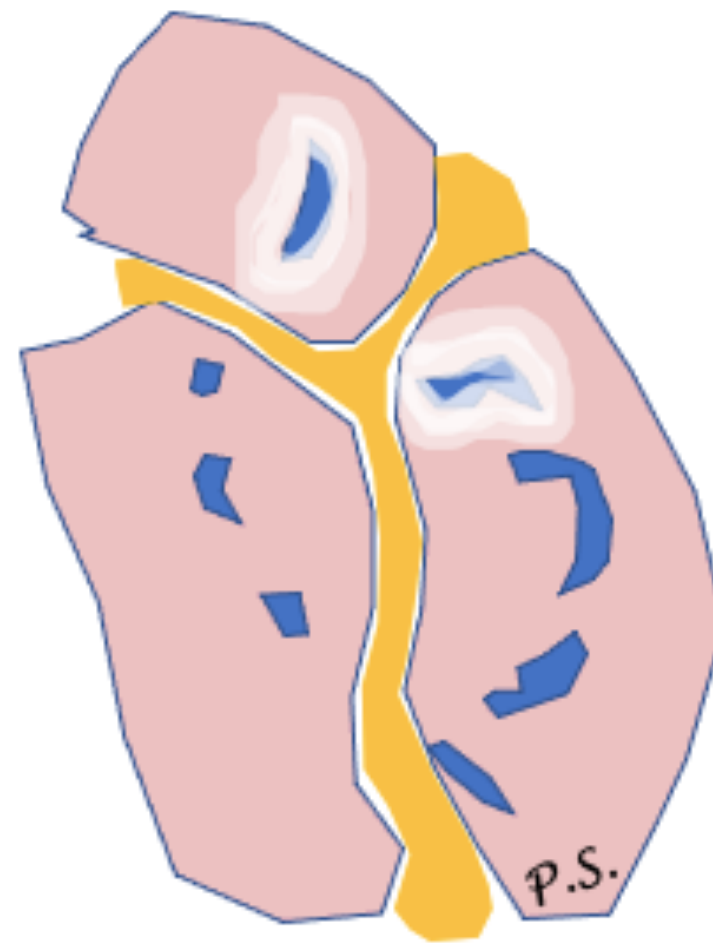
# Nerve



Nerve entrapment

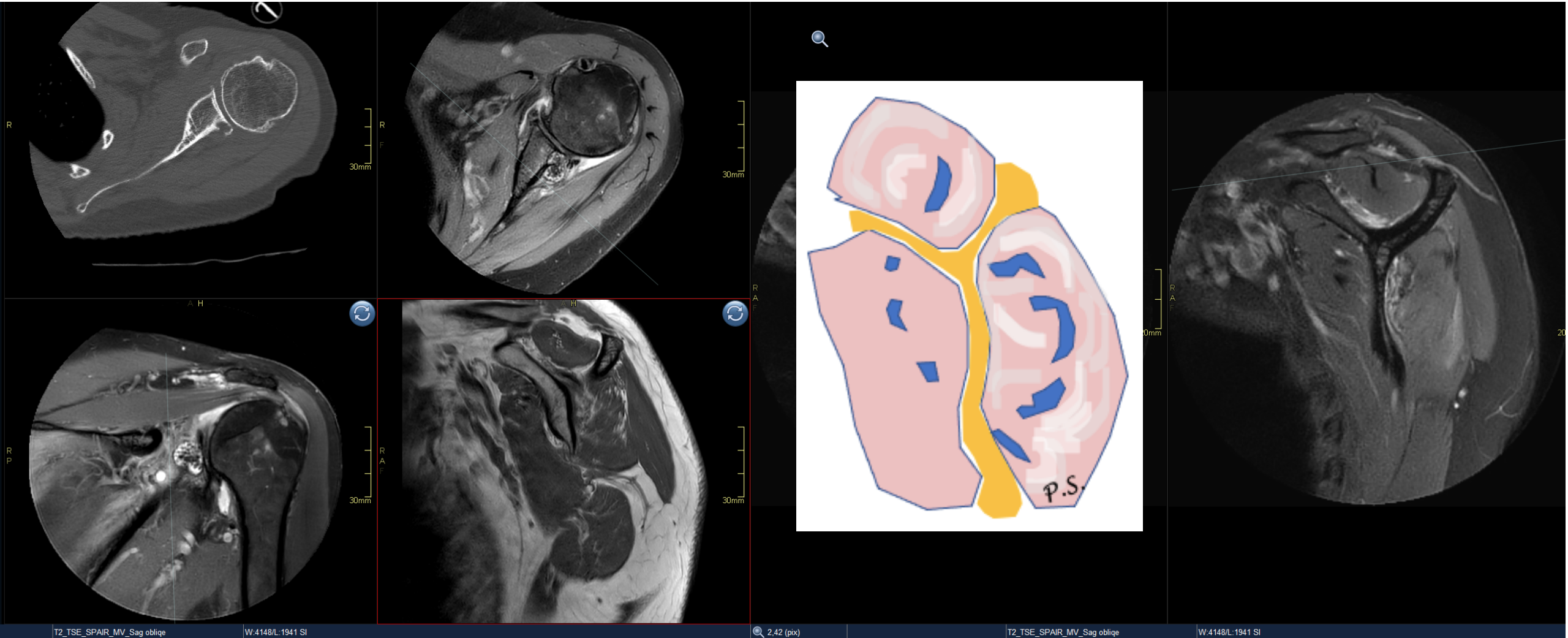


Parsonage-Turner syndrome  
(neuritis)

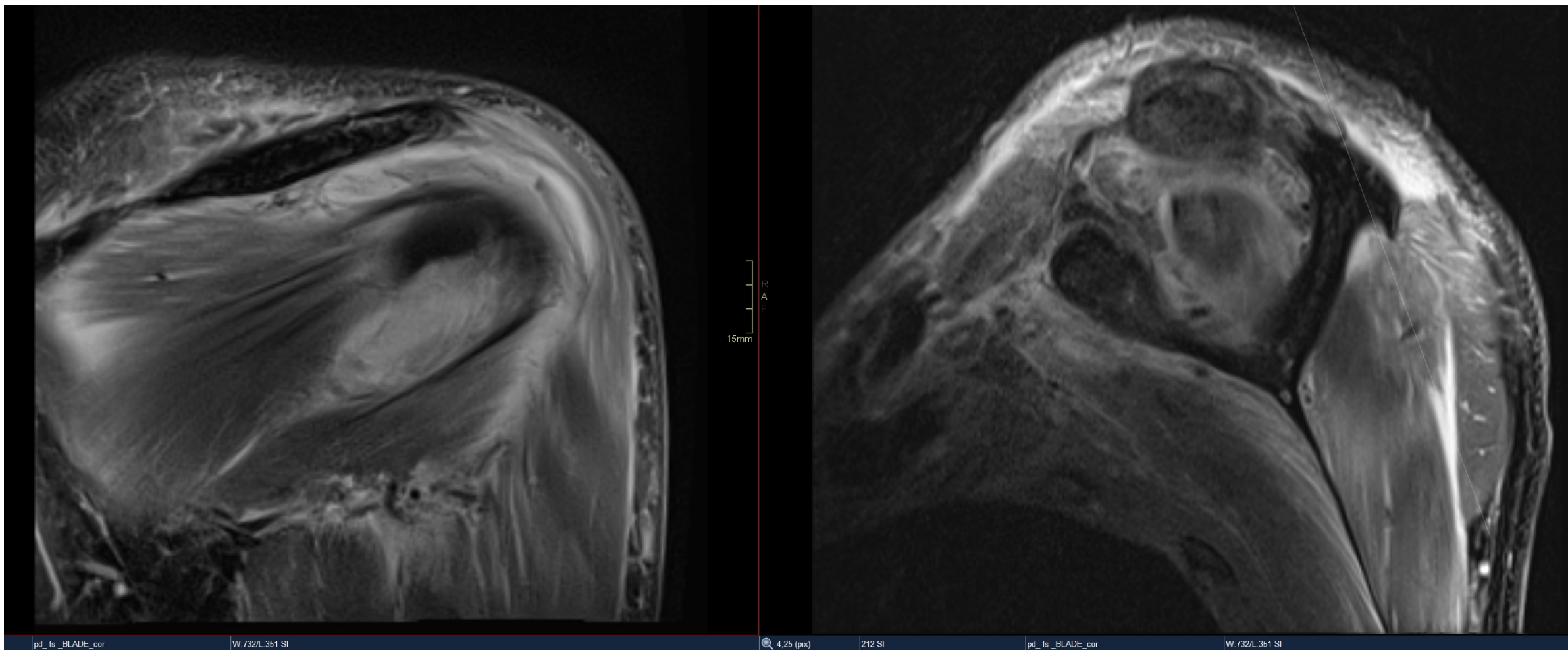


Trauma

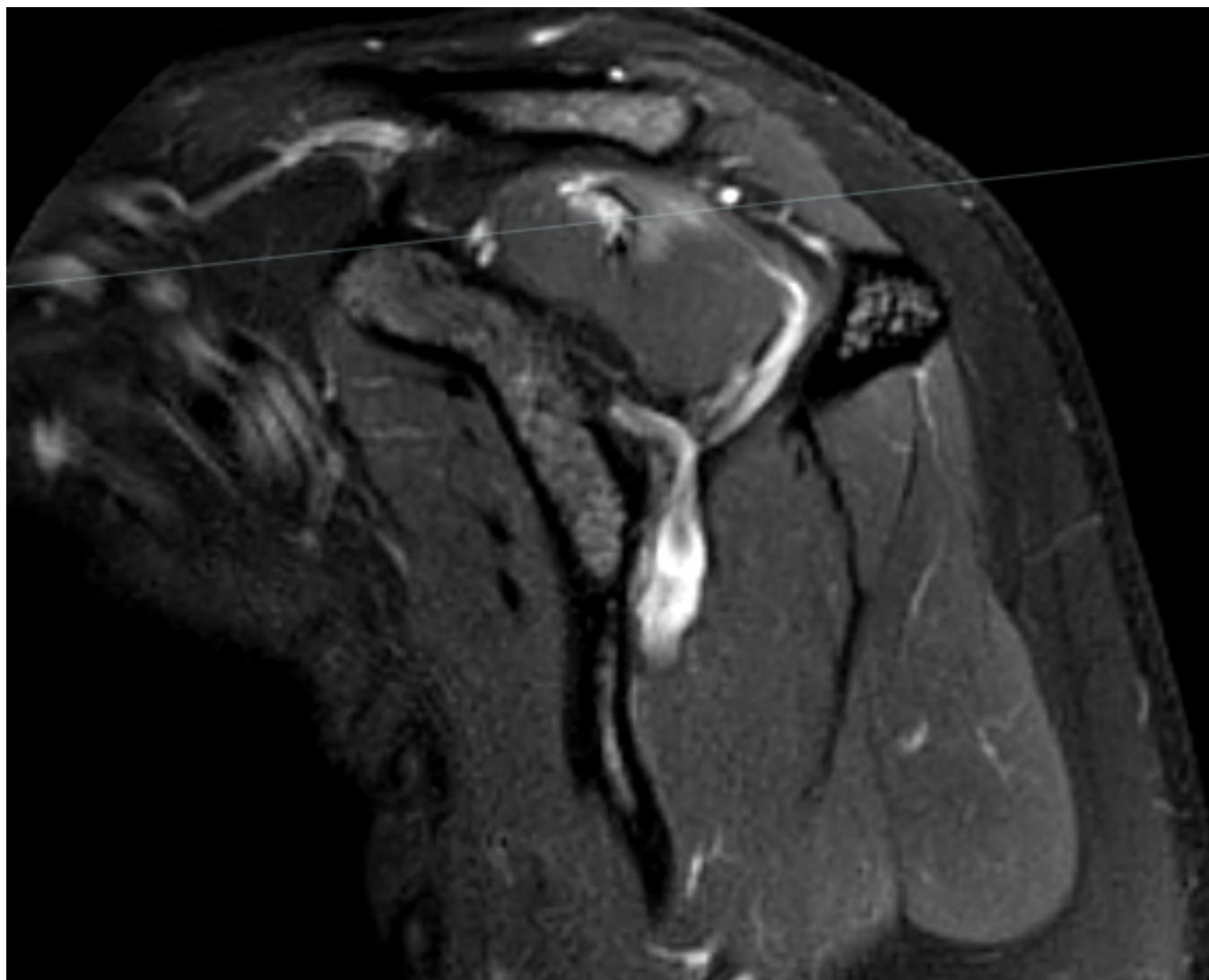
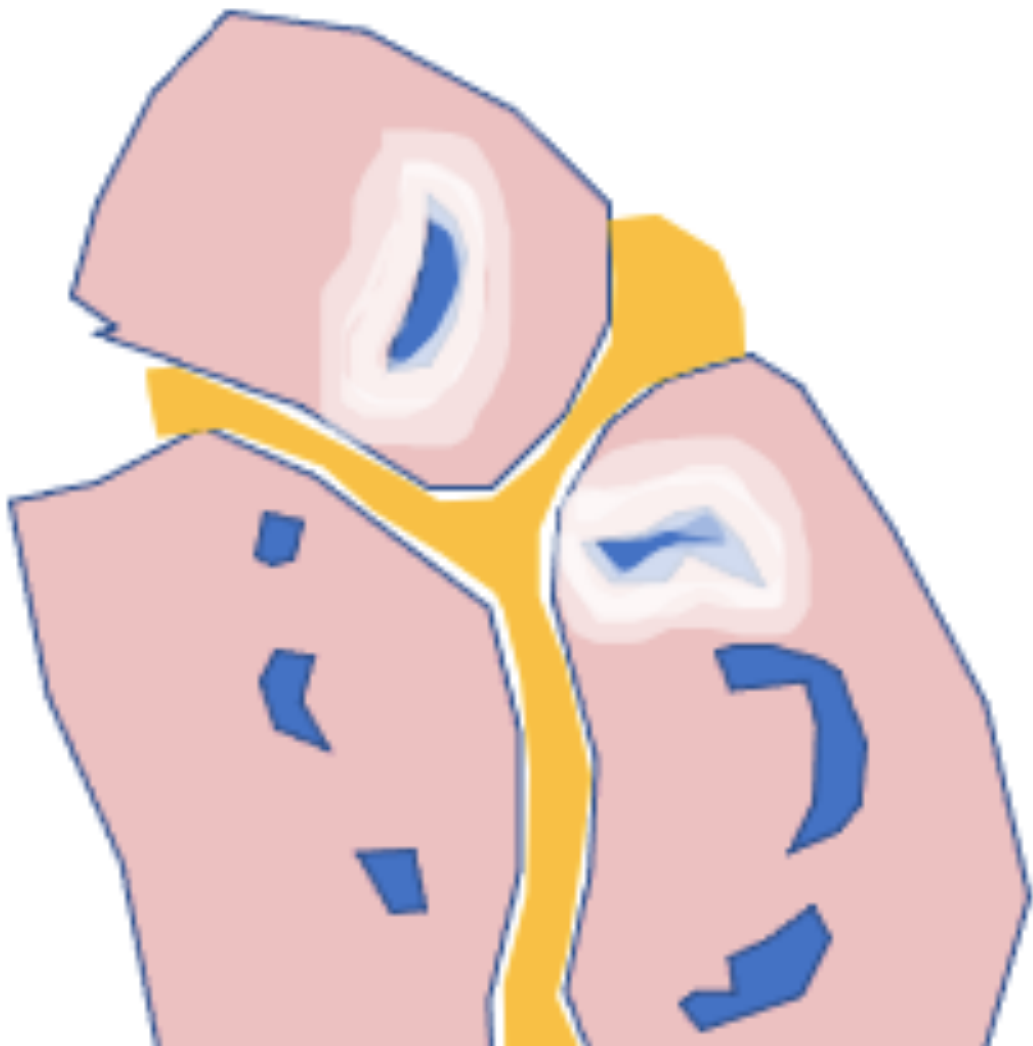
# Muscle



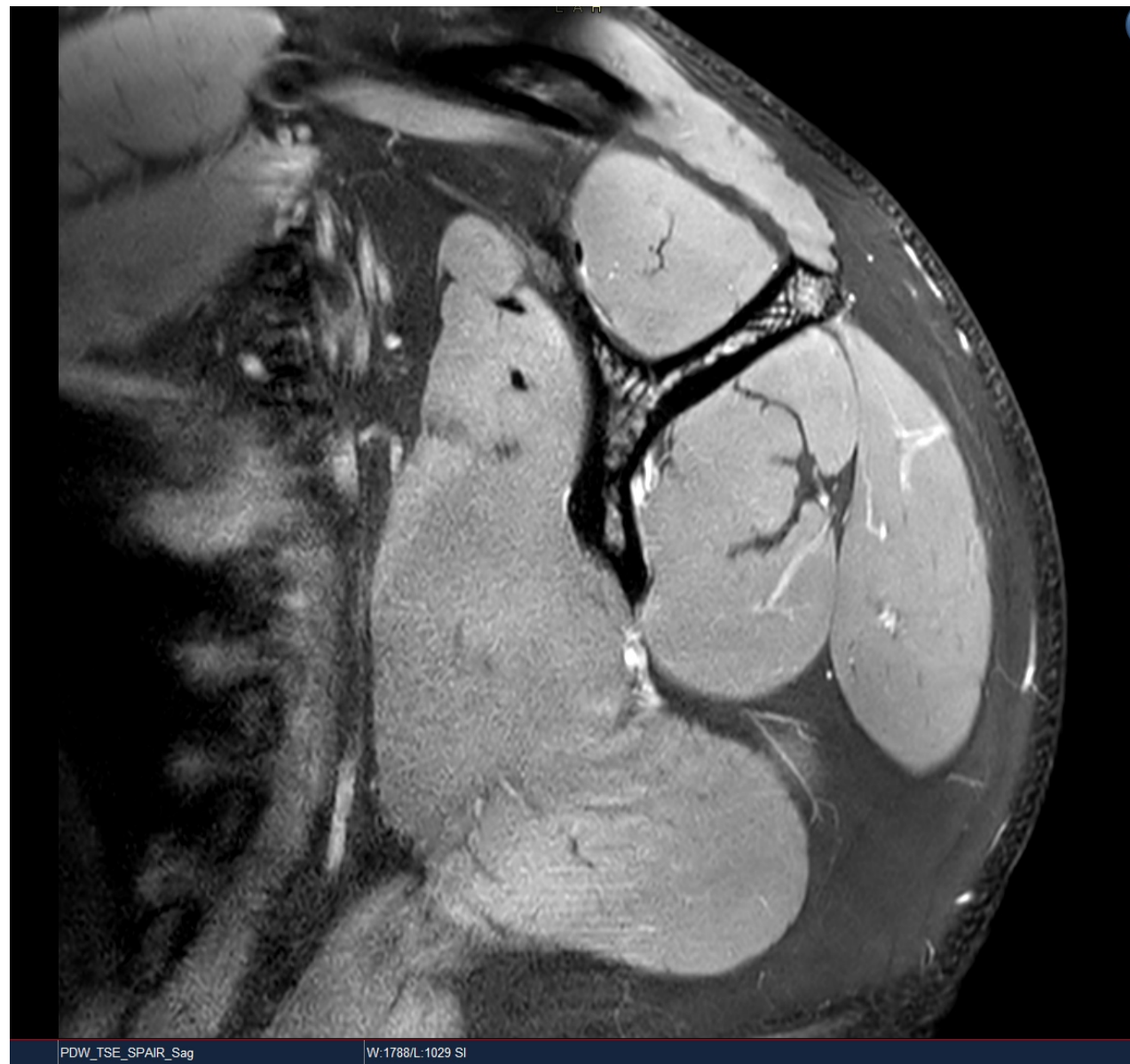
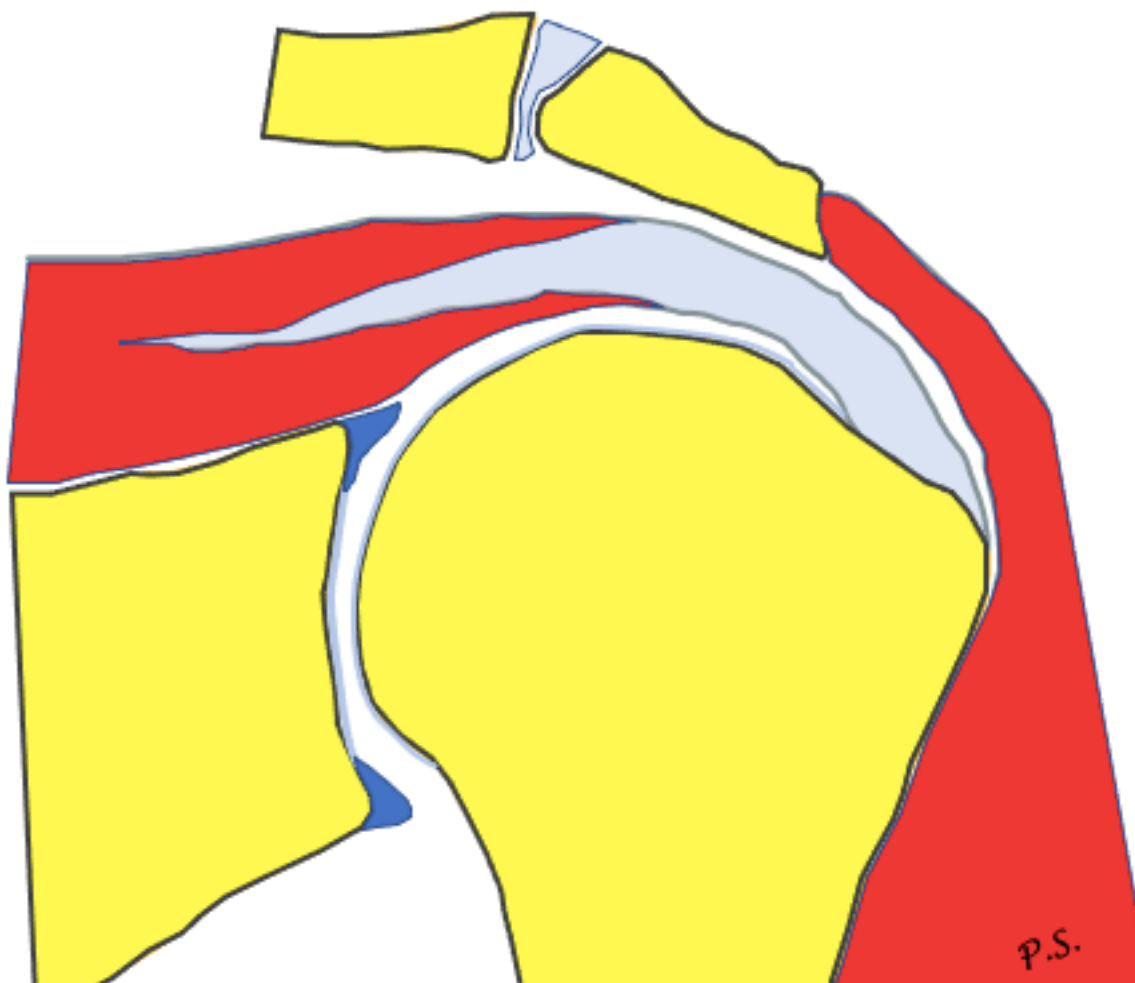
# Muscle



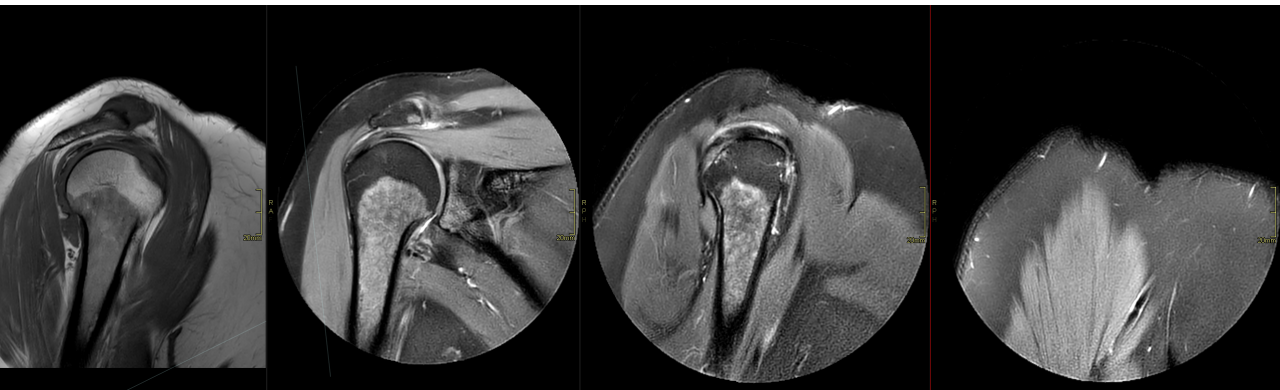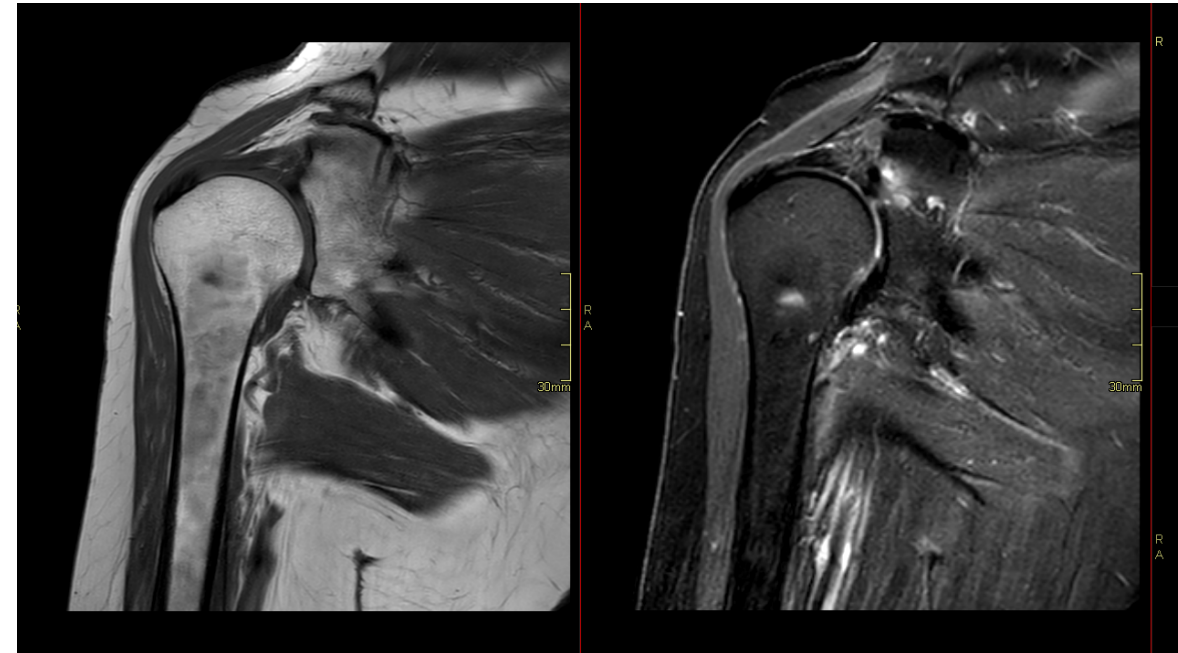
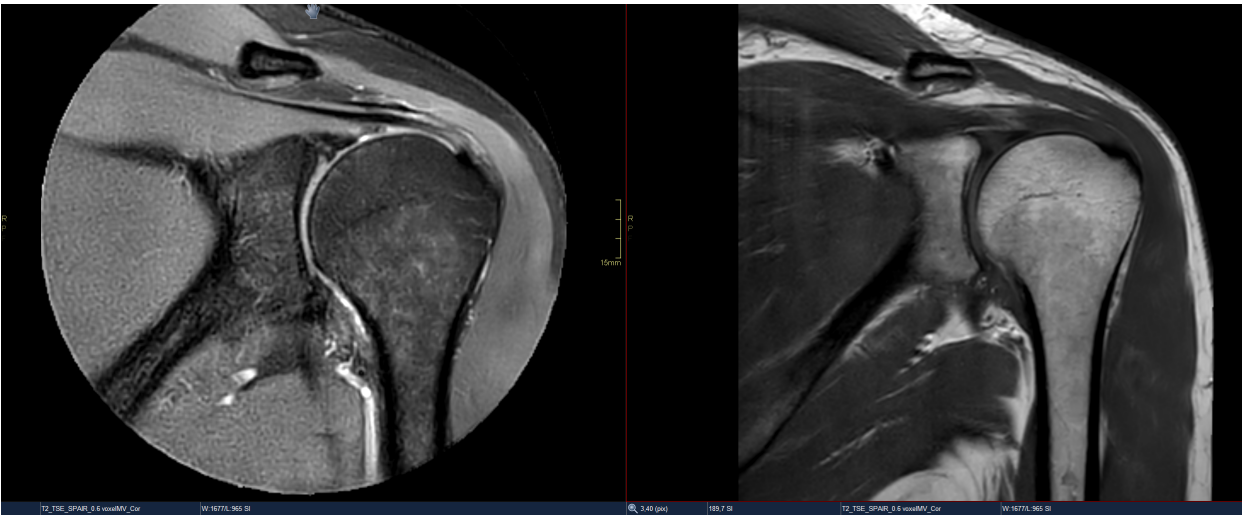
# Muscle



# Muscle



# Bone marrow

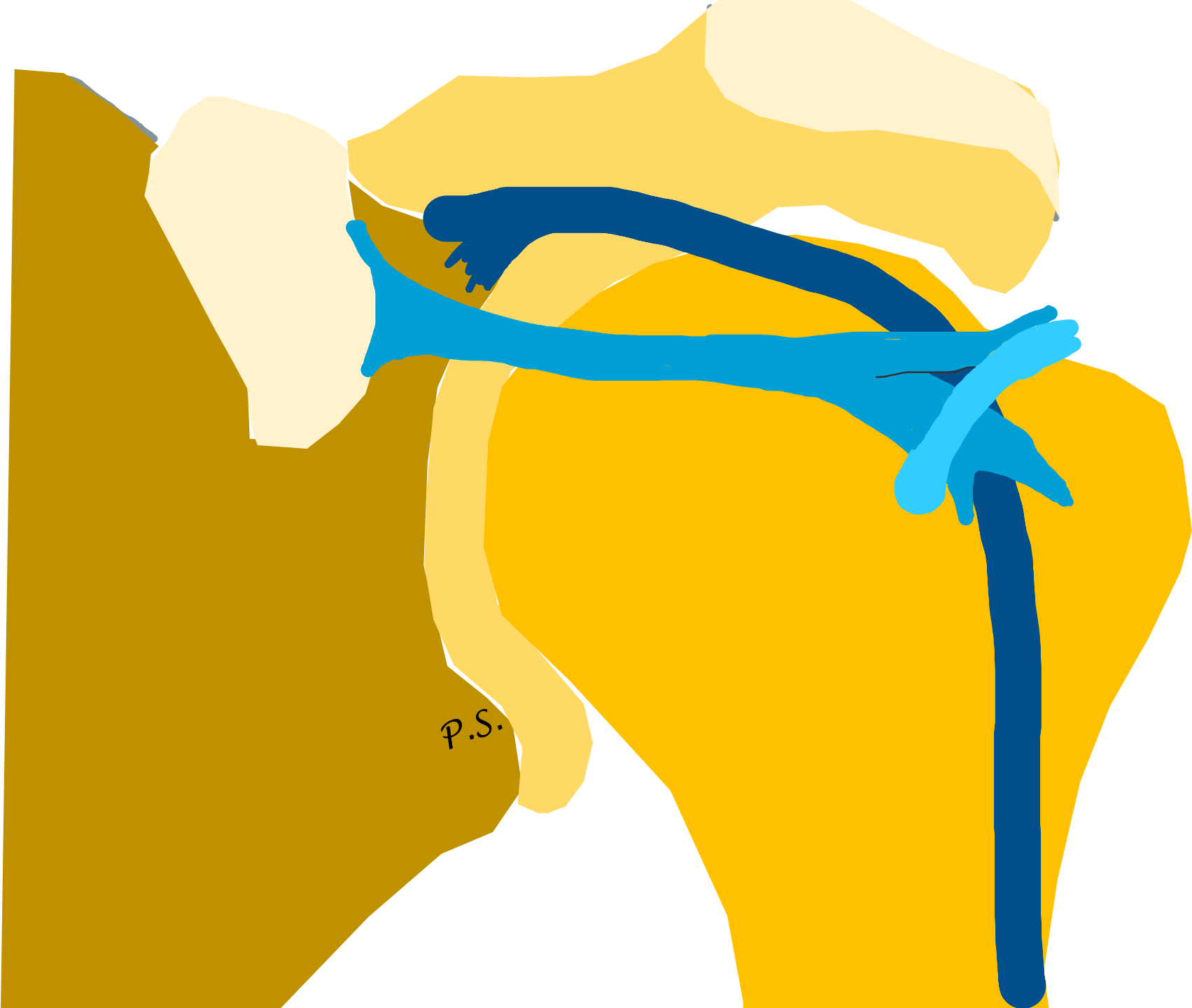


Rotator interval



P.S.






P.S.



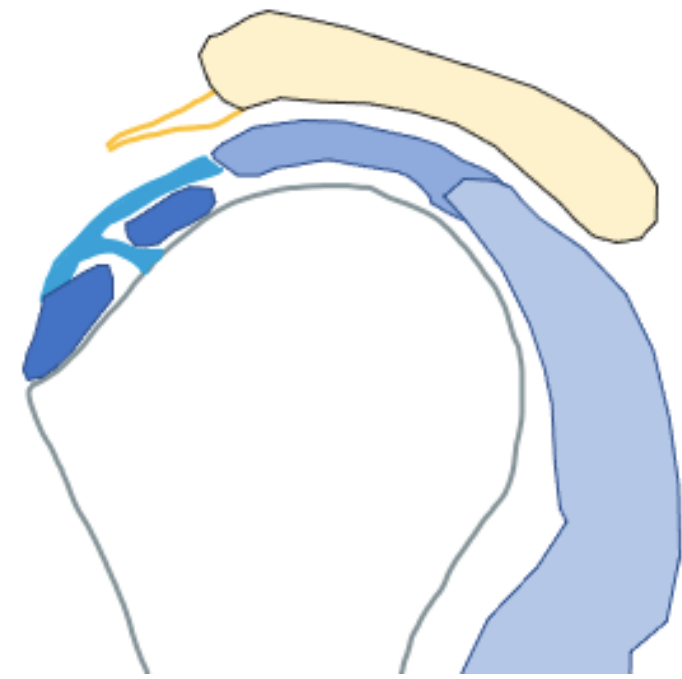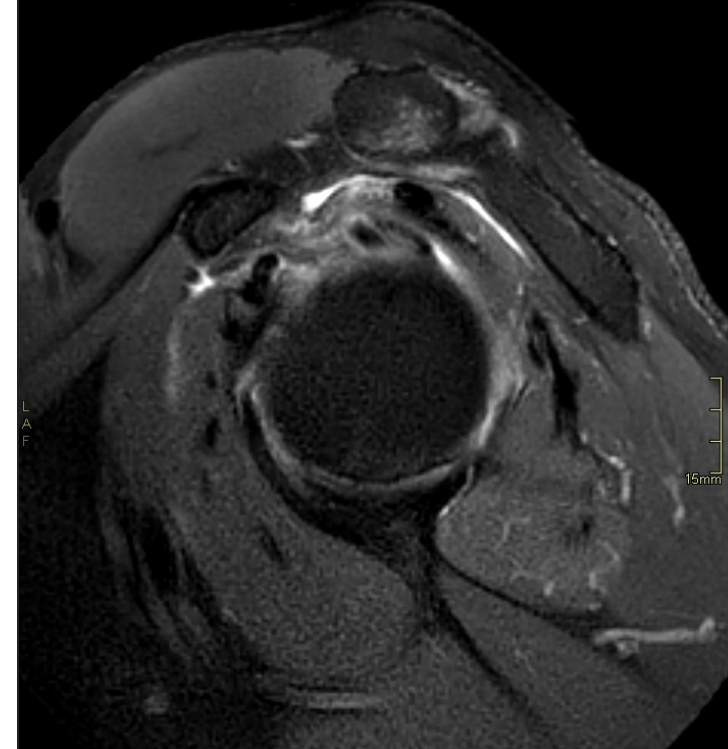
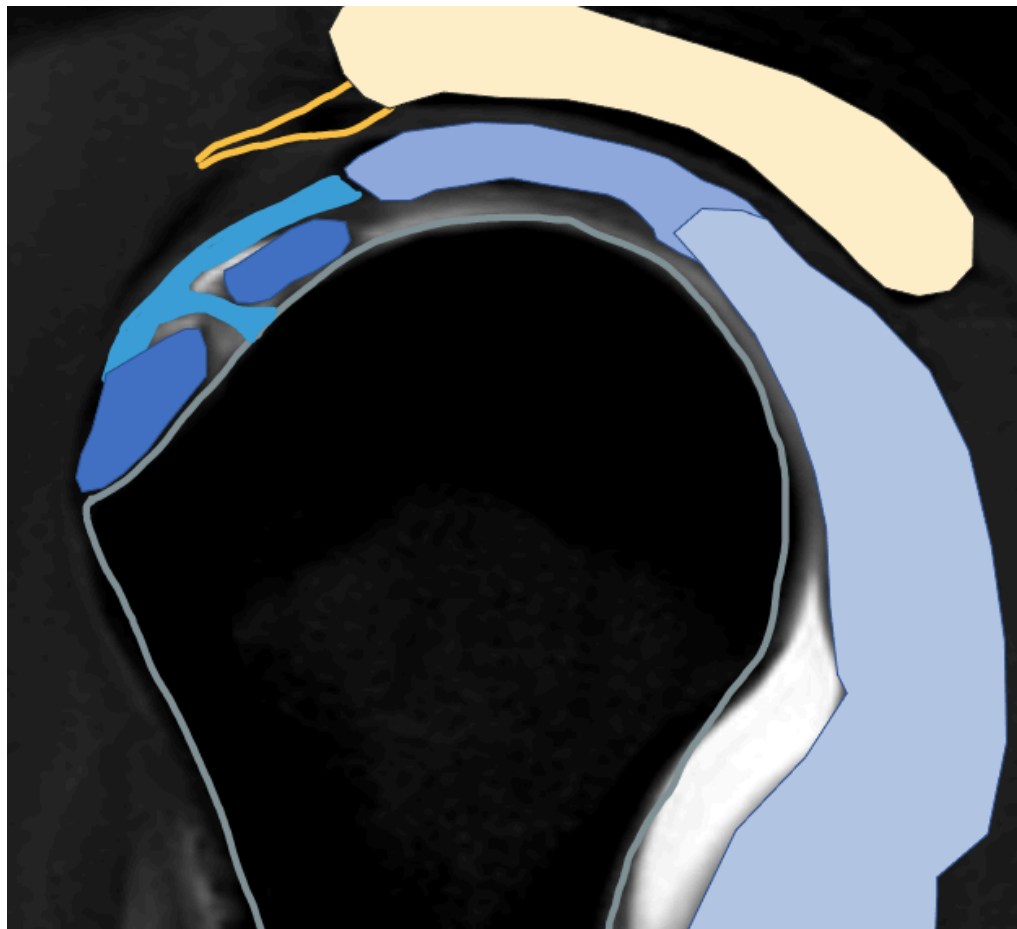
P.S.




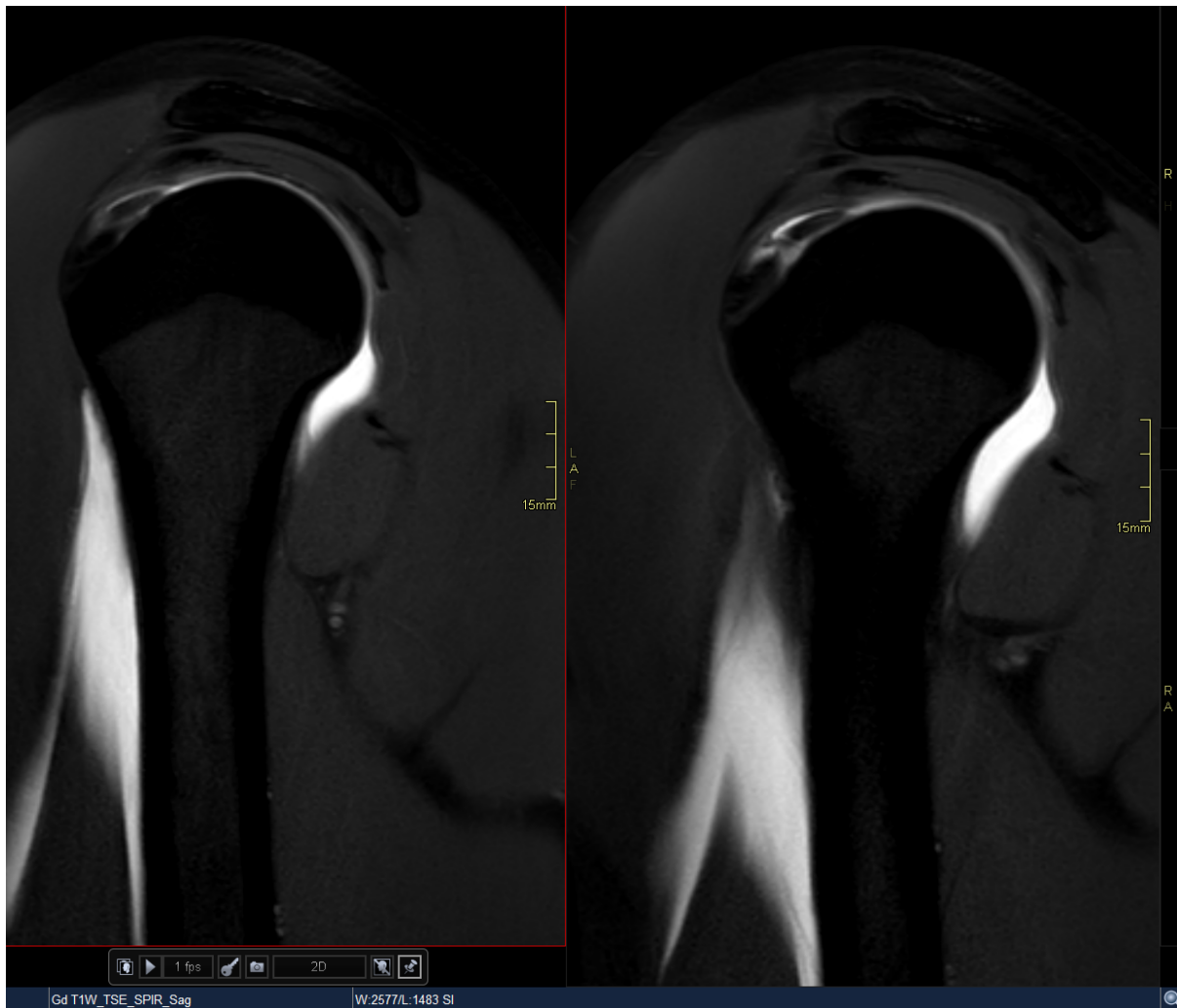


P.S.

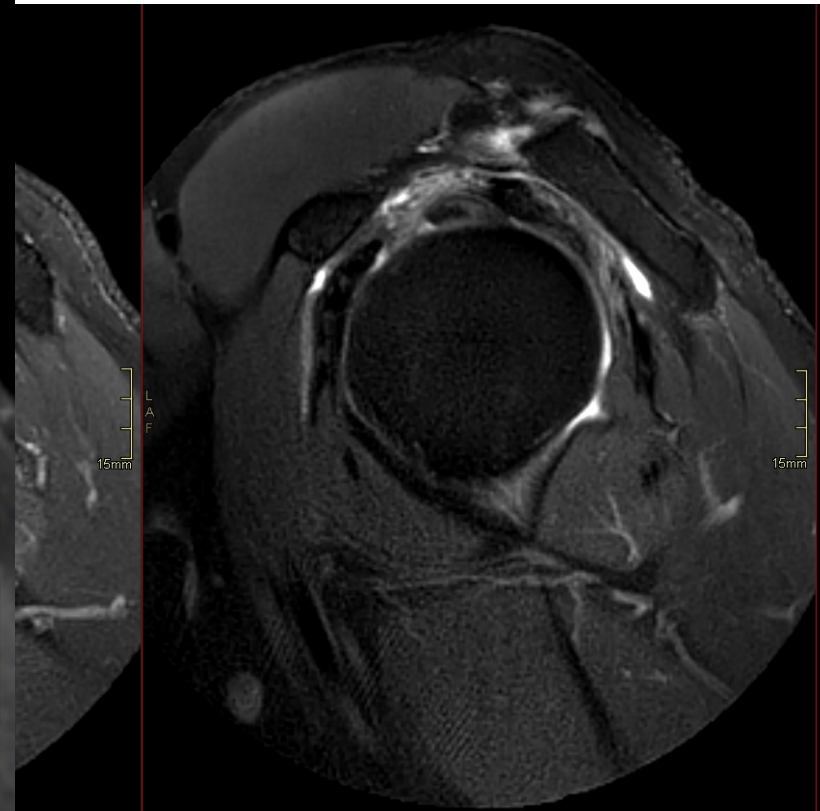
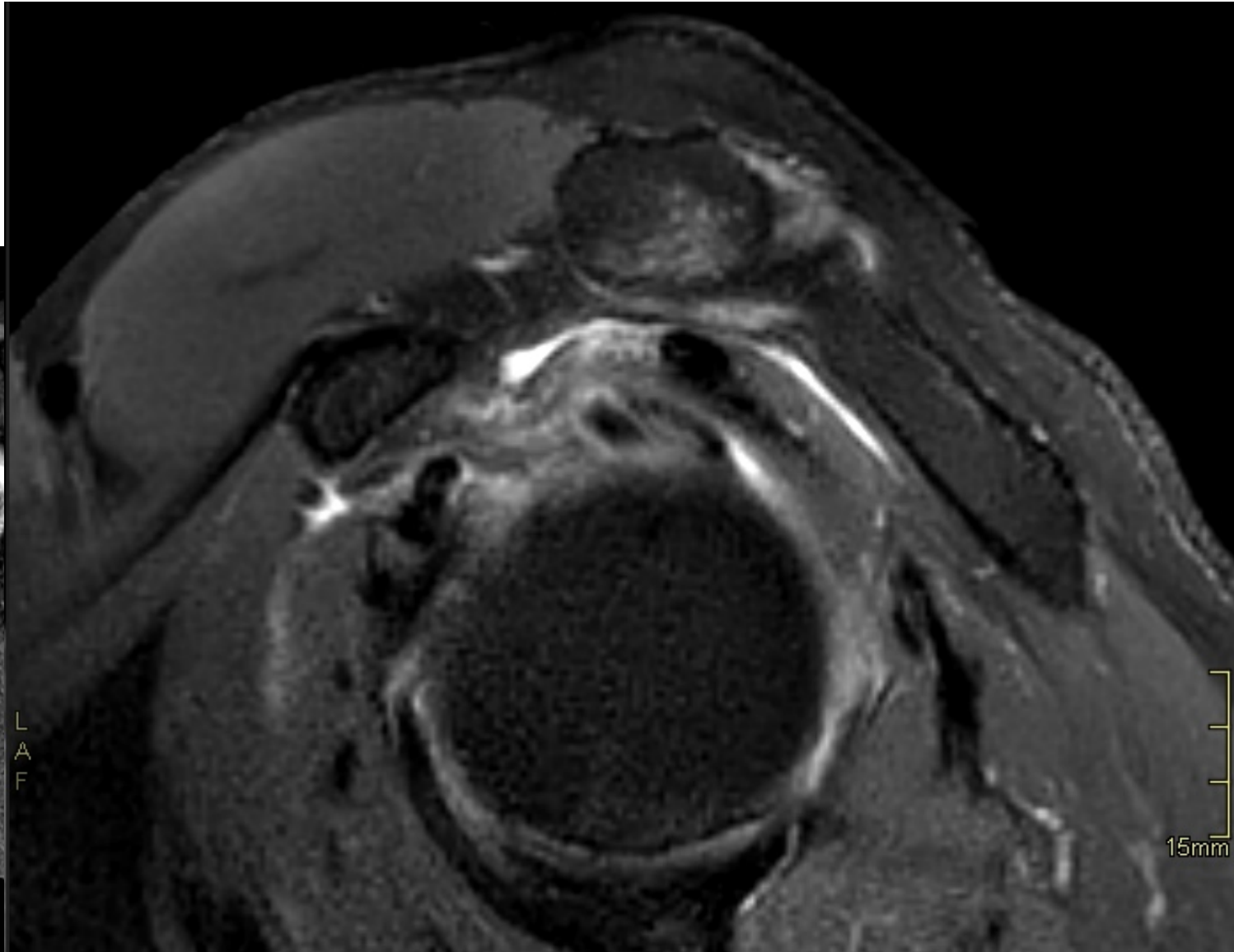
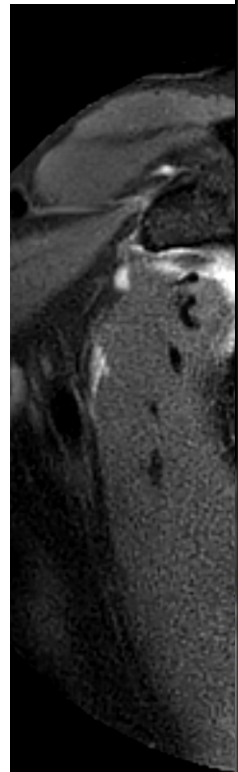
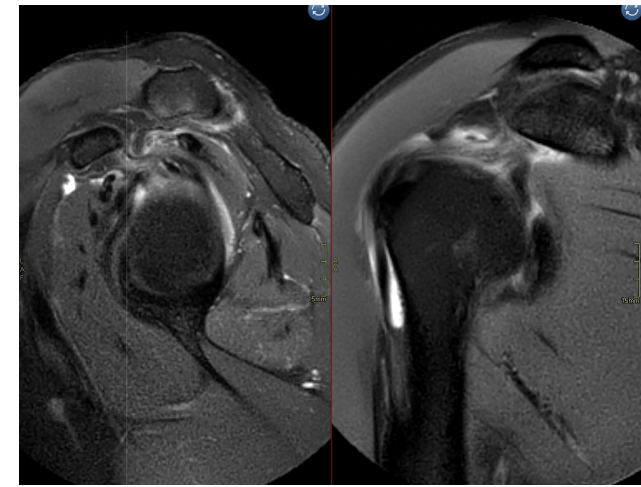
# Rotator interval



# Rotator interval

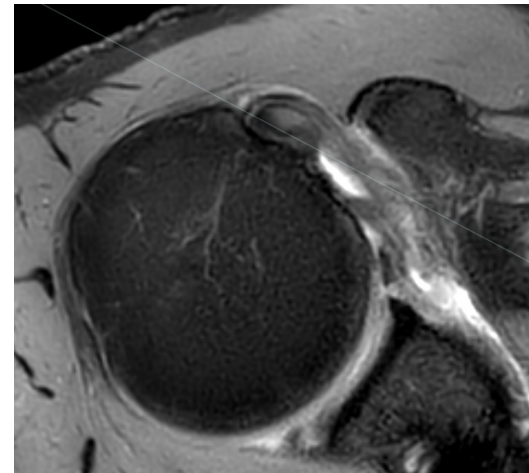
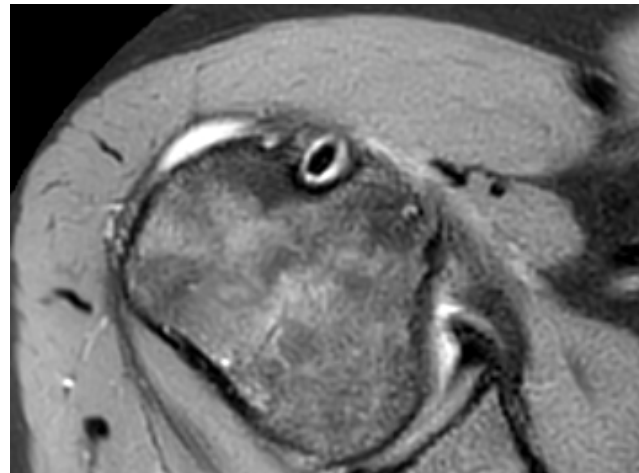
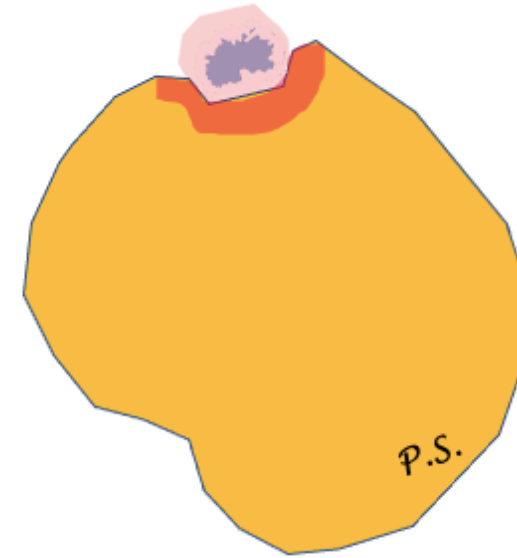
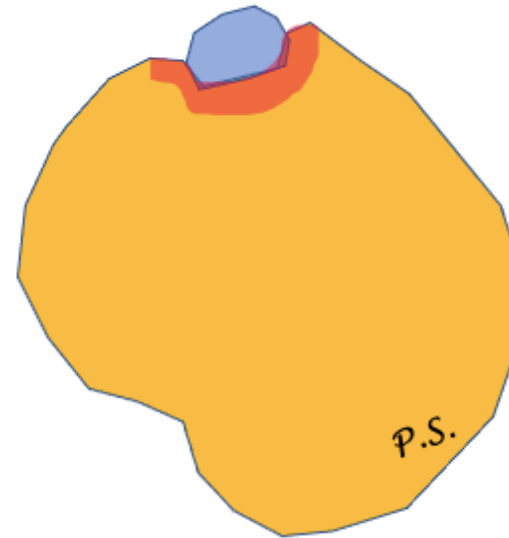
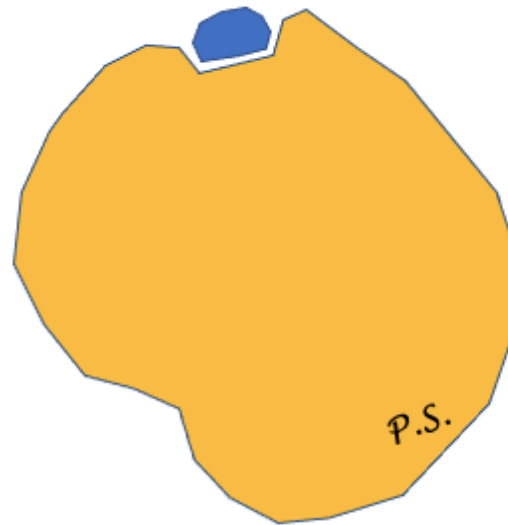


CHL



# Long head of biceps

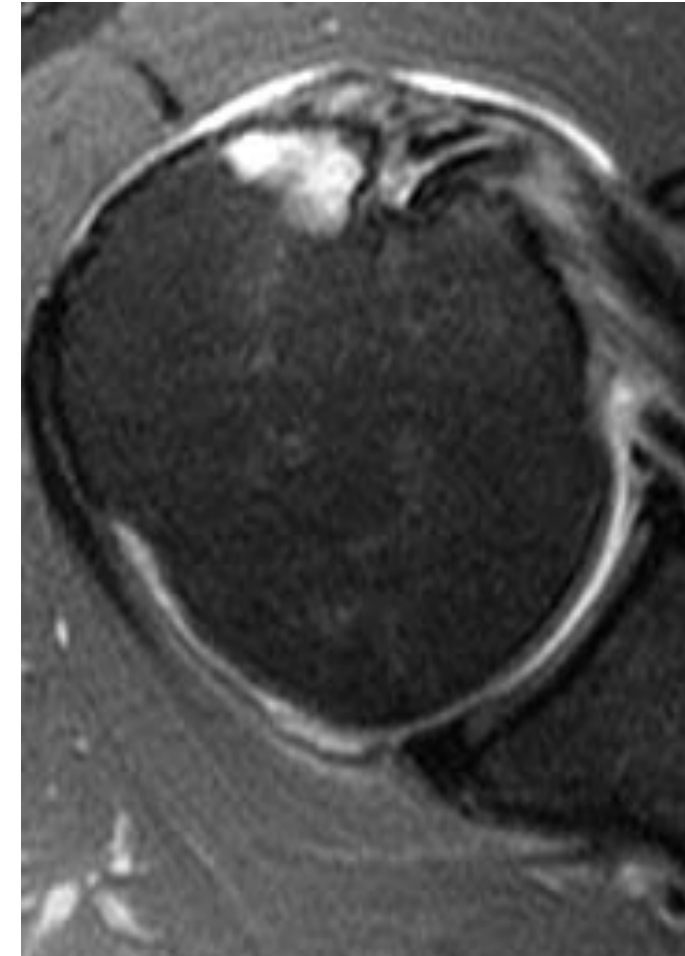
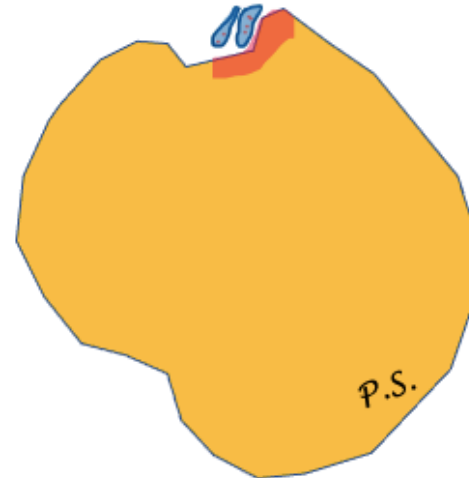
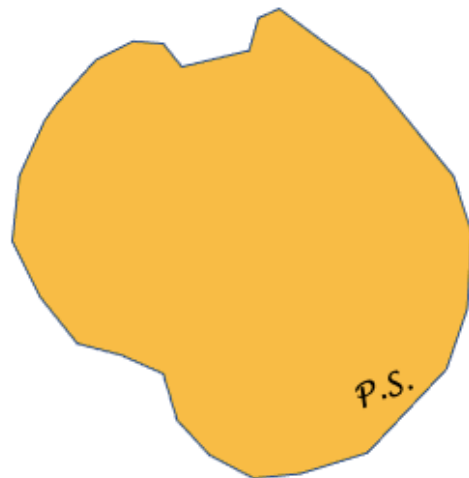
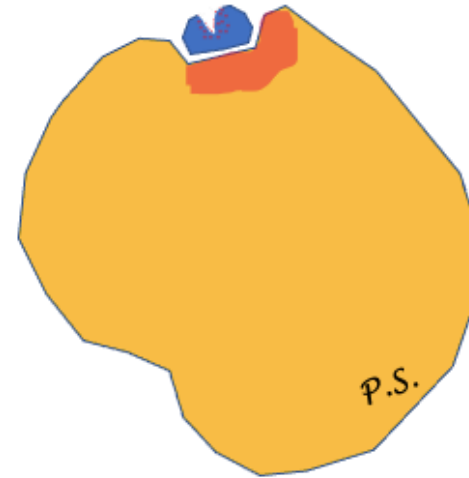
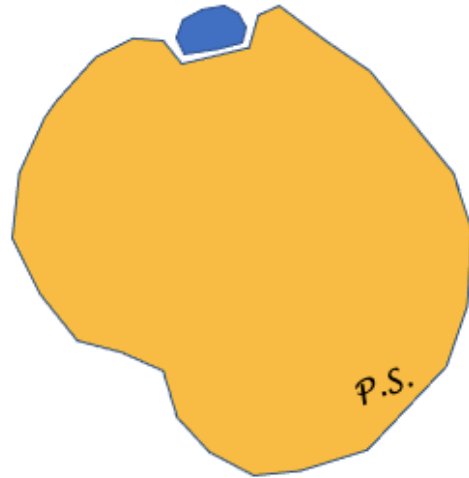
- Tendinopathy
  - Thickening
  - Thinning
- Discontinuity
- absence
- Instability





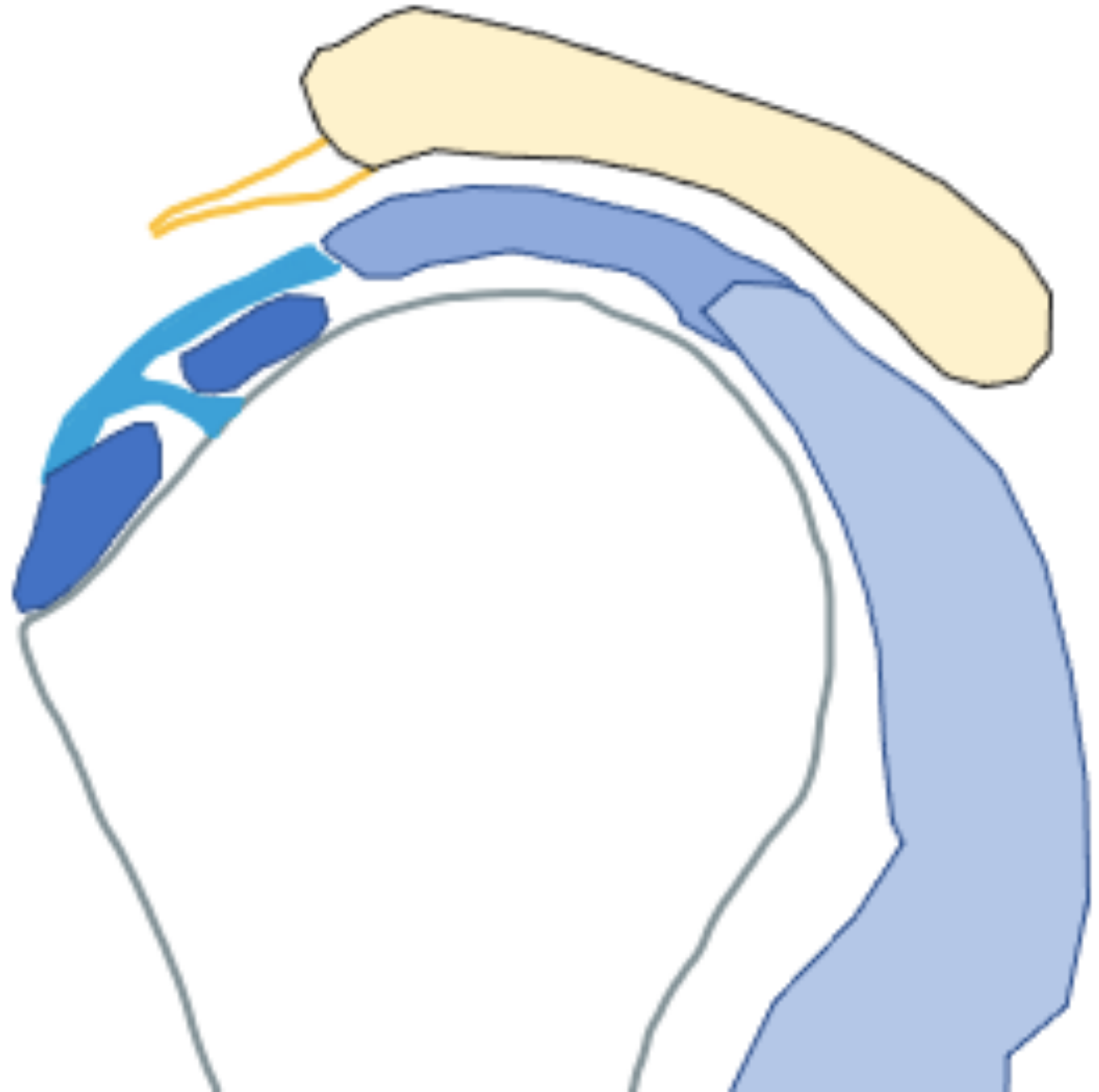
# Long head of biceps

- Tendinopathy
  - Thickening
  - Thinning
- Discontinuity
- Split rupture
- Absence
- Instability



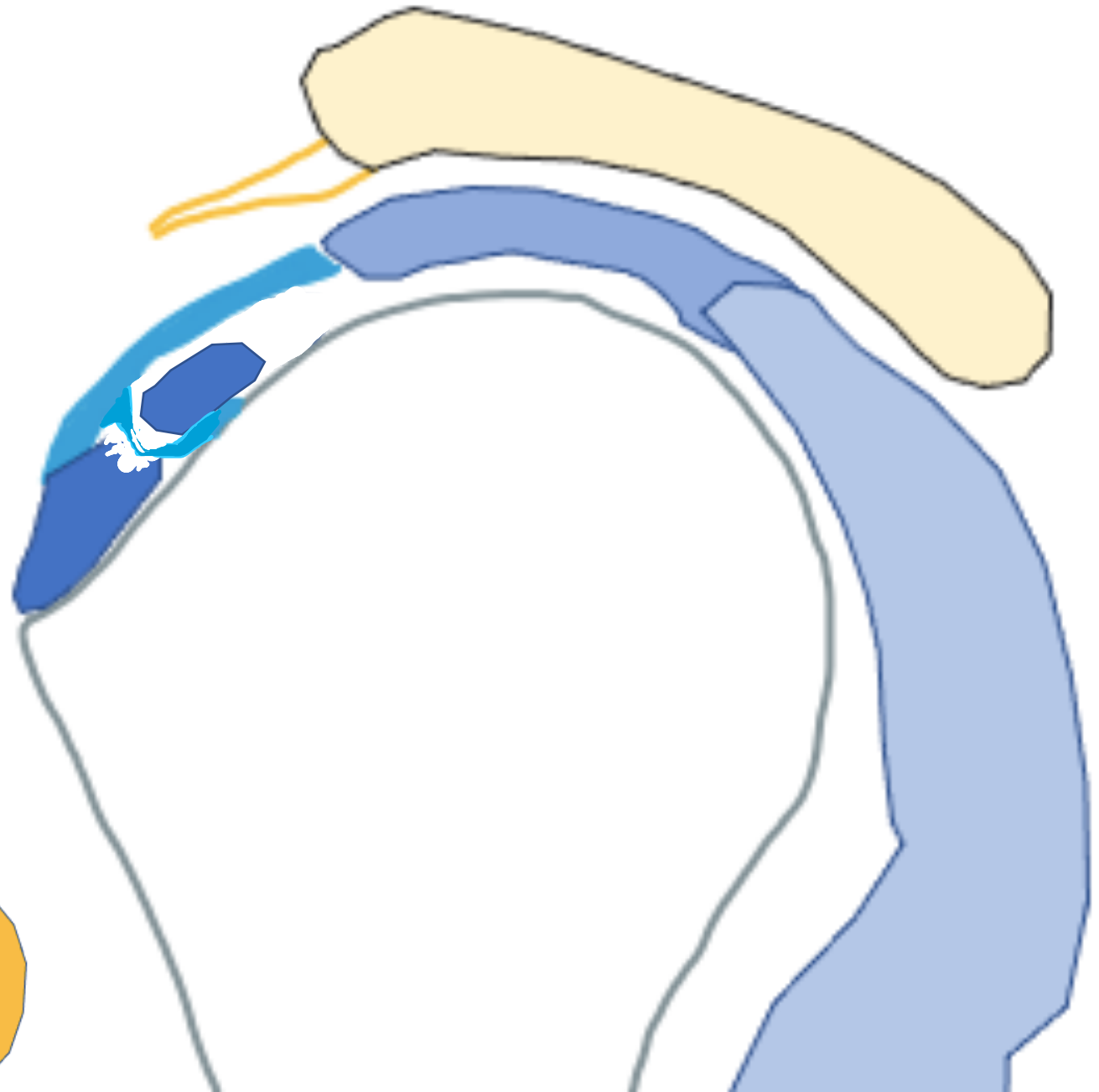
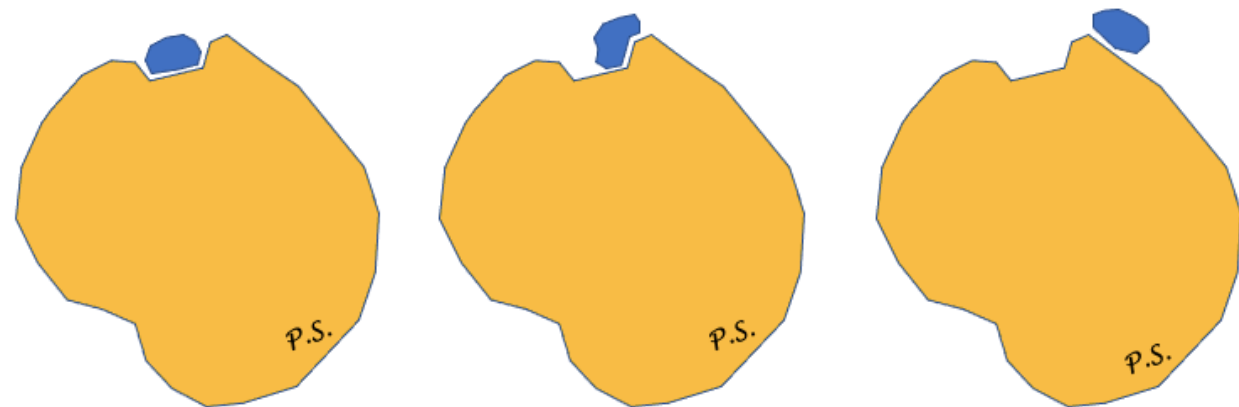
# Long head of biceps

- Tendinopathy
  - Thickening
  - Thinning
- Discontinuity
- absence
- Instability

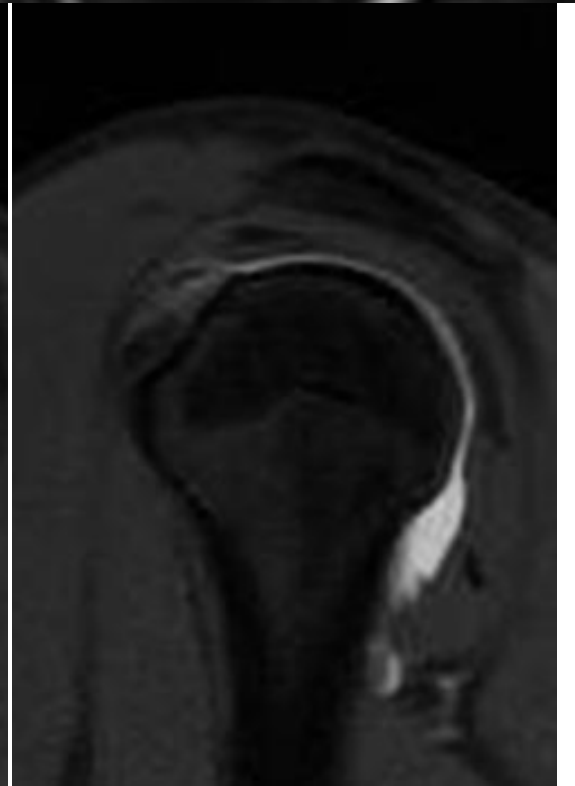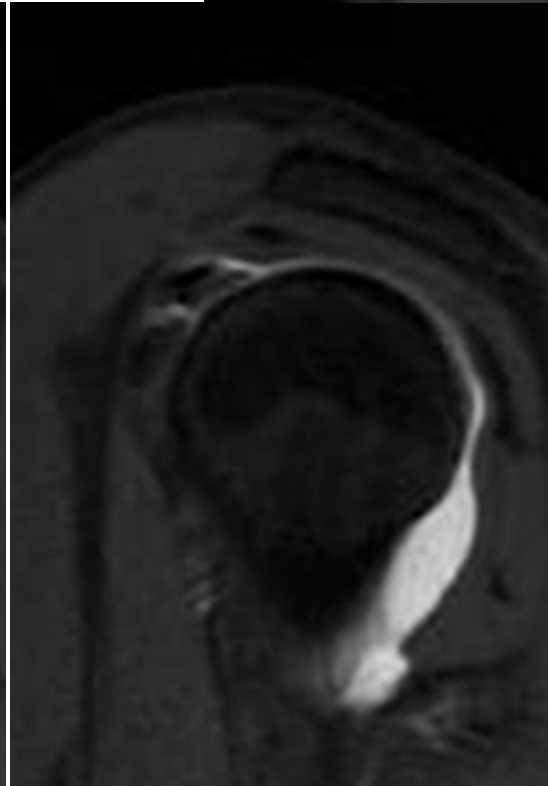
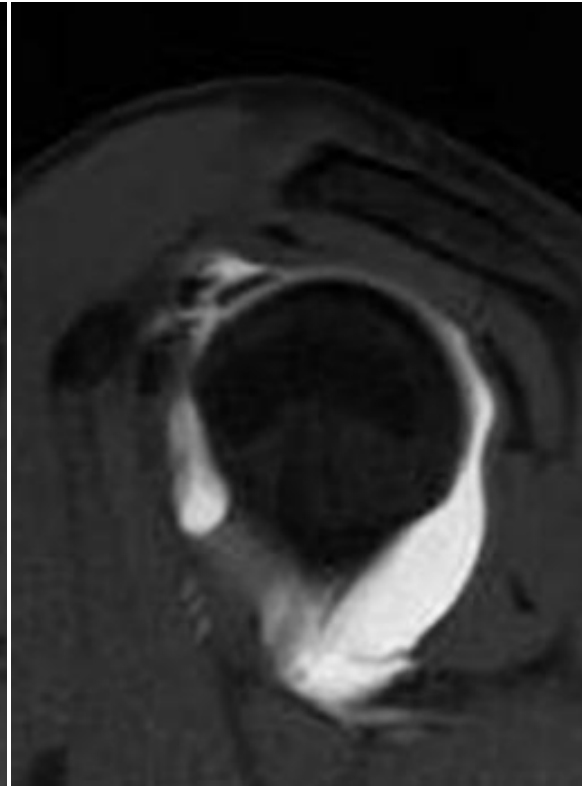
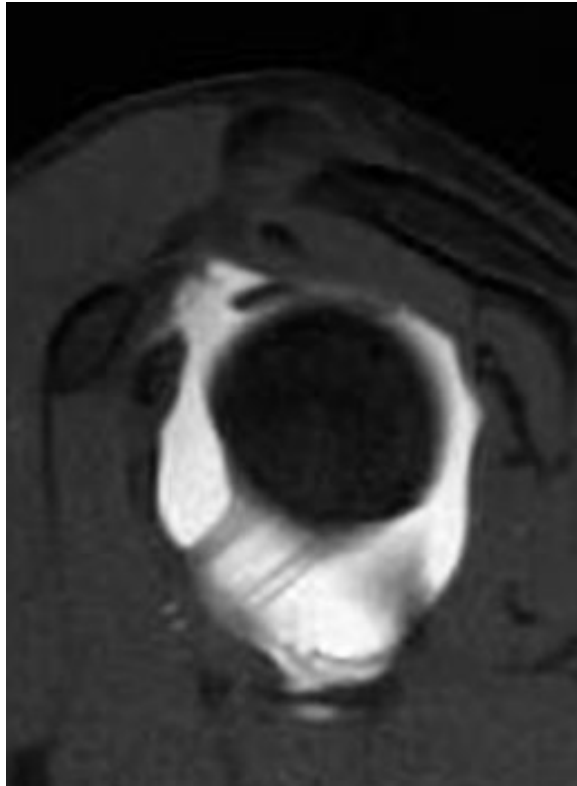
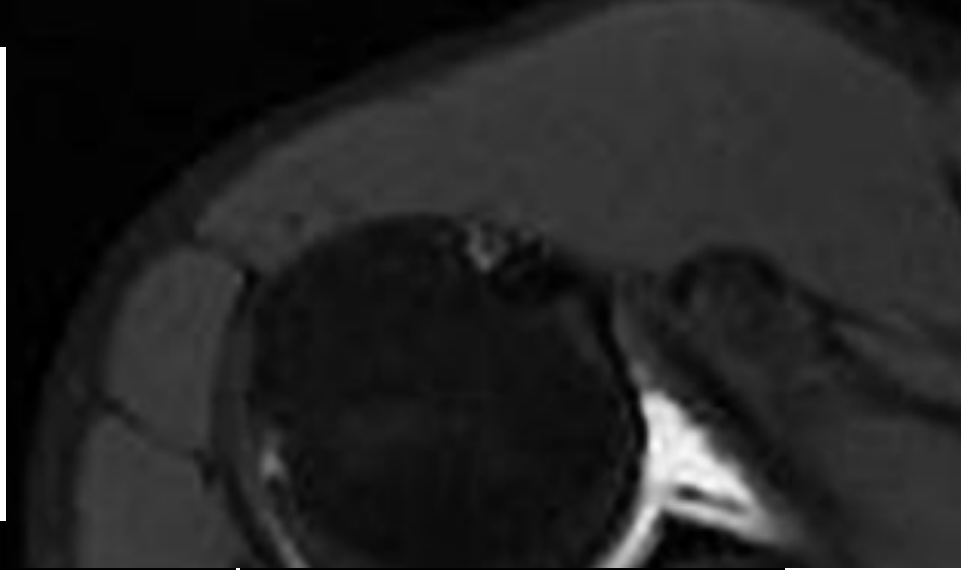

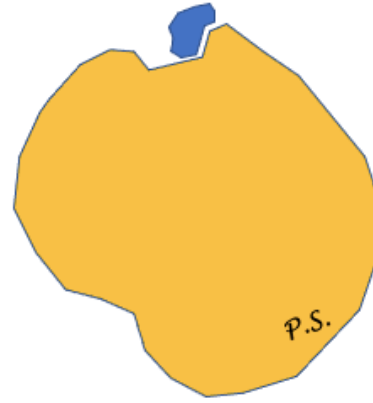
# Long head of biceps

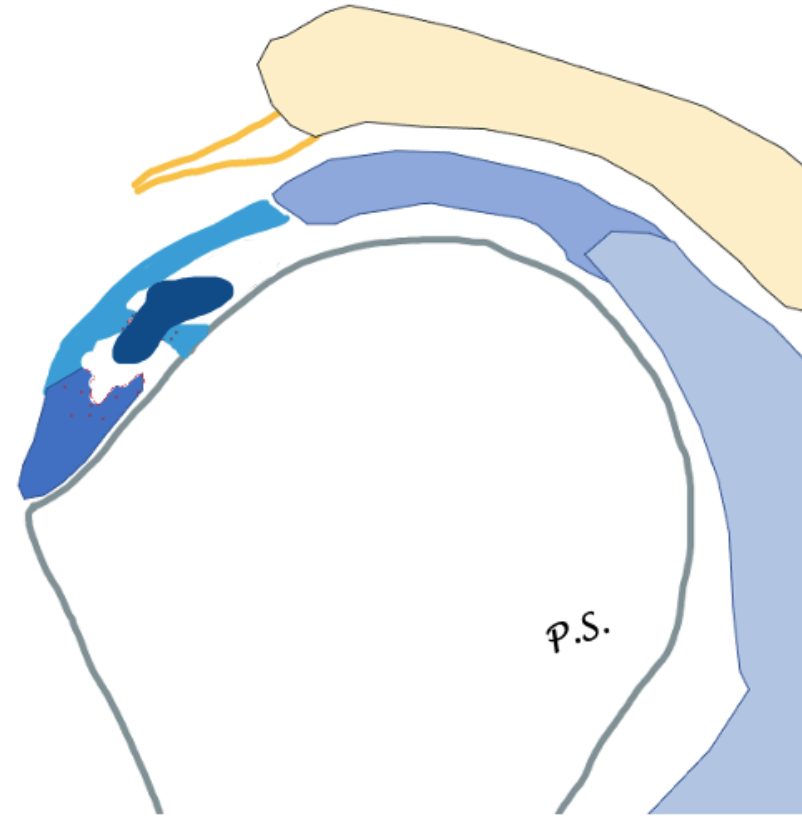
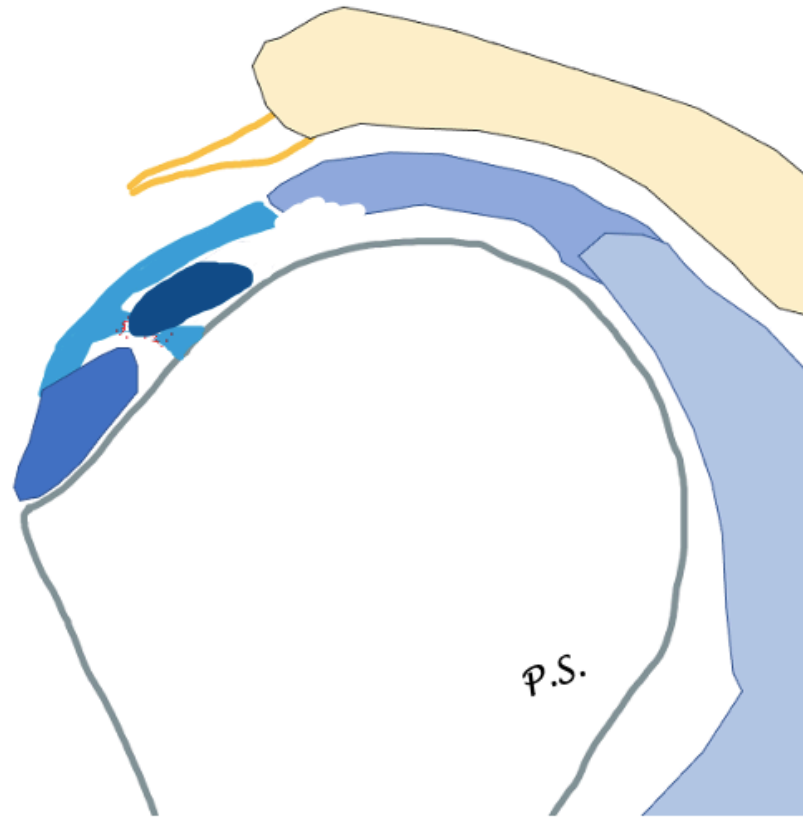
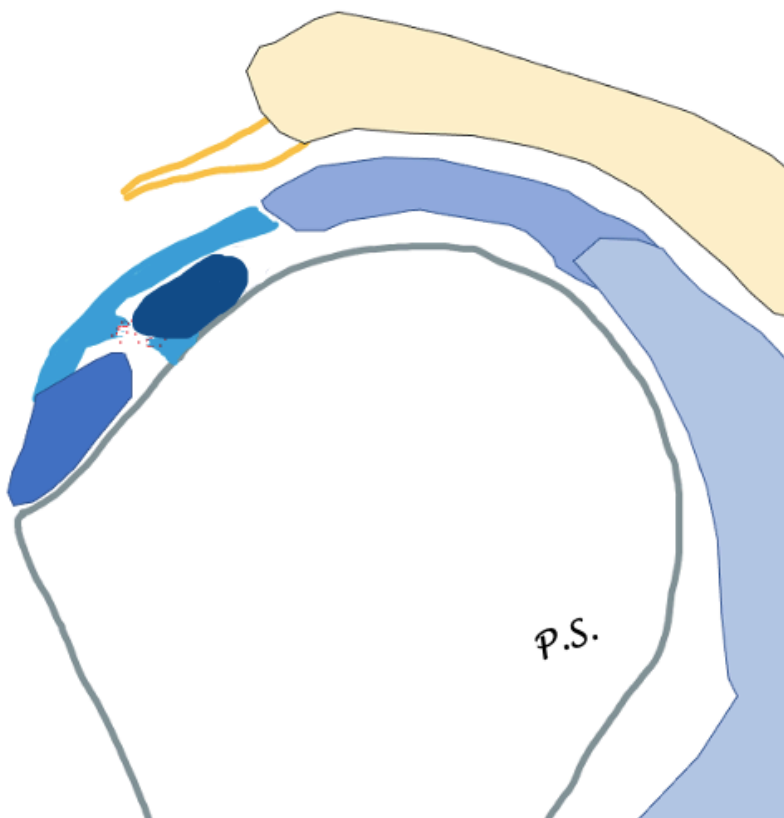
- Tendinopathy
  - Thickening
  - Thinning
- Discontinuity
- Split rupture
- Absence
- Instability



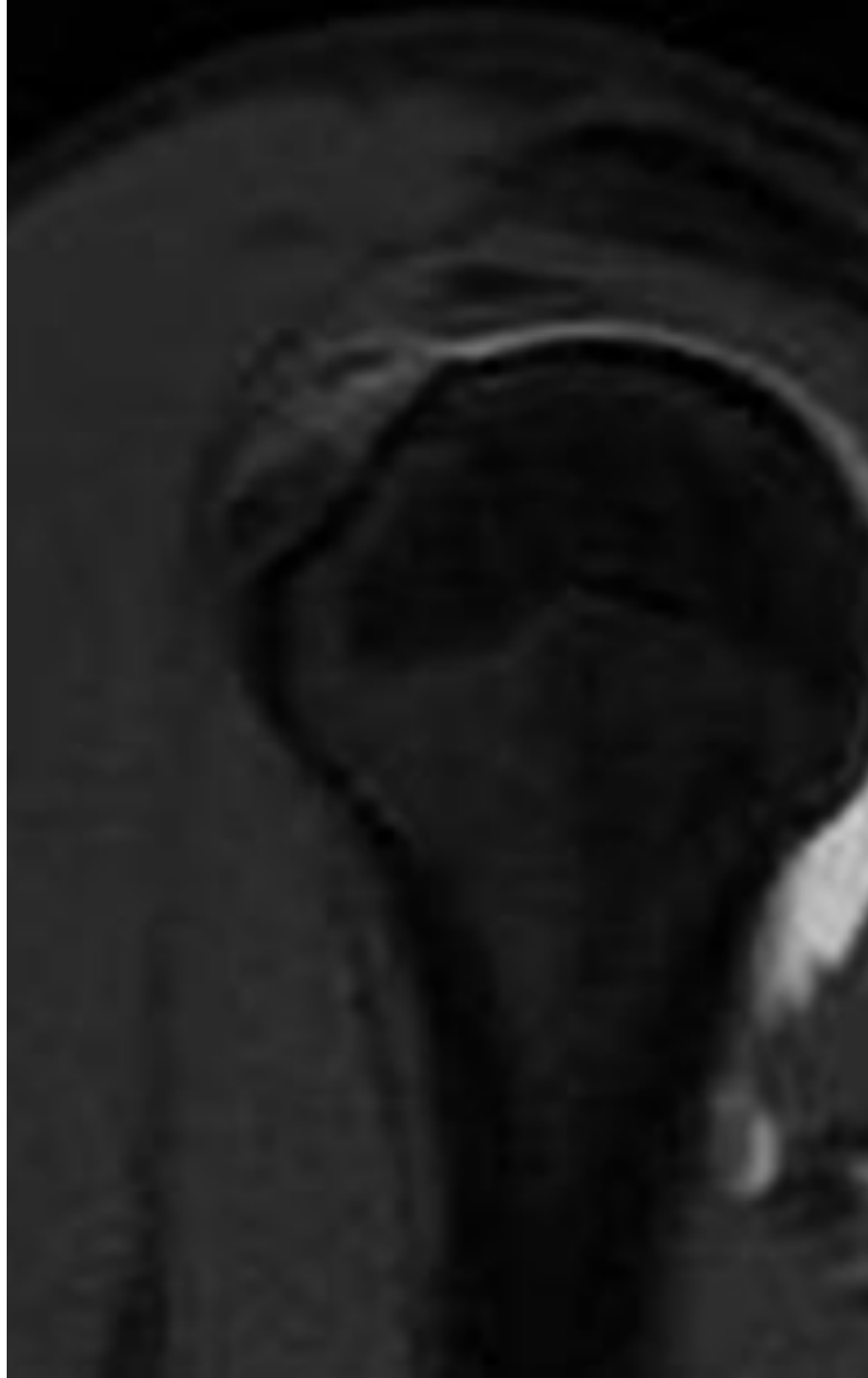
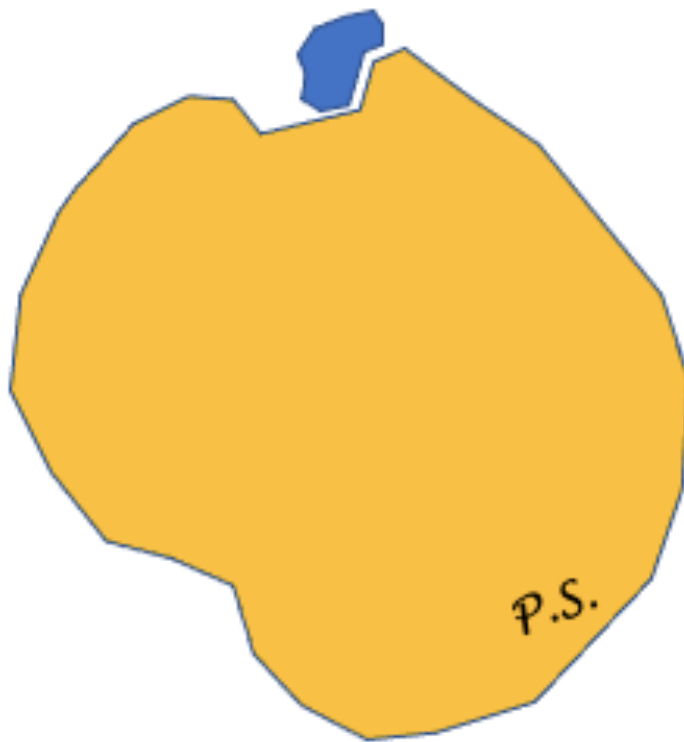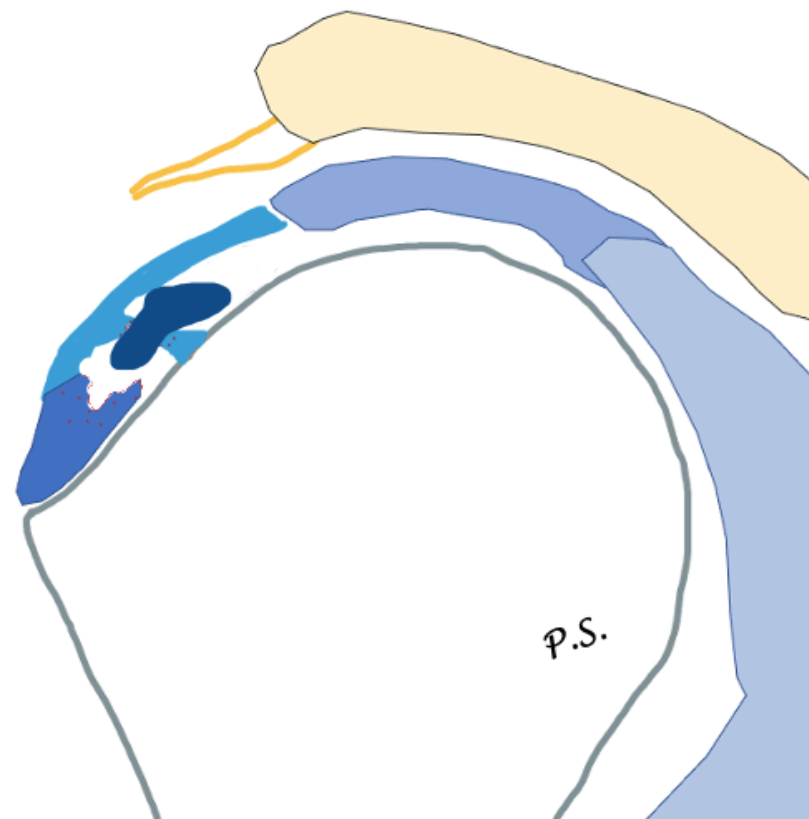
# Biceps pulley lesion



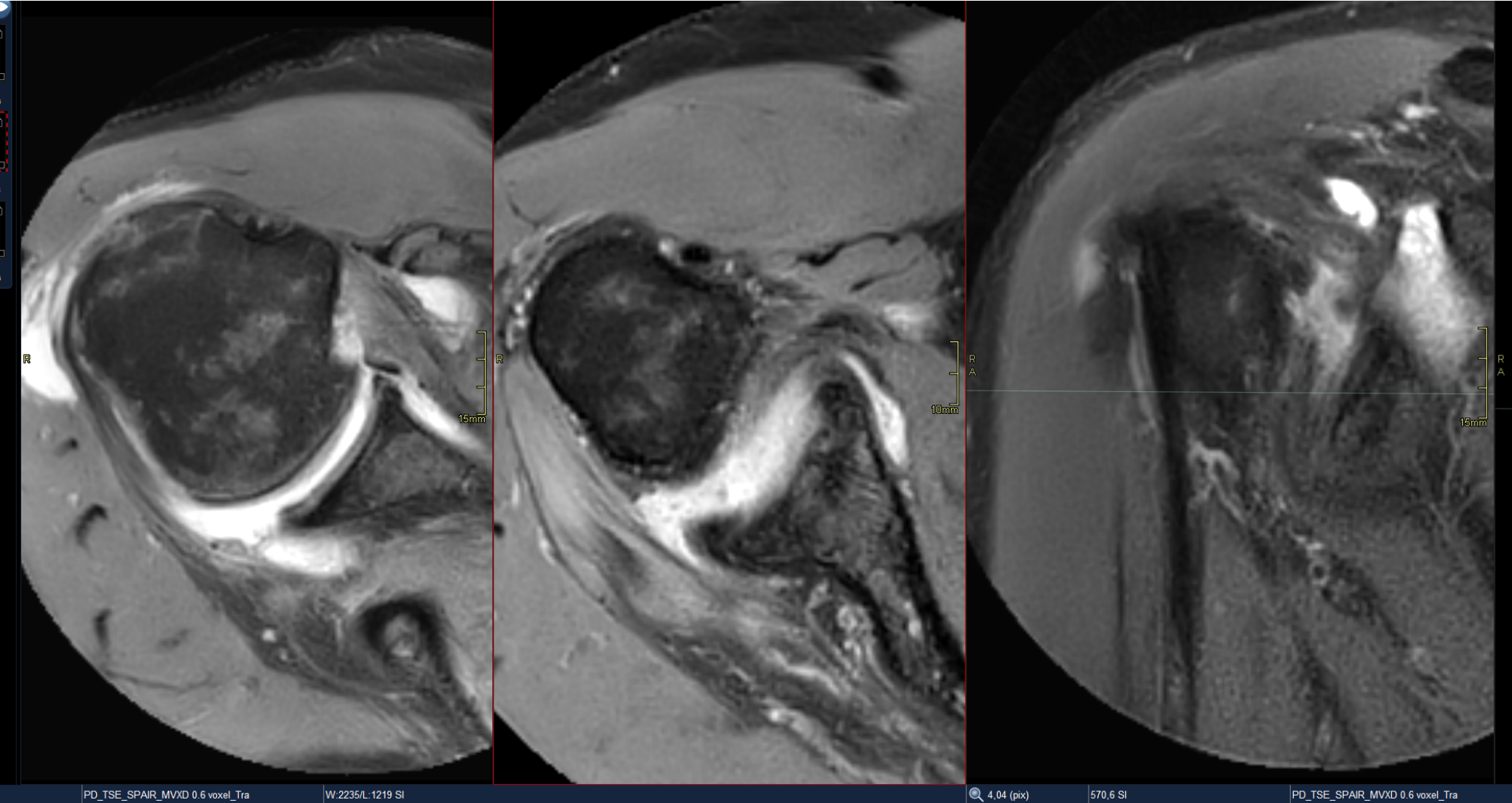
# Biceps pulley lesion (grading)



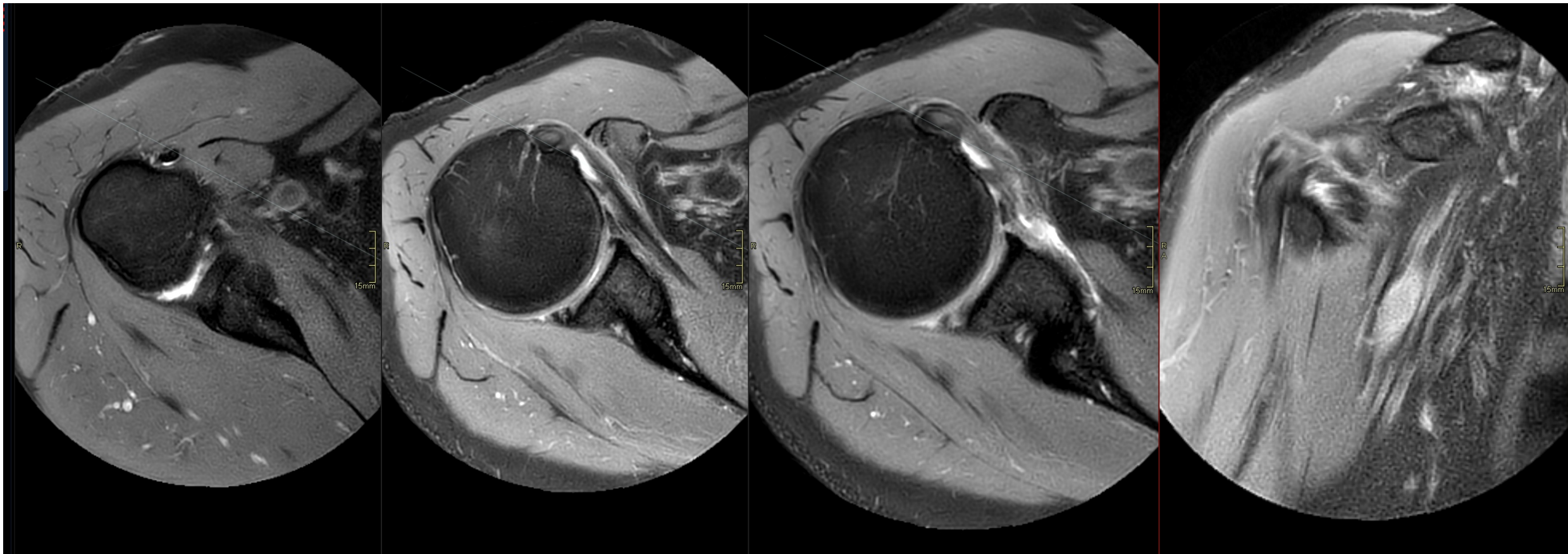
# Biceps pulley lesion (grading)



# LHB

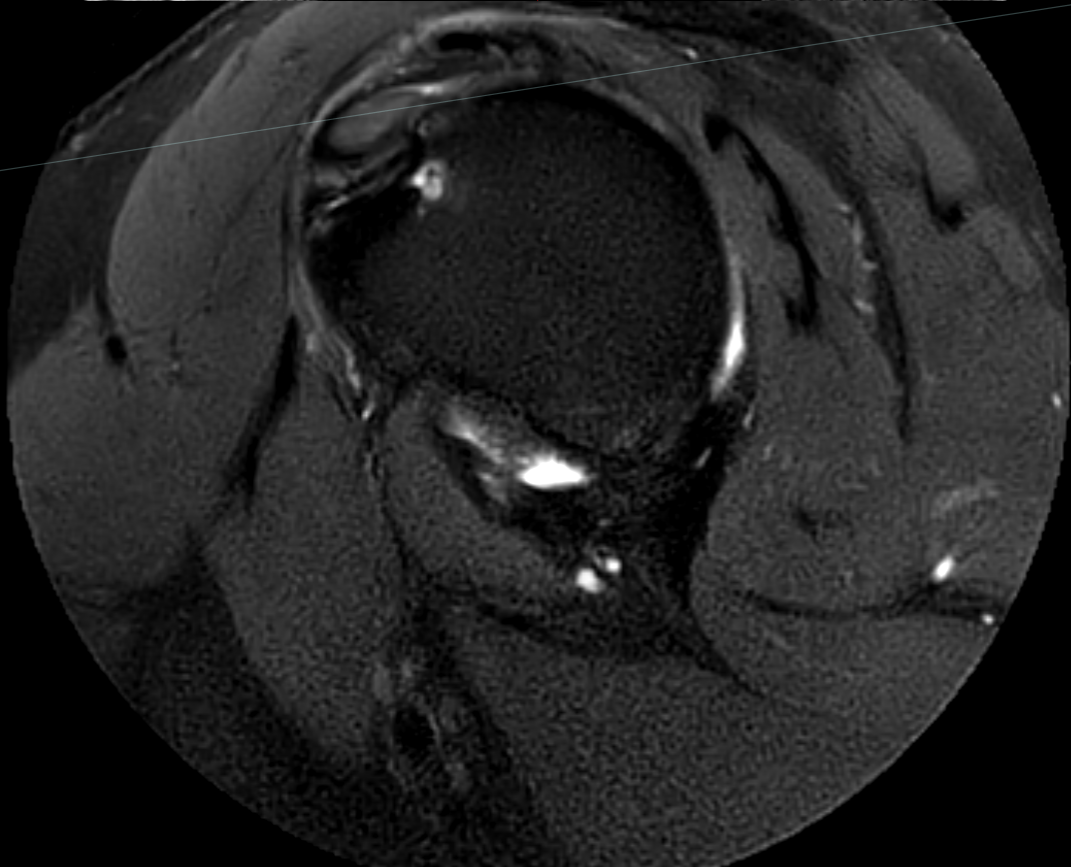
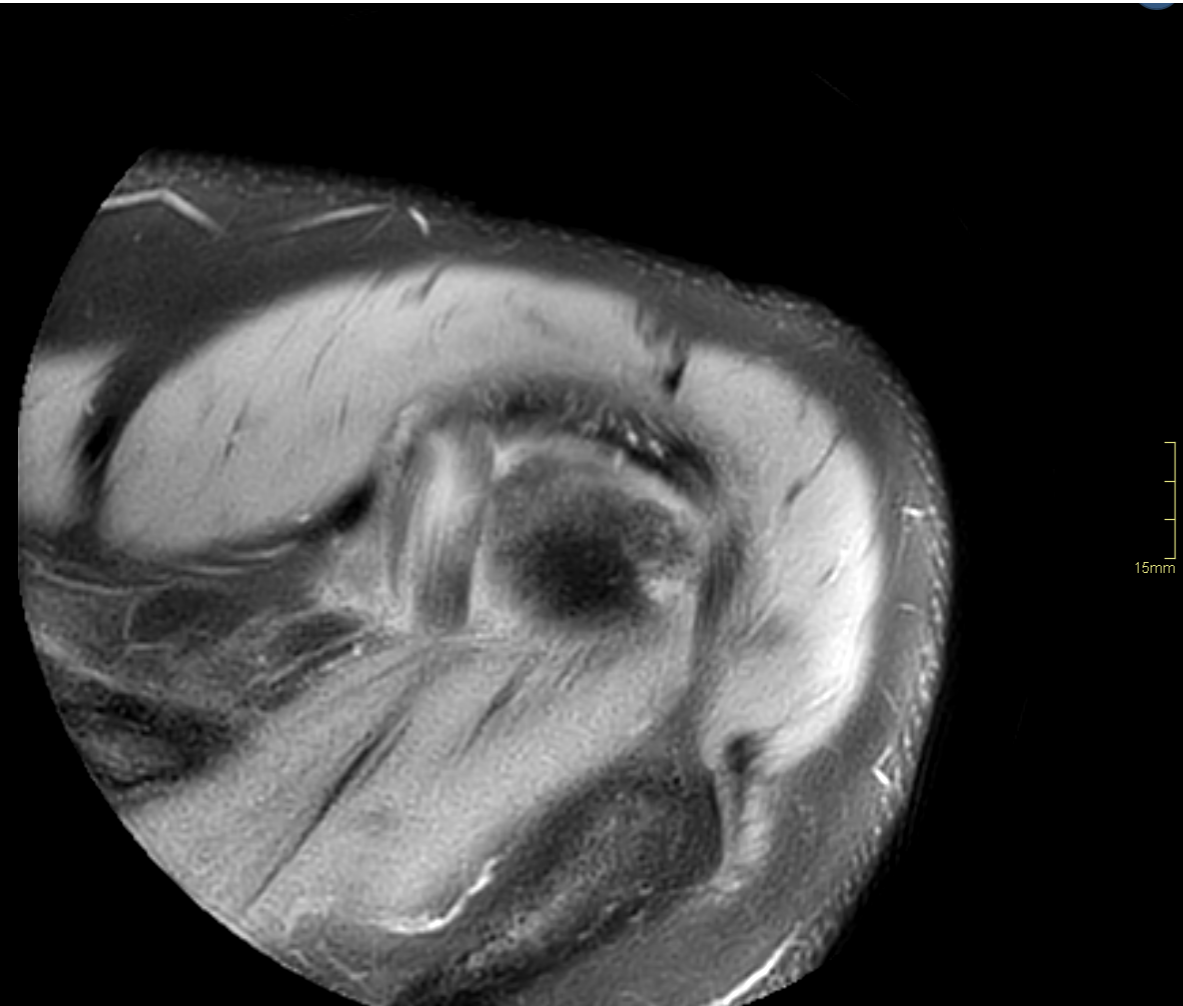
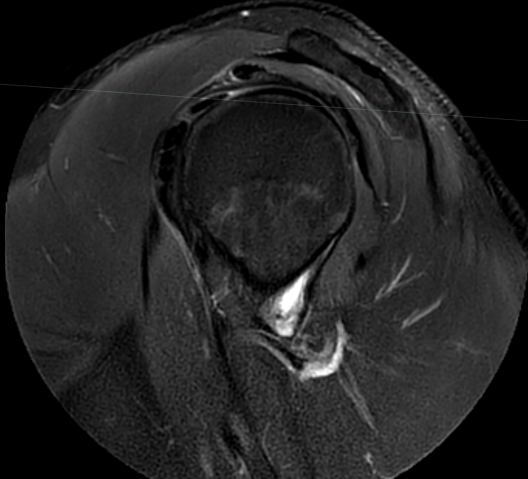
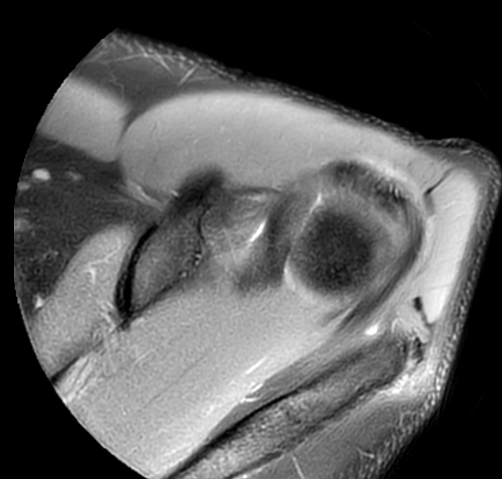


# LHB

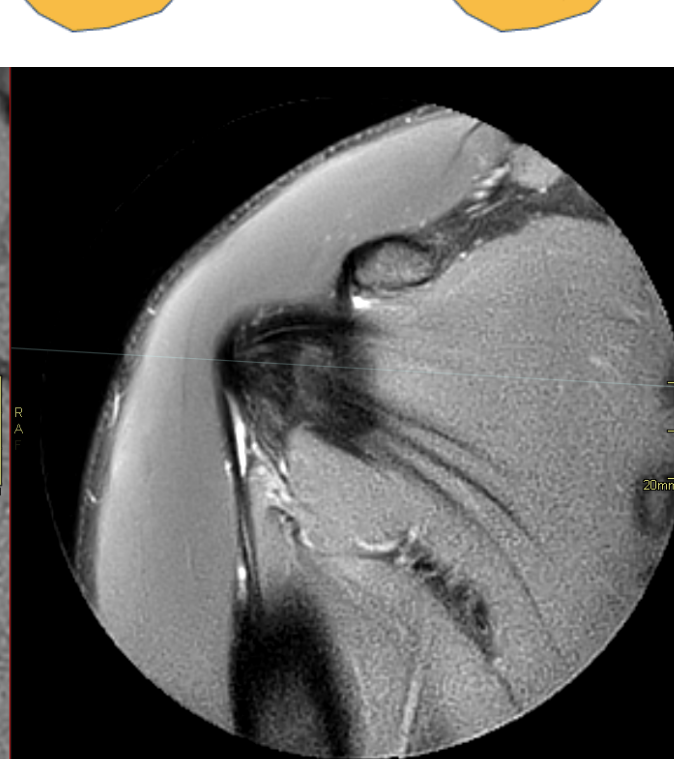
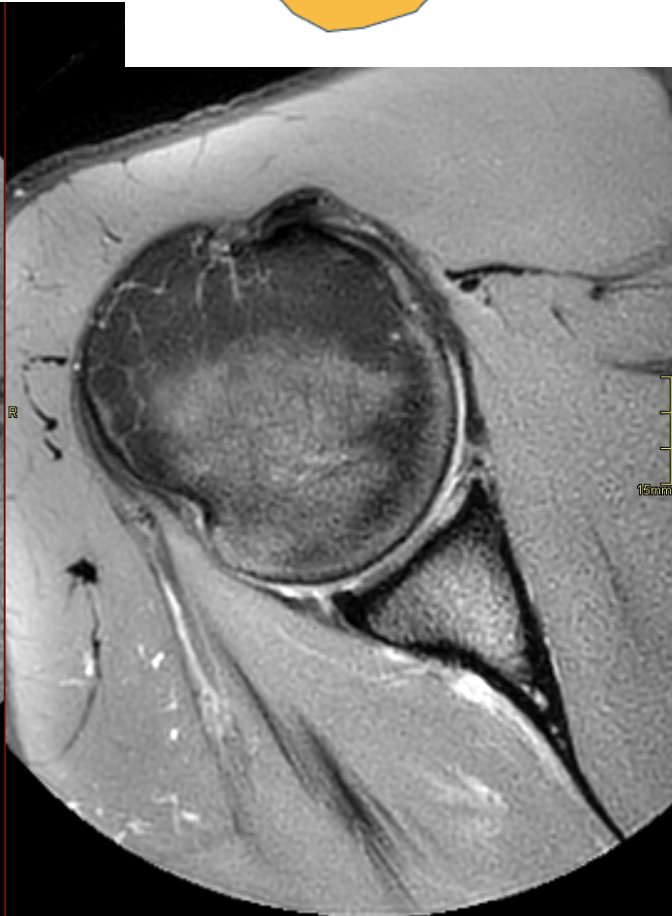
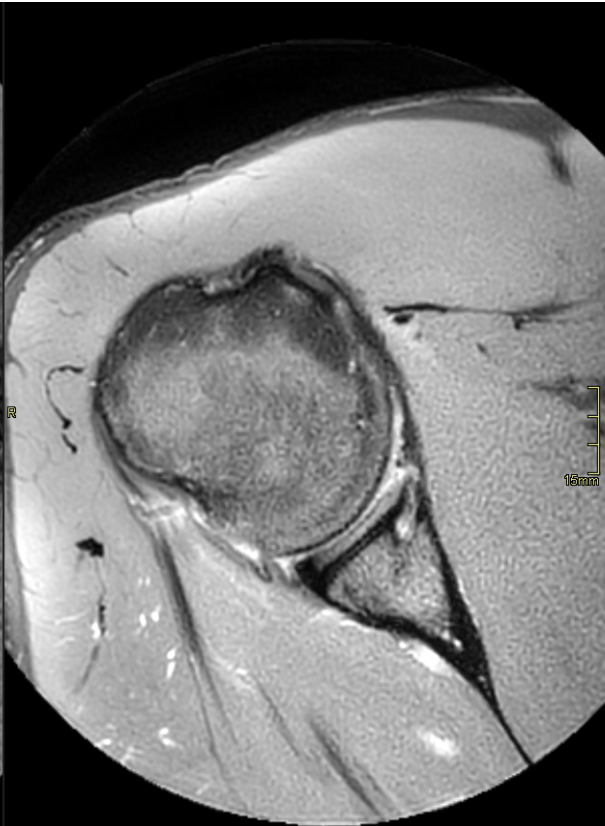
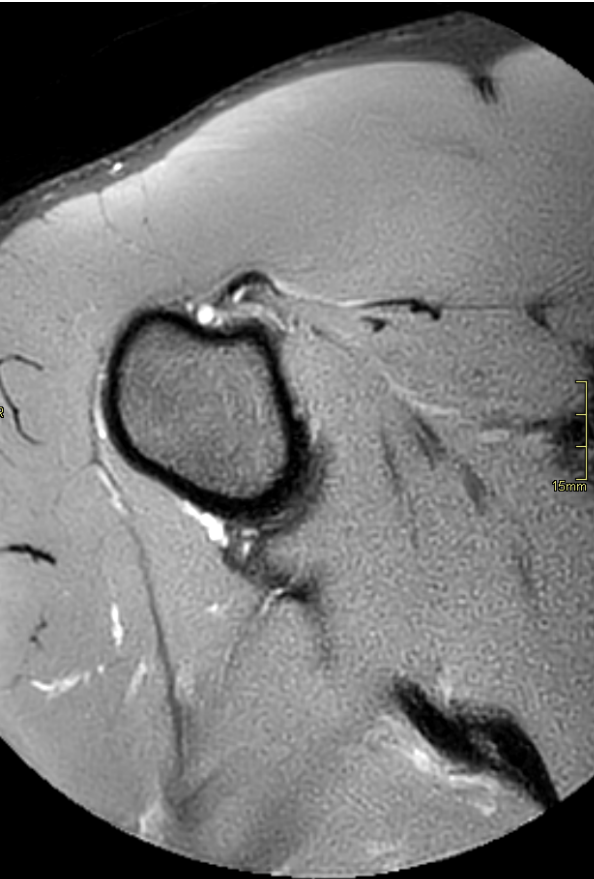
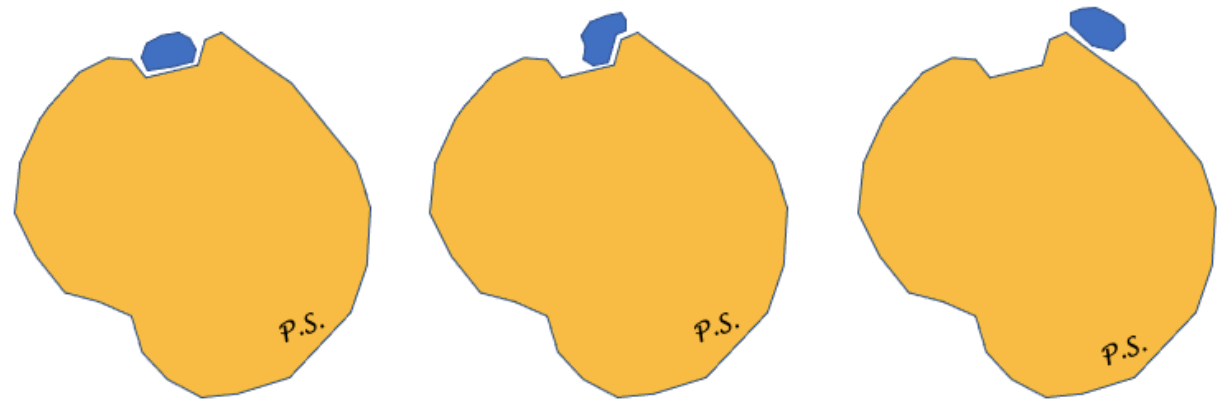




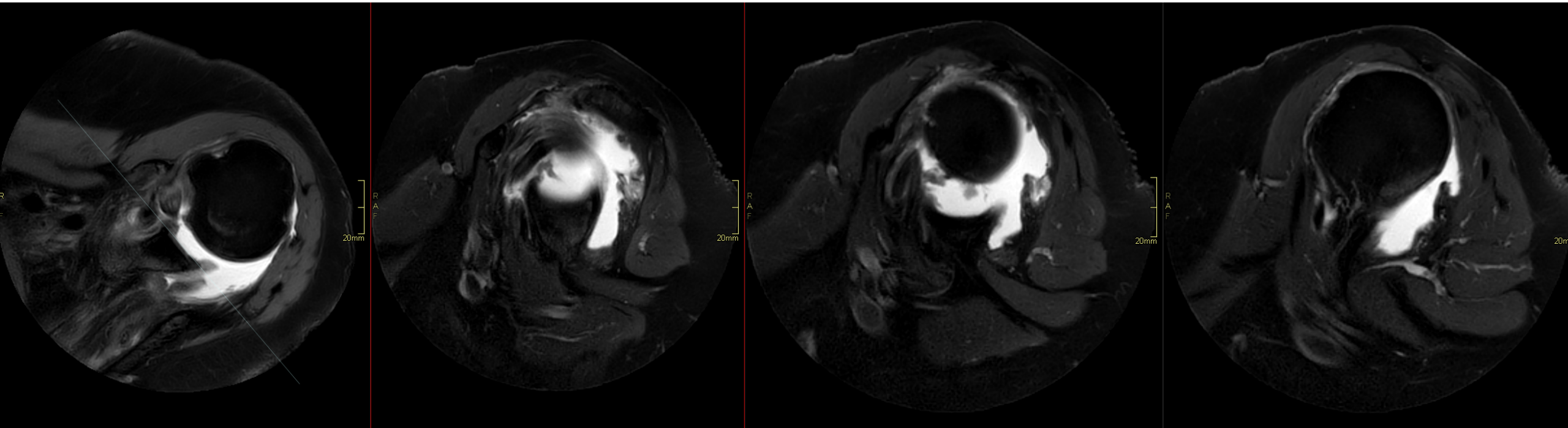
# Tendinopathy



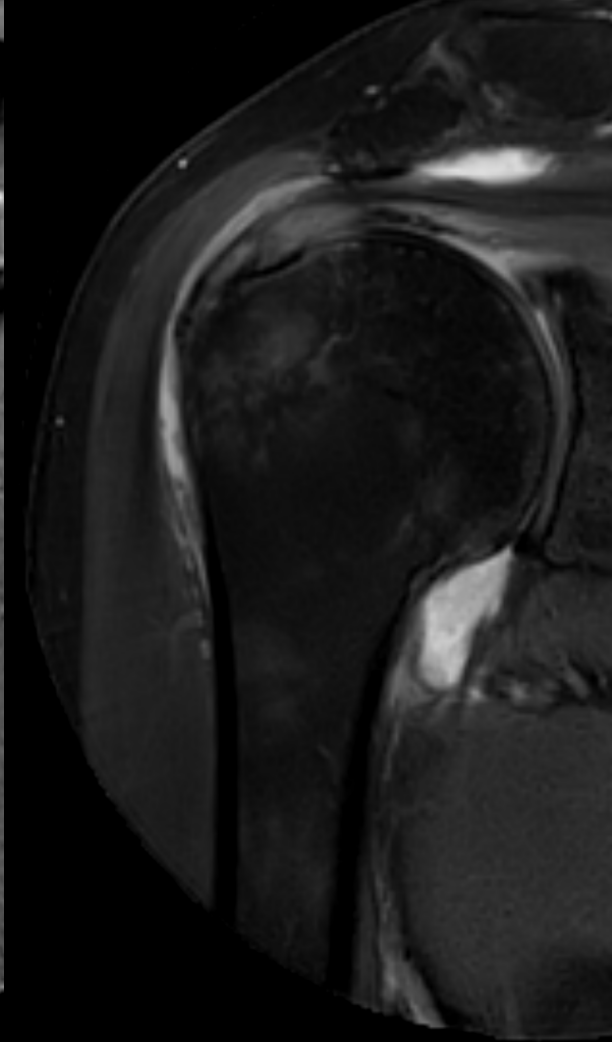
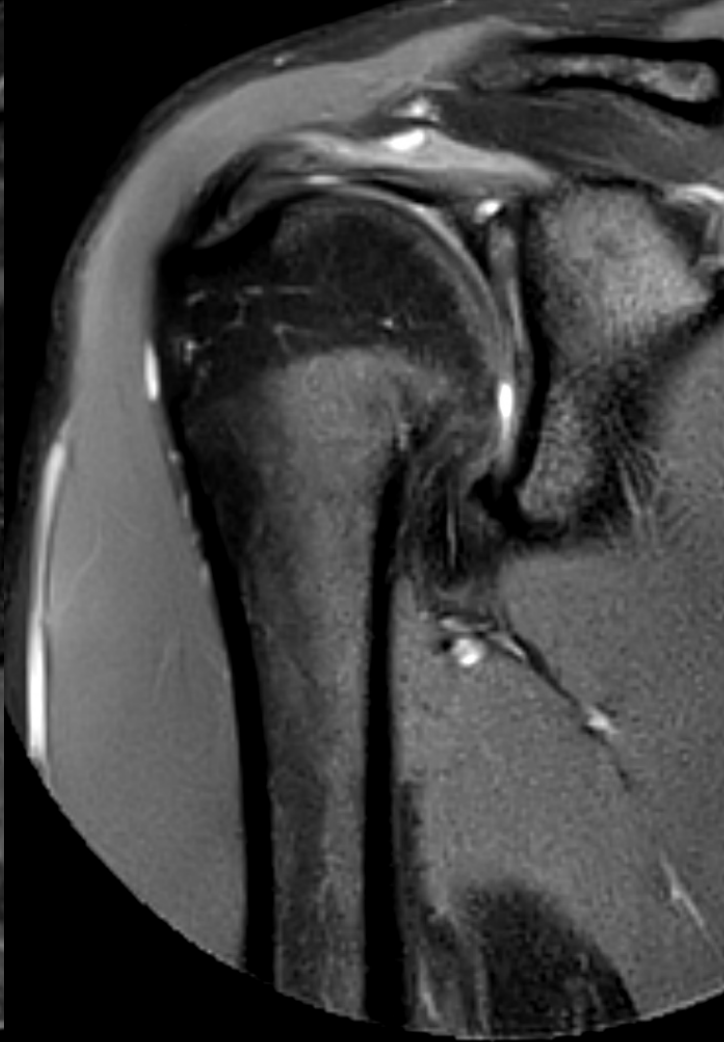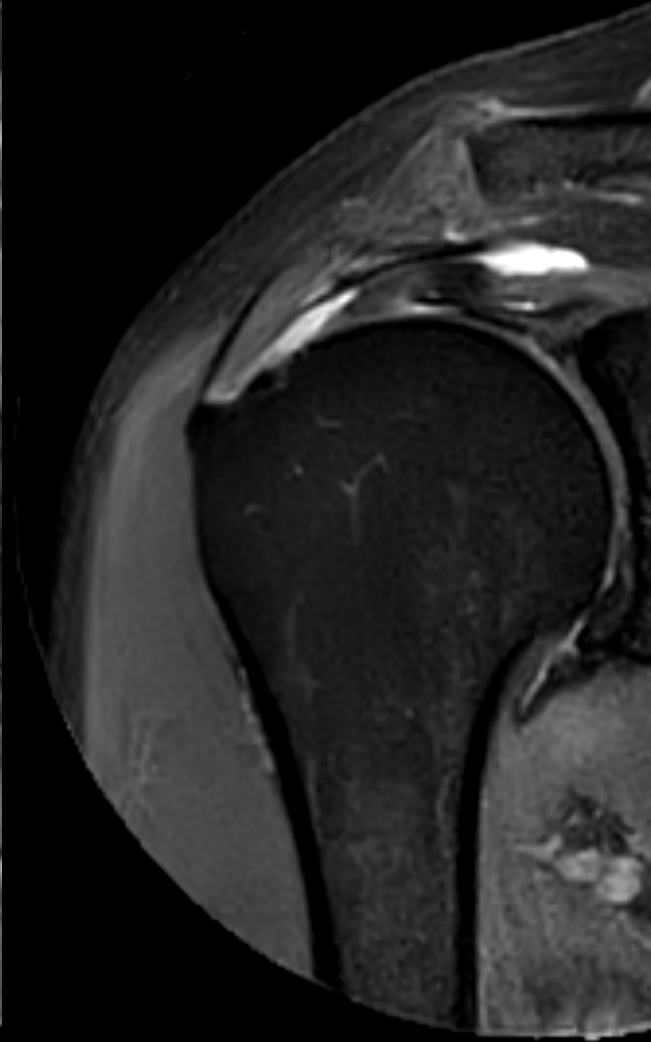
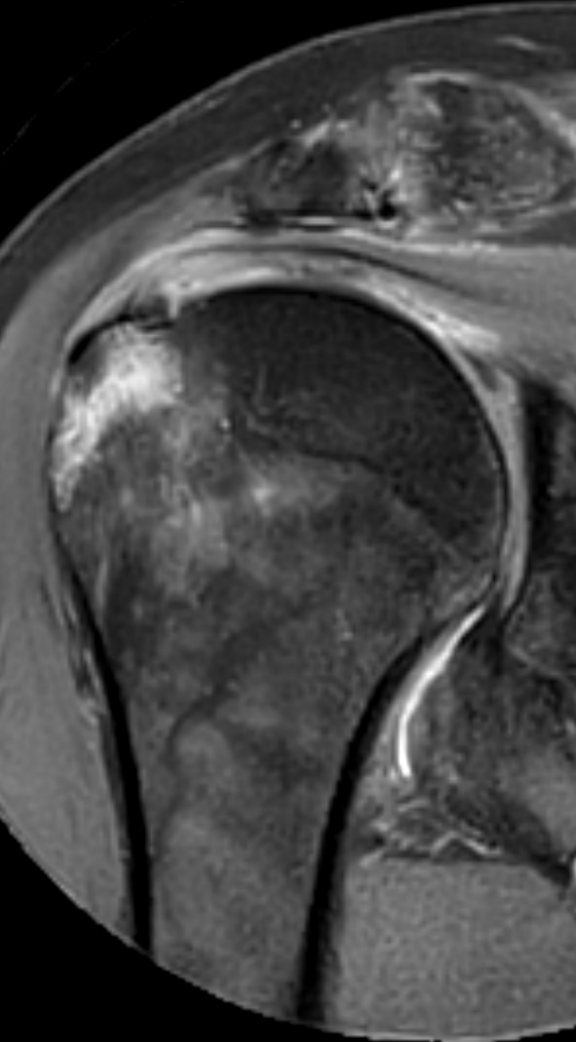
# LHB



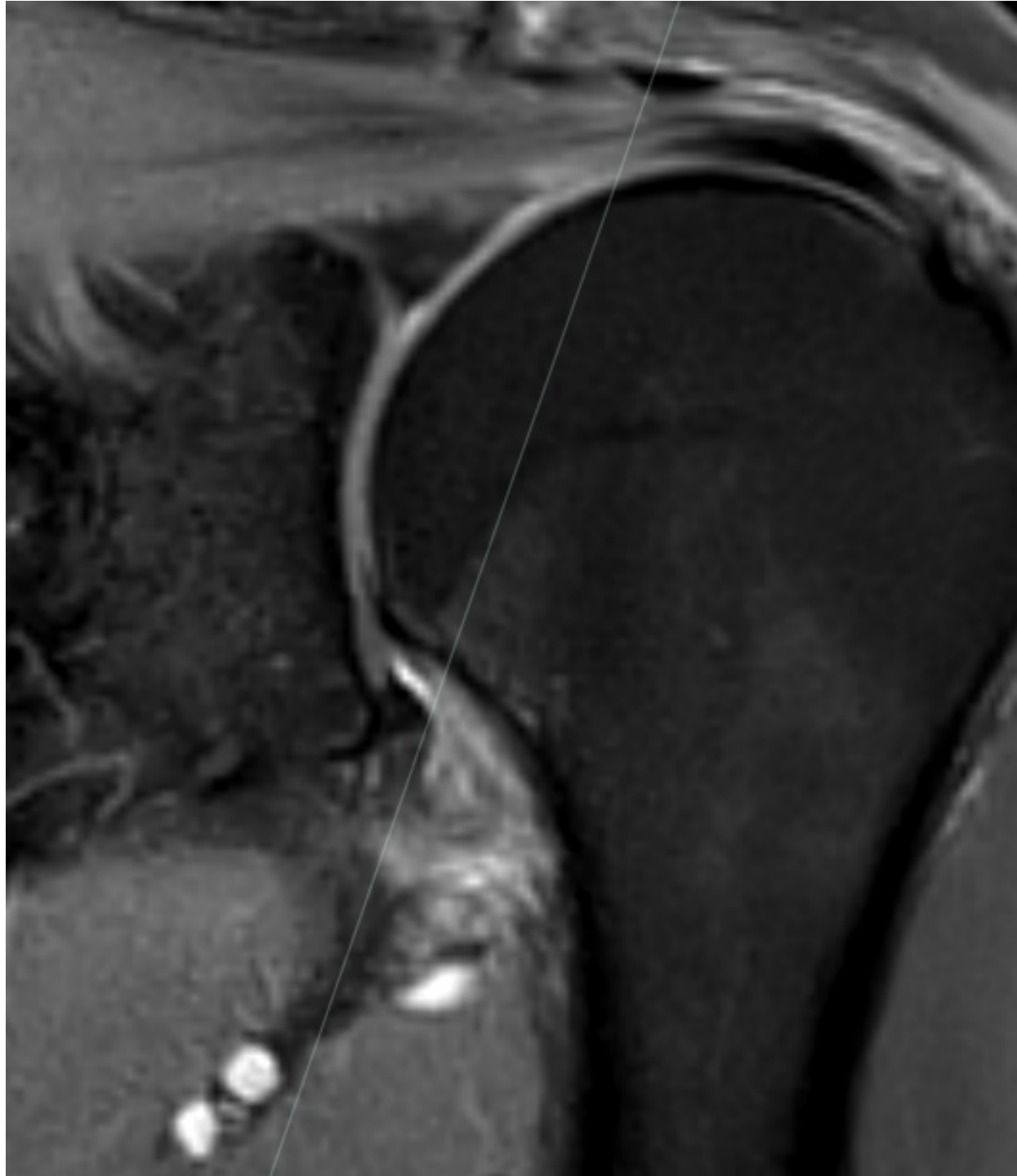
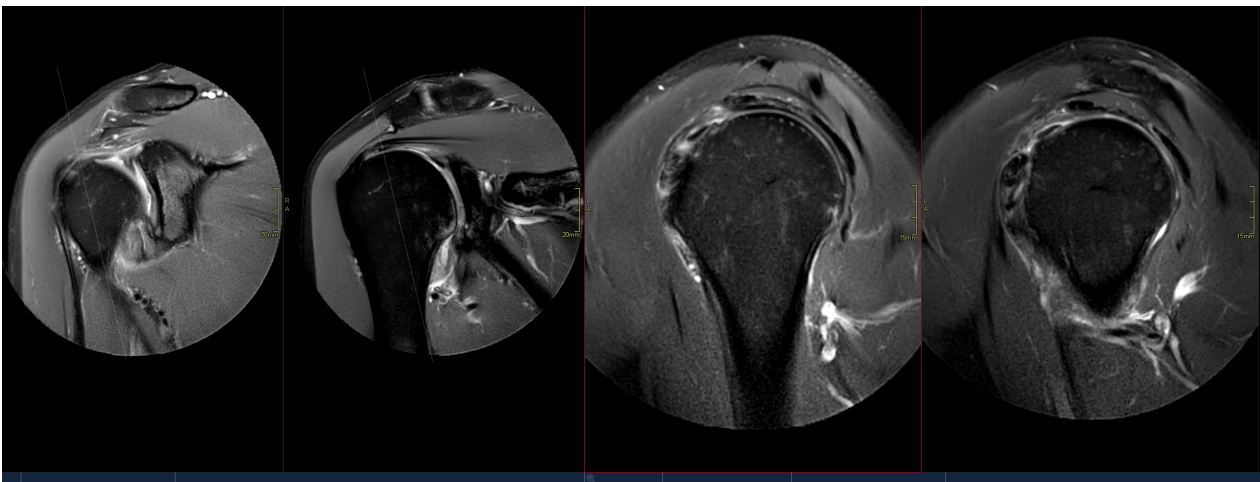
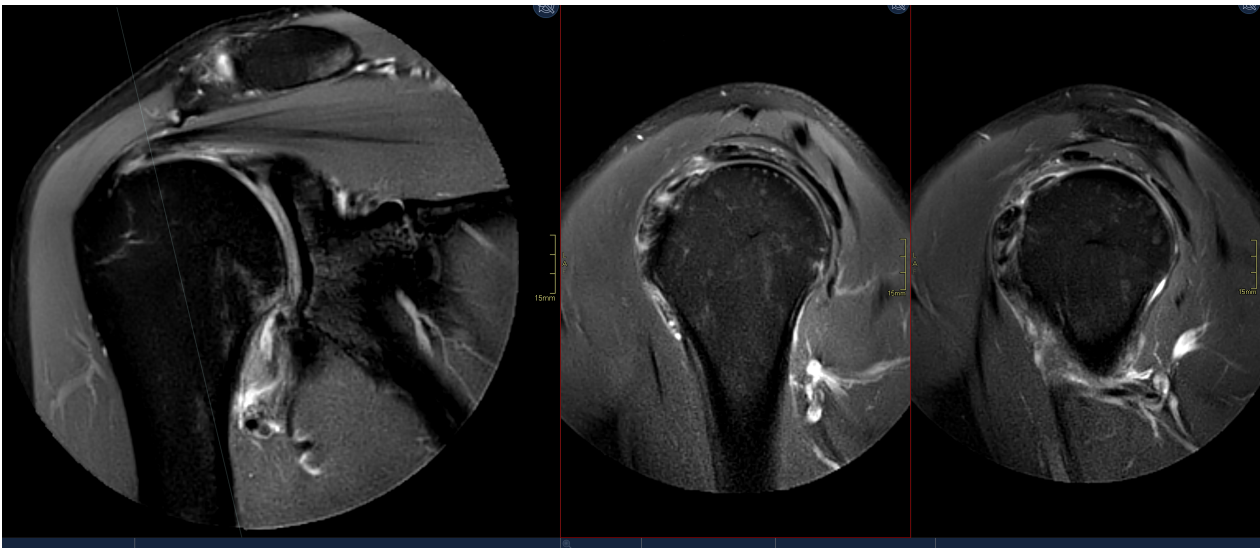
# LHB



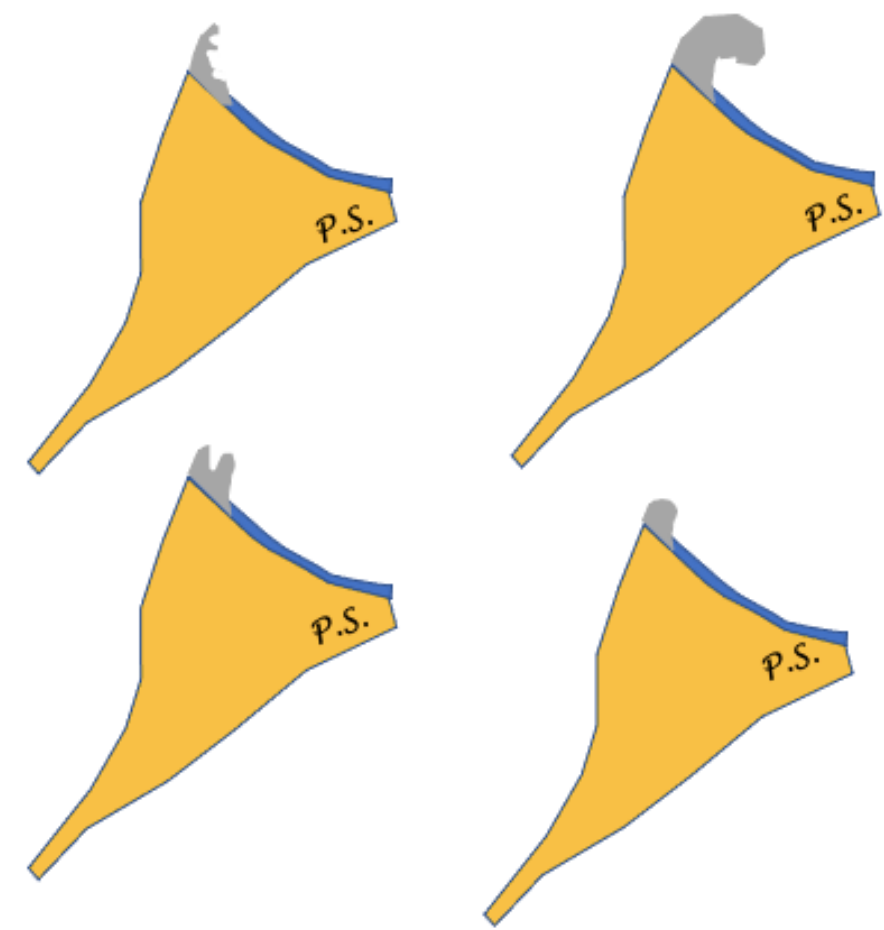
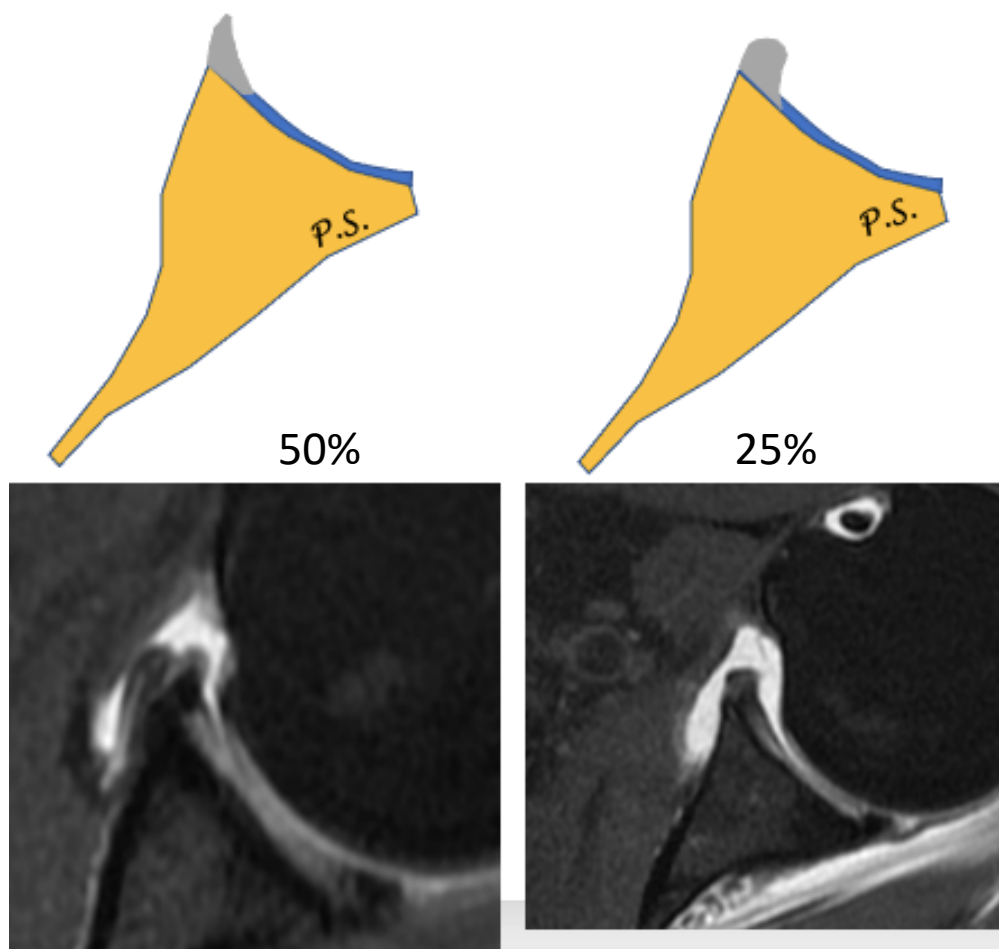
# Articular capsule

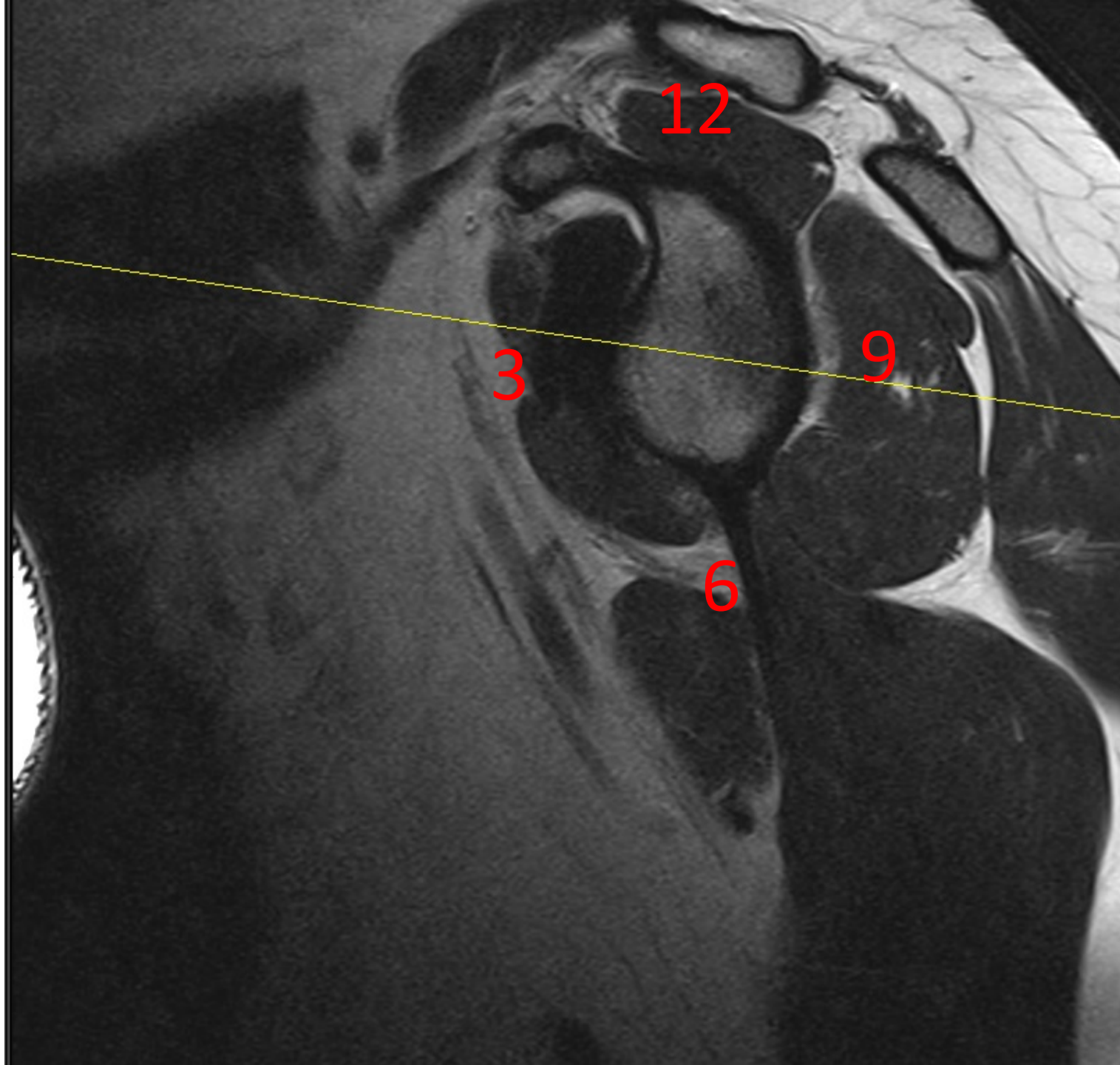


# Capsulitis adhesiva

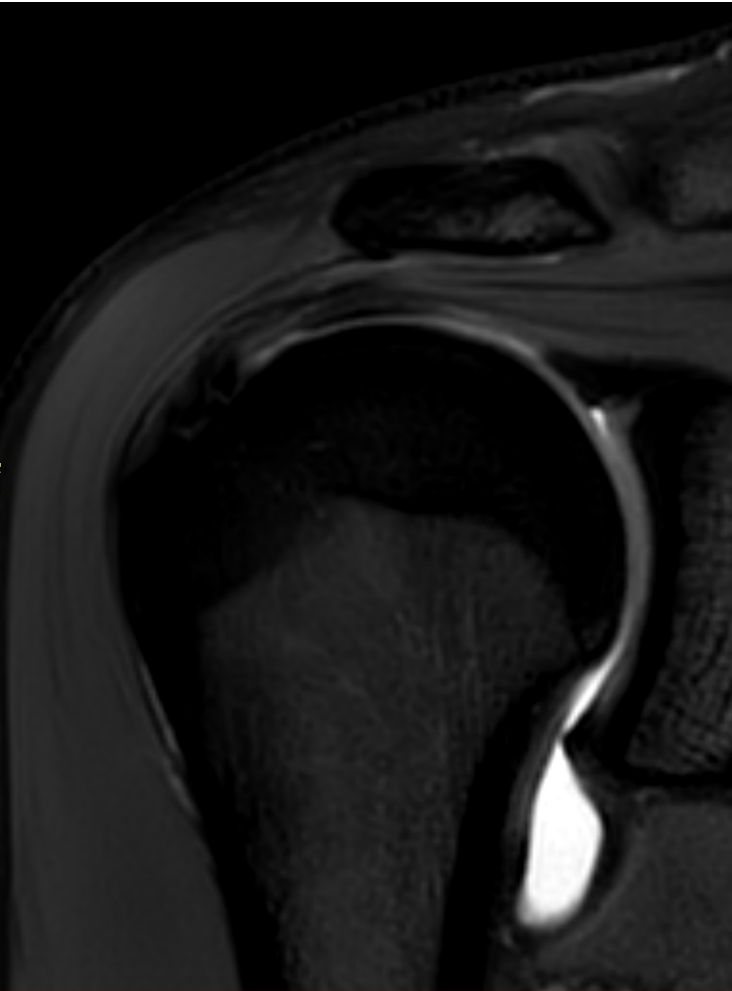


# Labrum



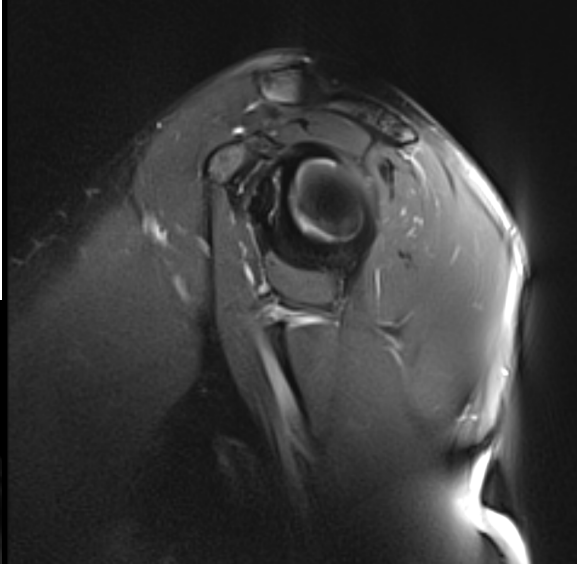
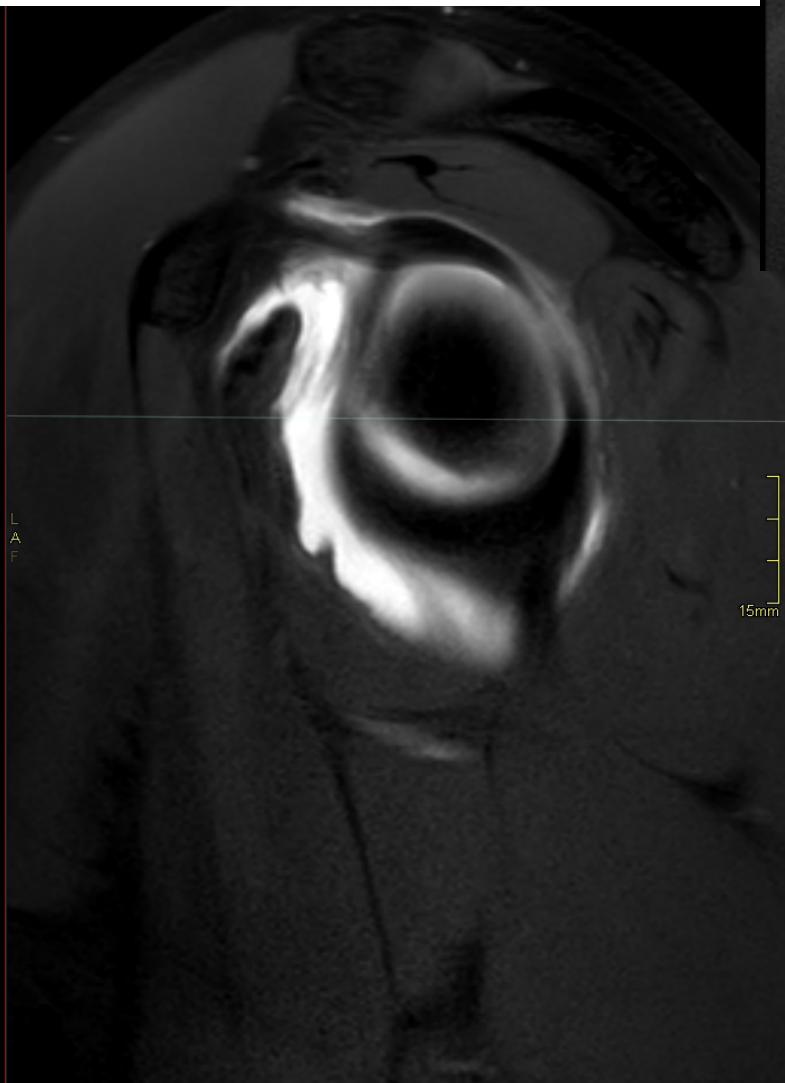
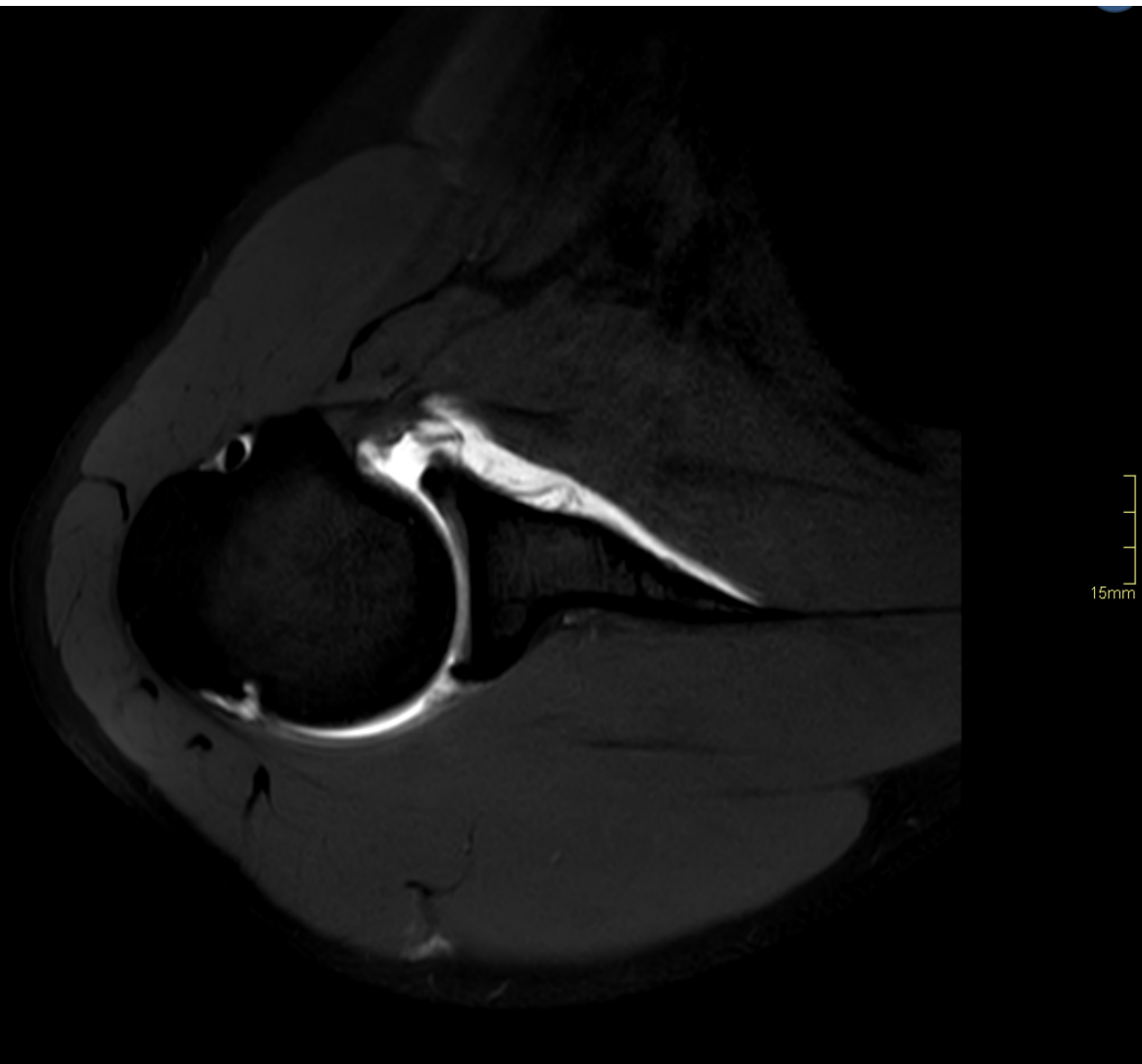


# Labrum

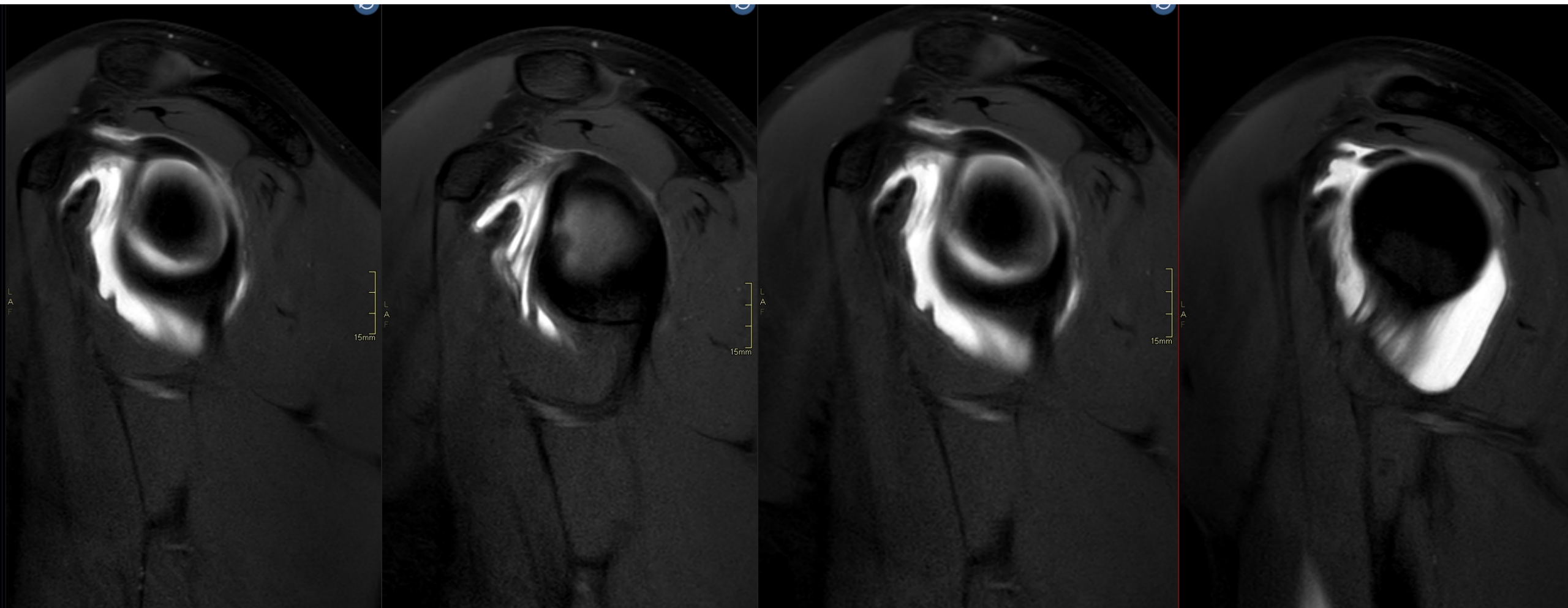




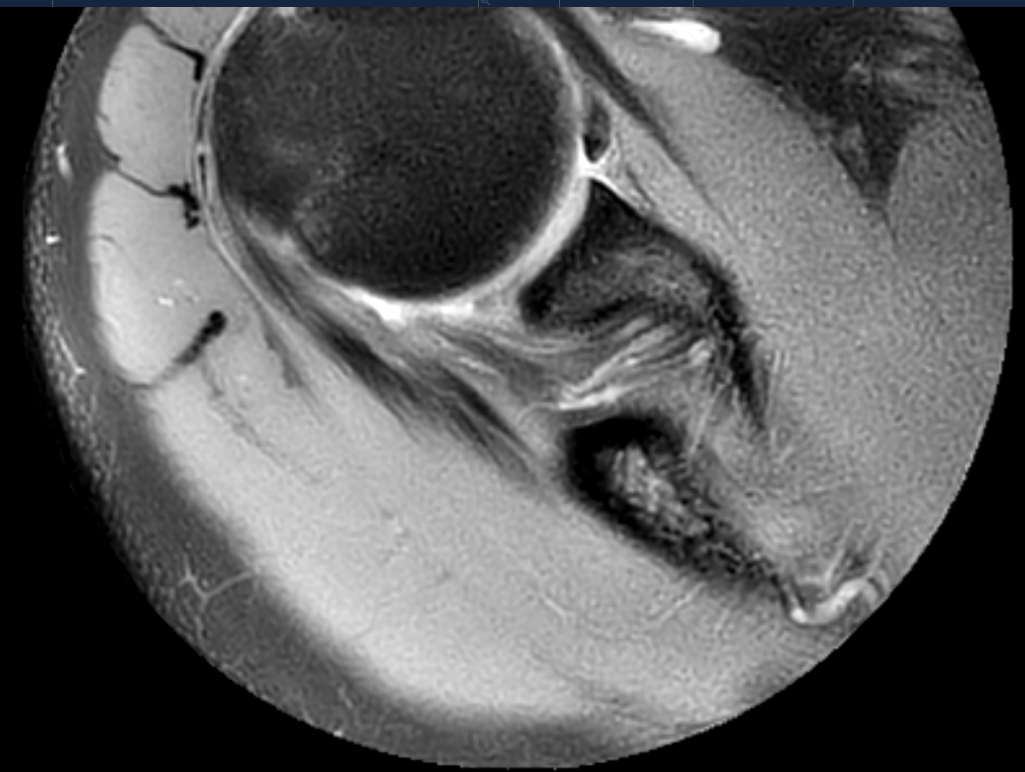
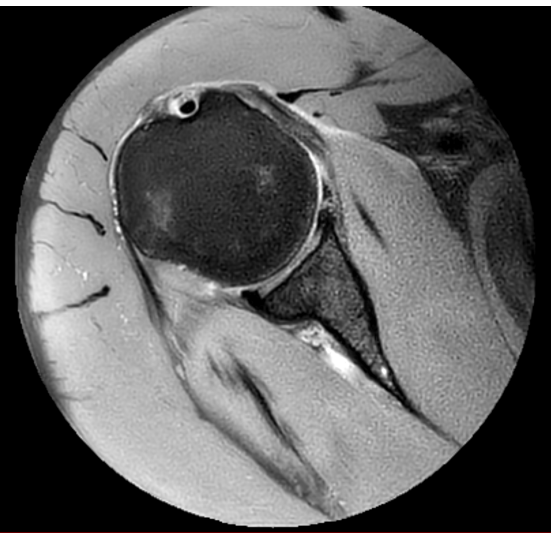
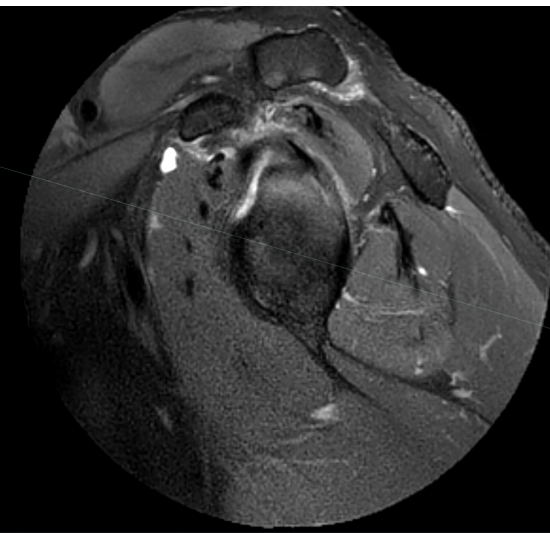
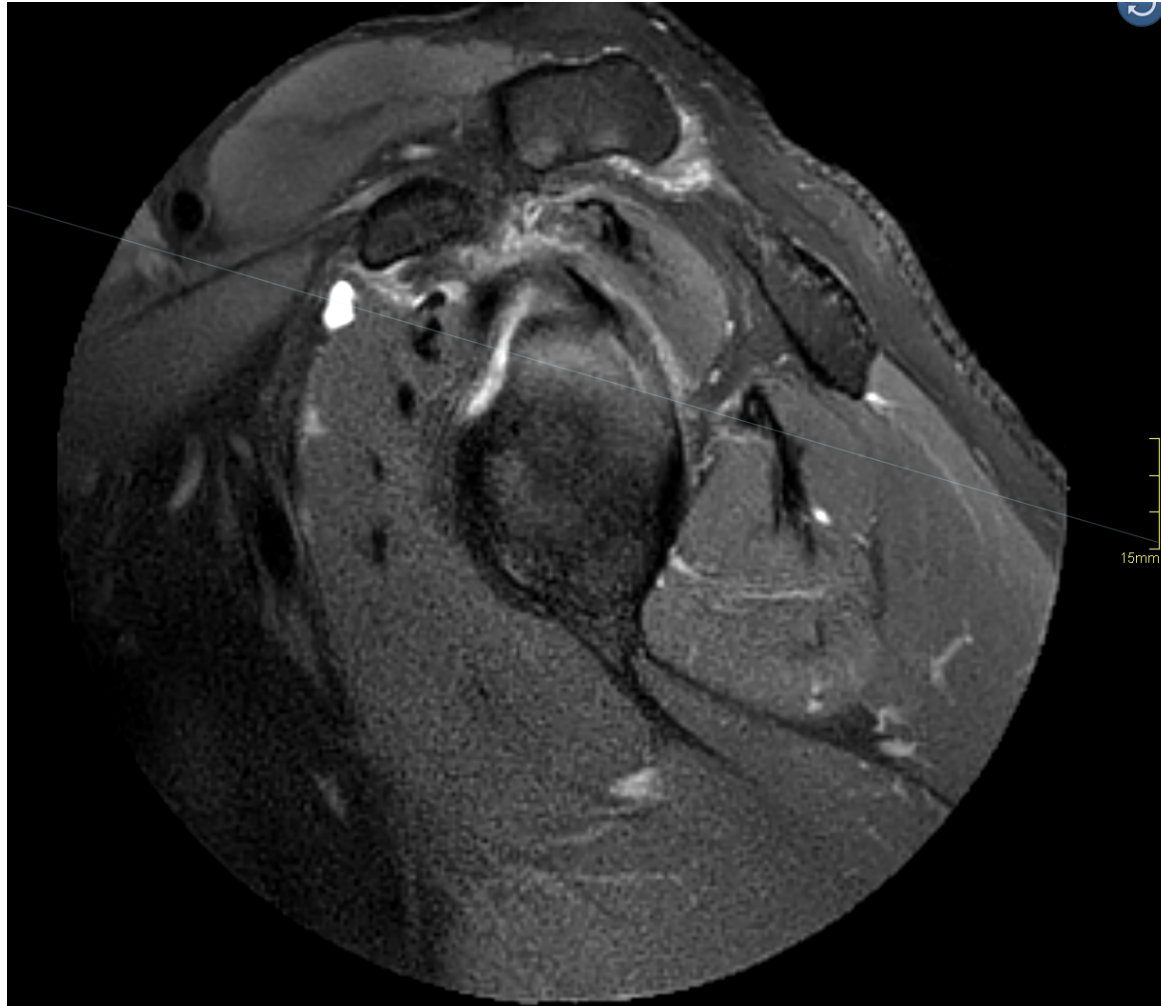# Labrum



# Ligament – case 02!

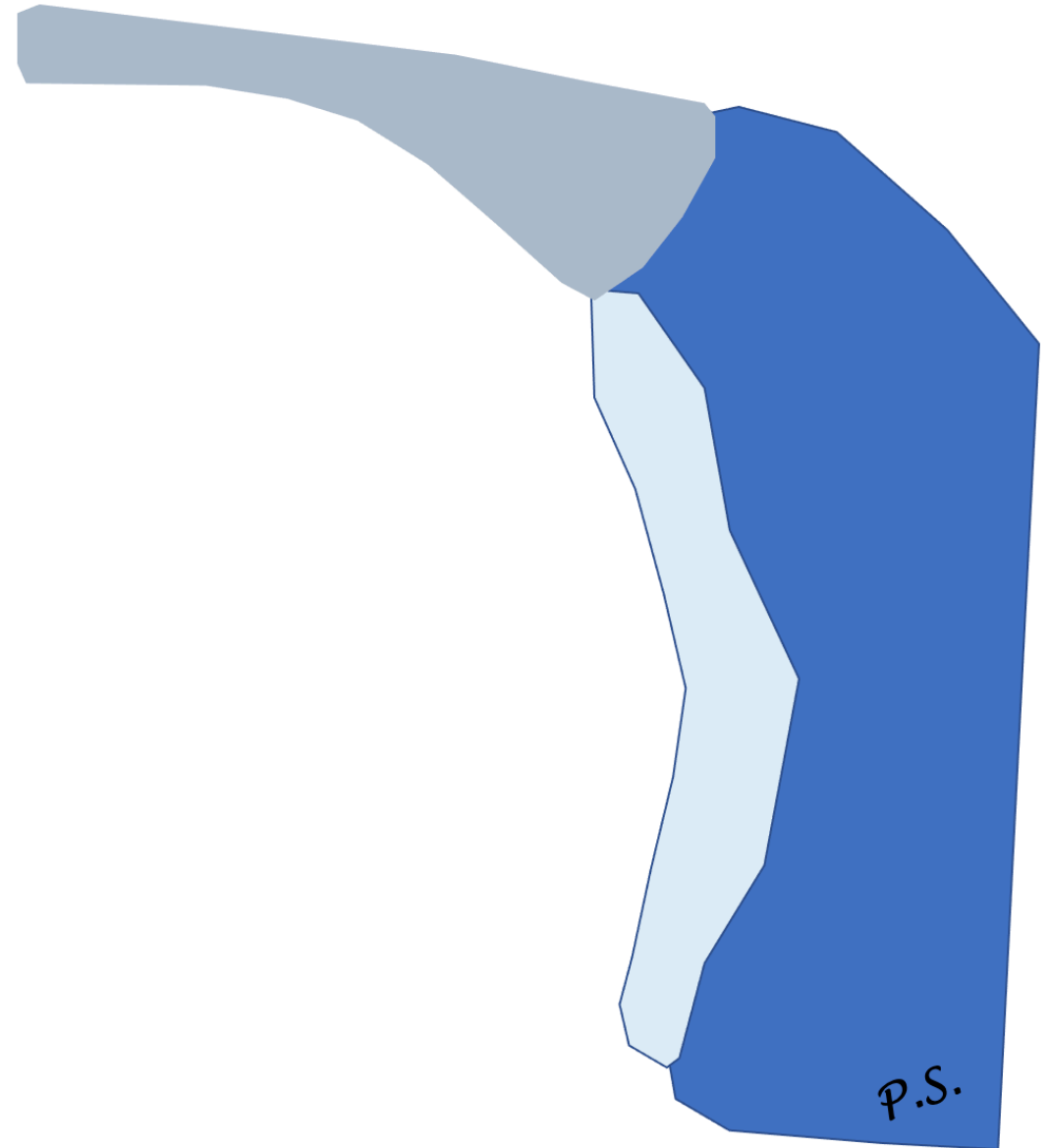


# Buford complex



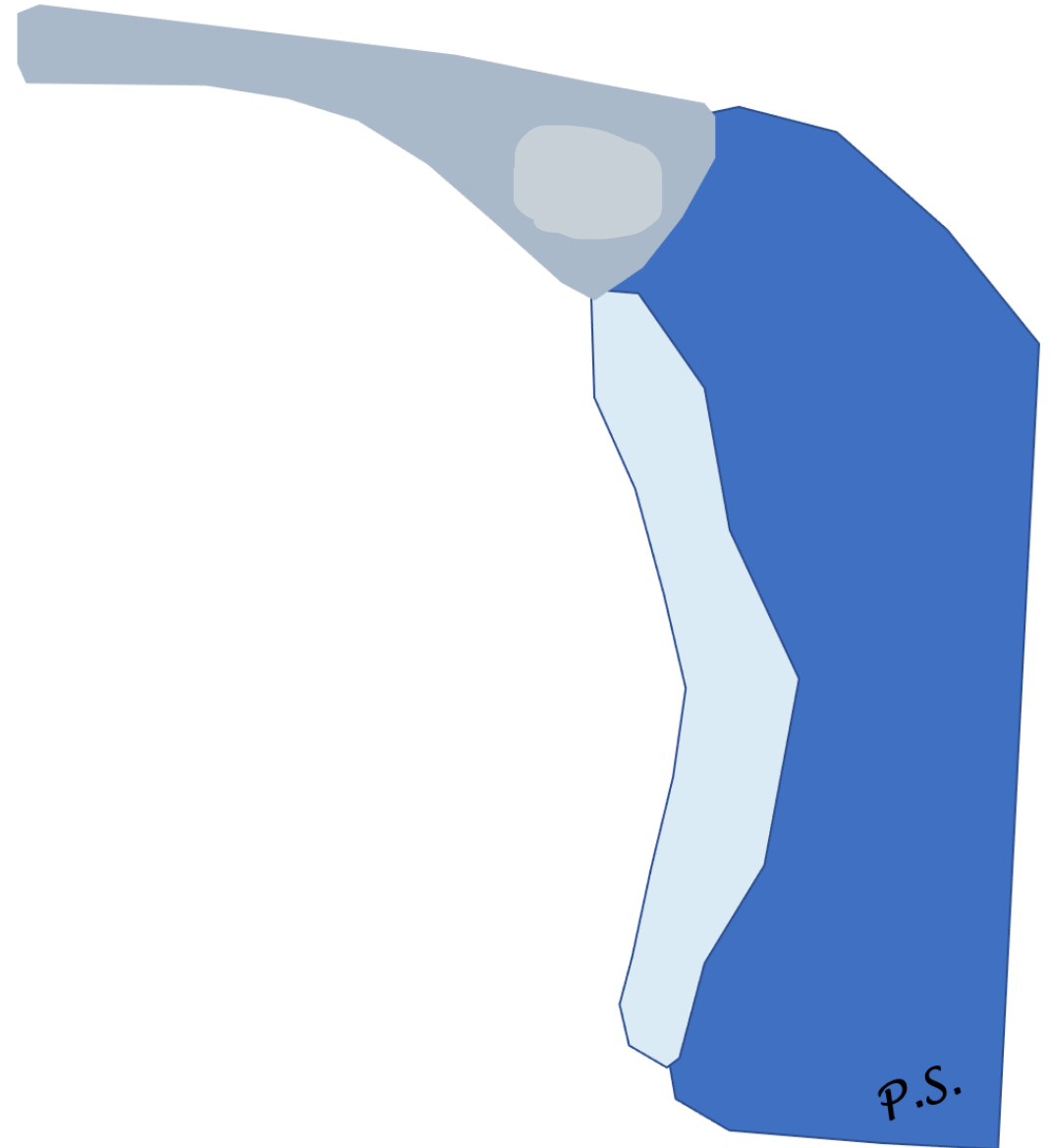
# Labrum

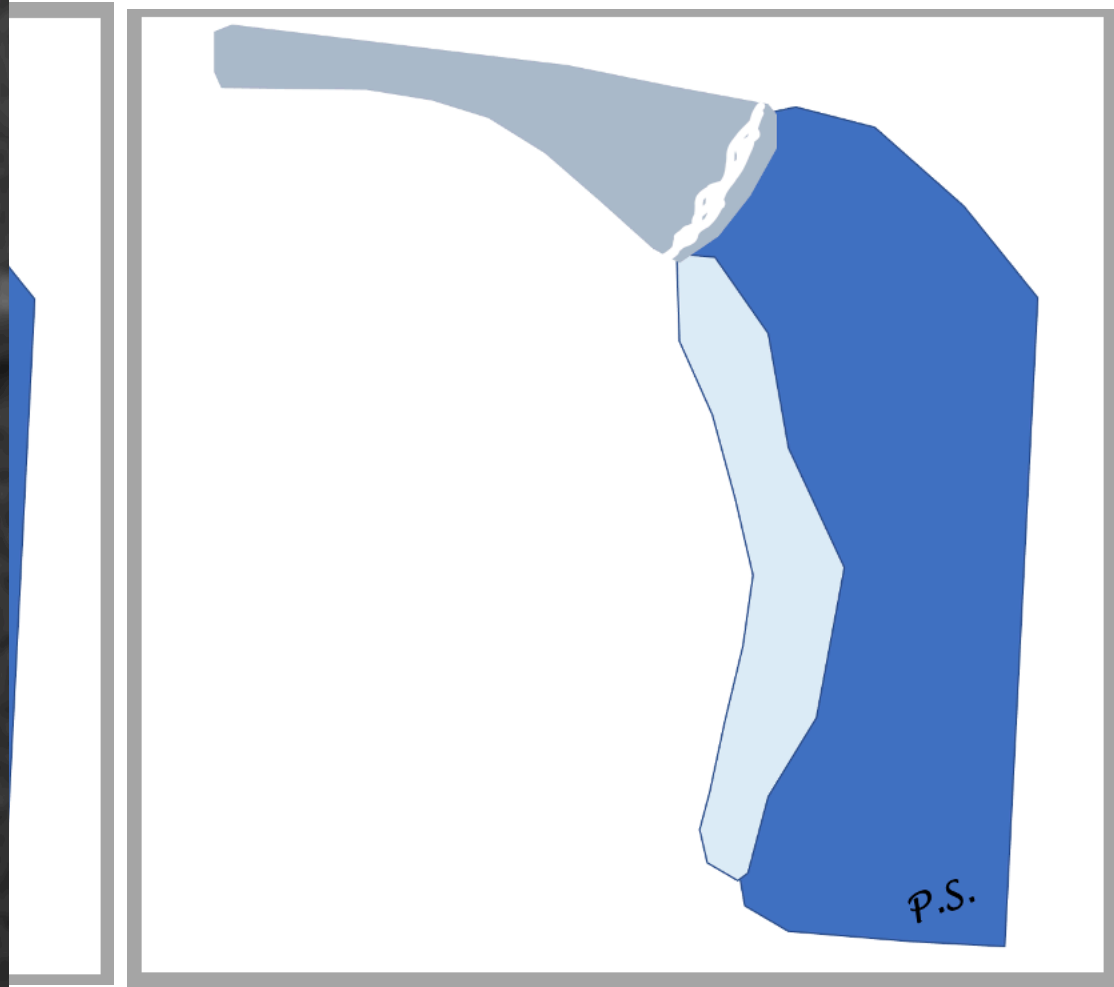
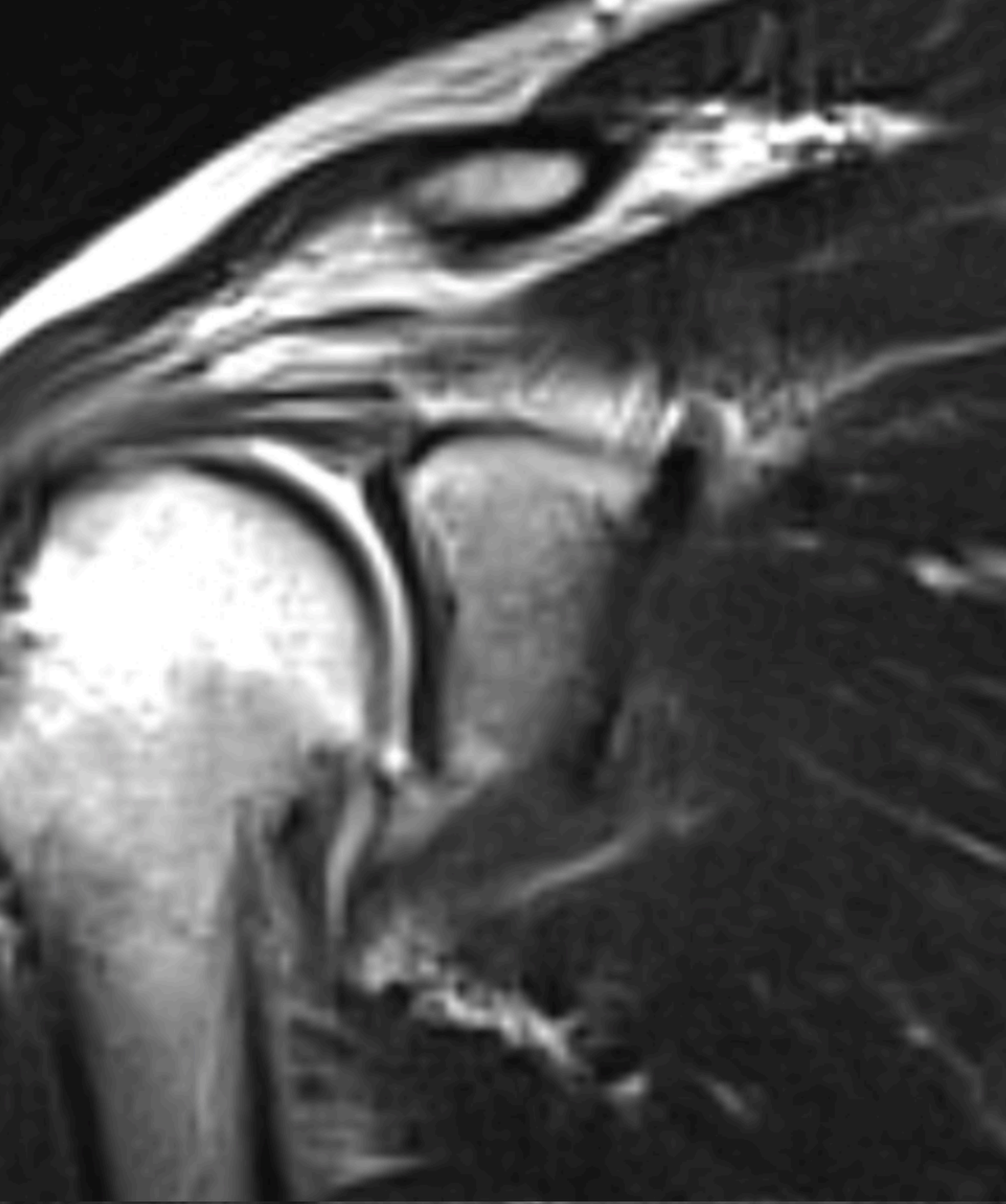
- SLAP
  - Acute or chronic trauma
  - Fall, anterior shoulder repetitive torsion (overhead athletes)

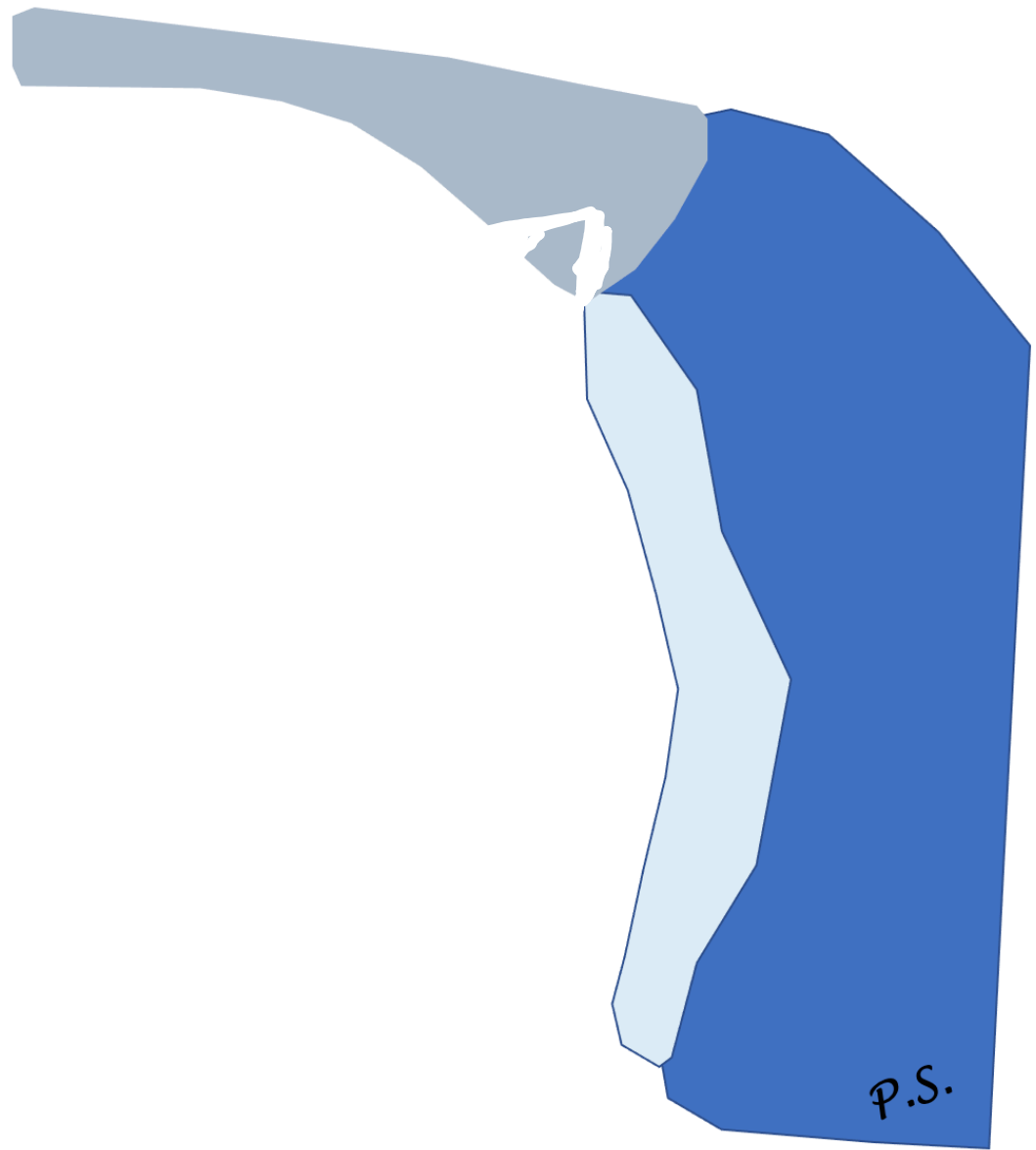
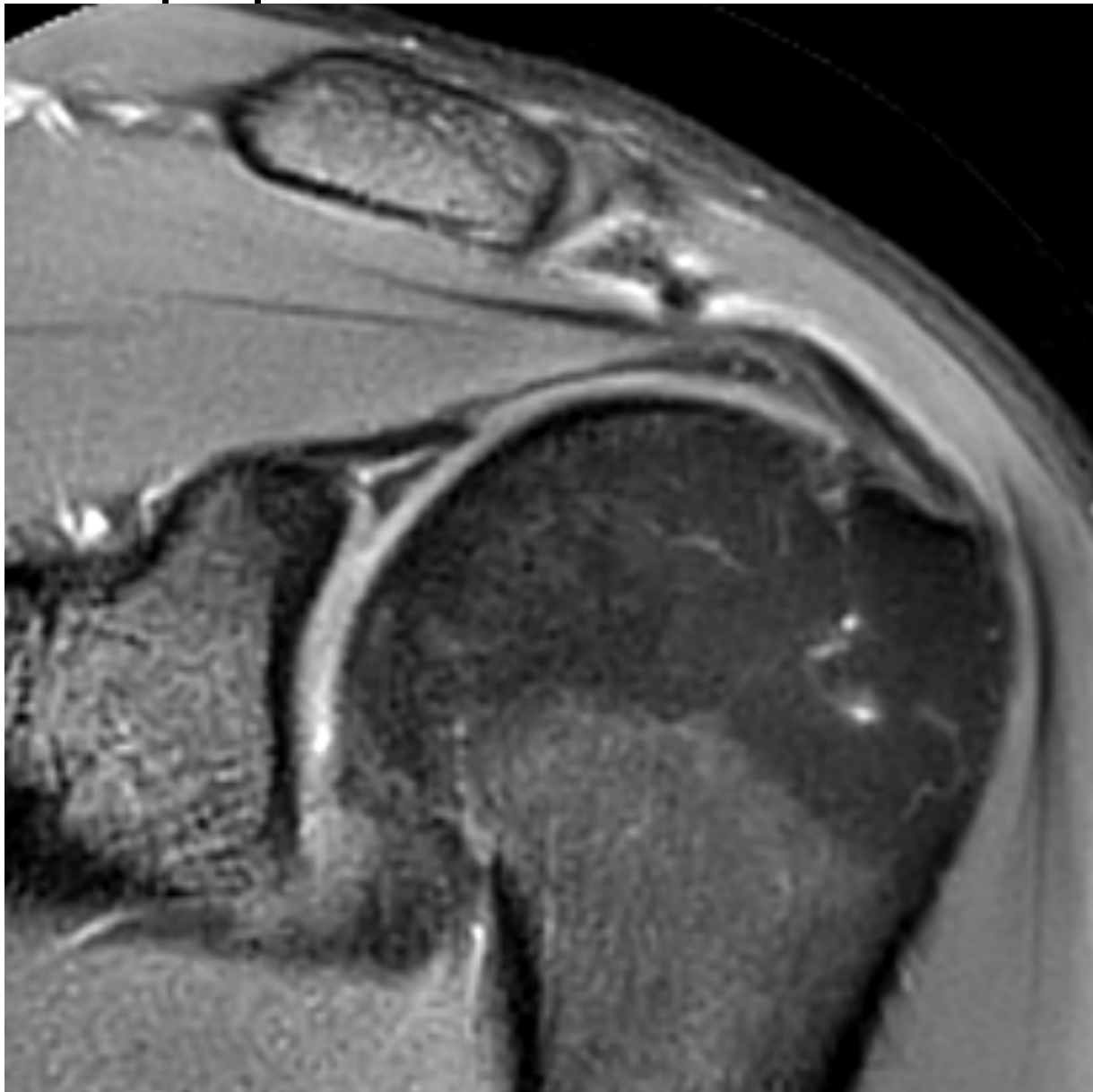


# Labrum

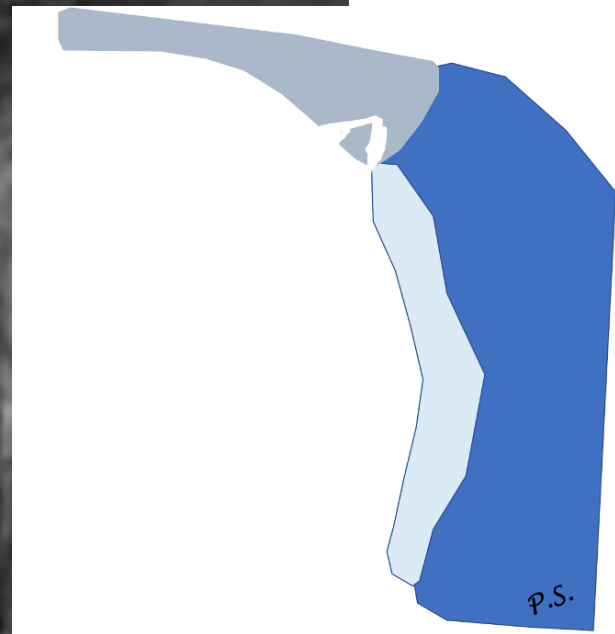
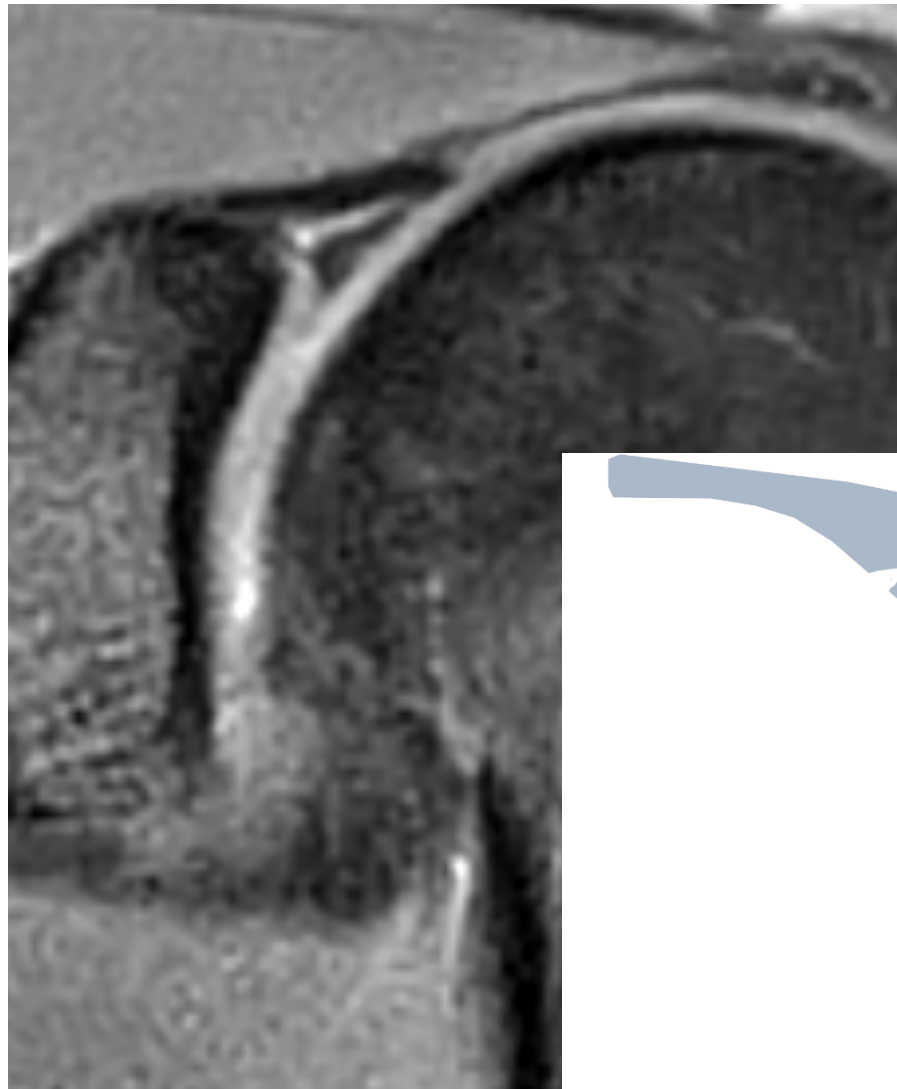
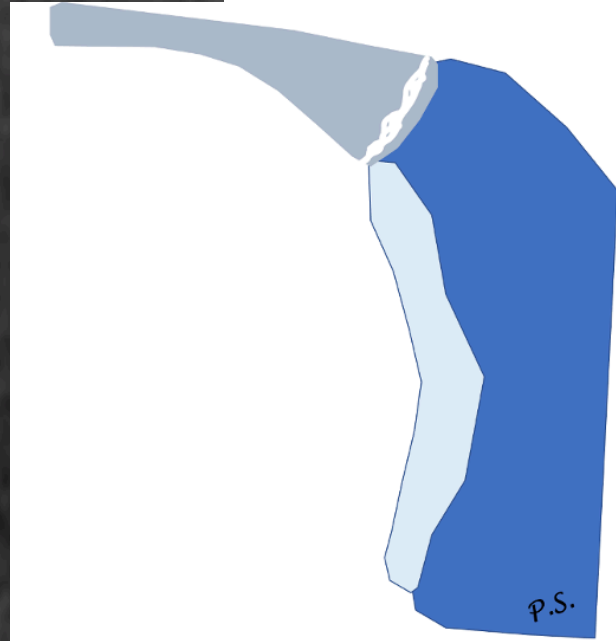
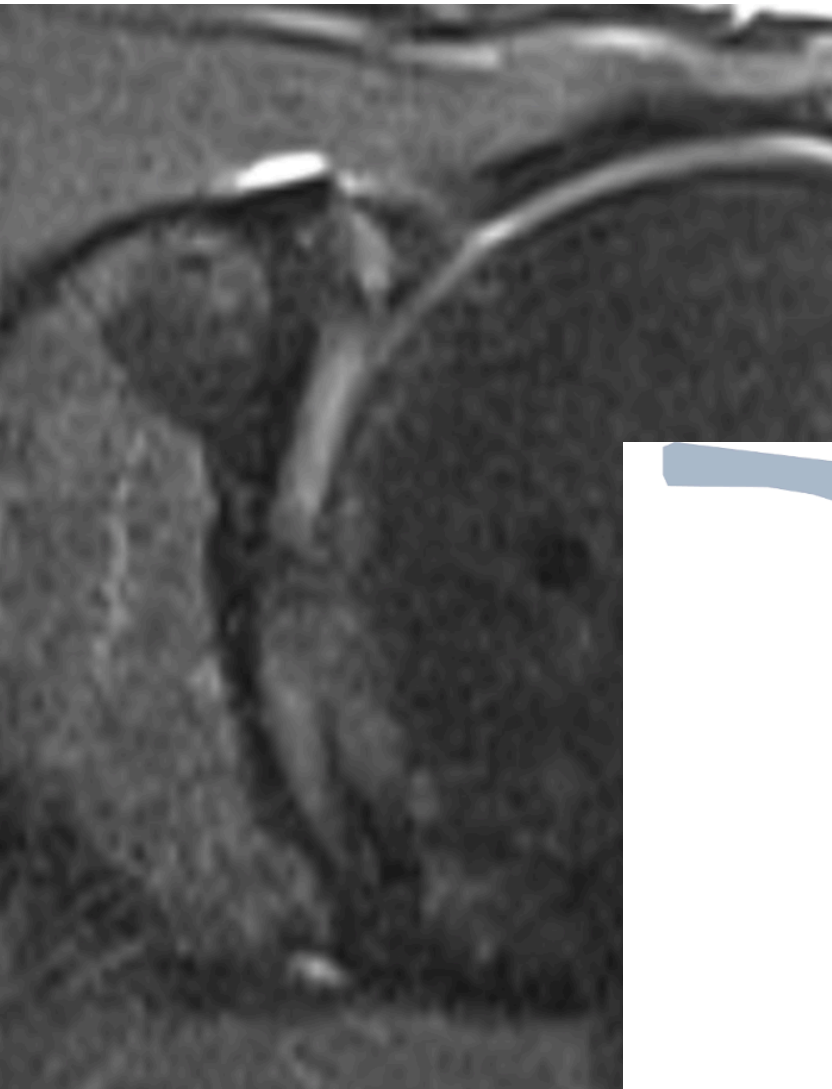
- SLAP
  - Acute or chronic trauma
  - Fall, anterior shoulder repetitive torsion (overhead athletes)





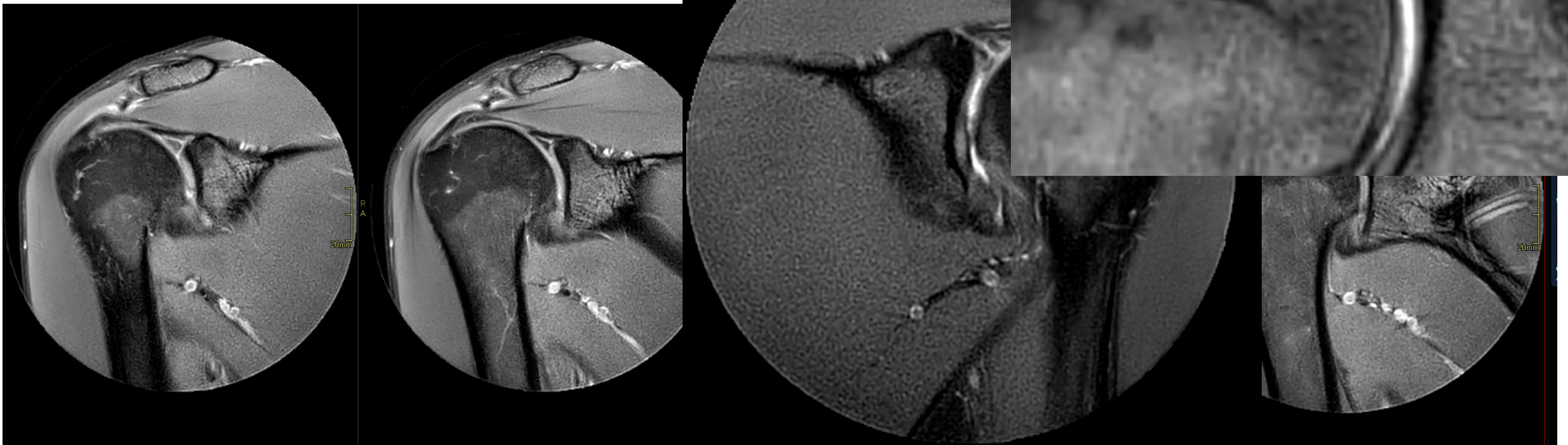


# SLAP 2 vs. 3





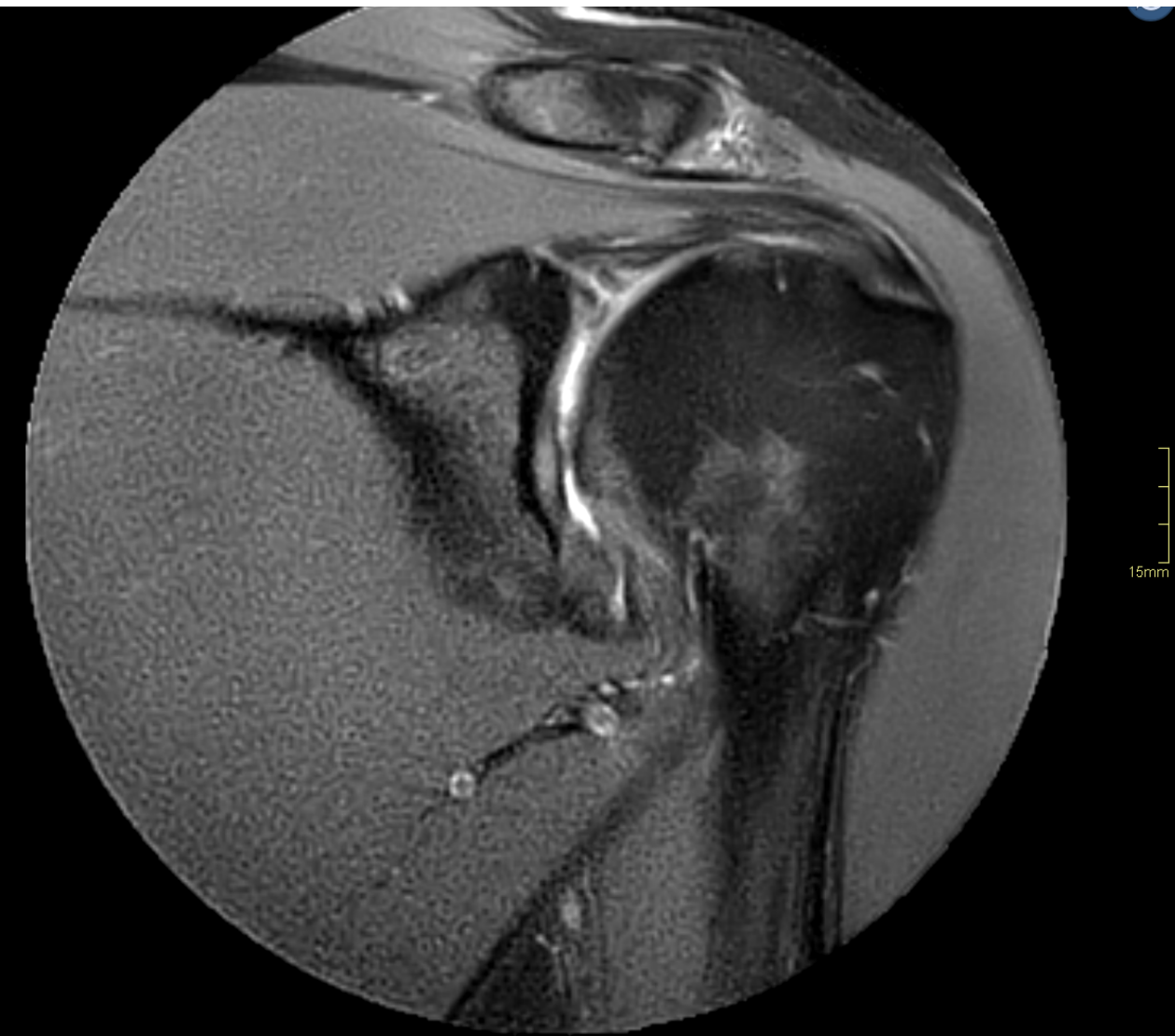# SLAP



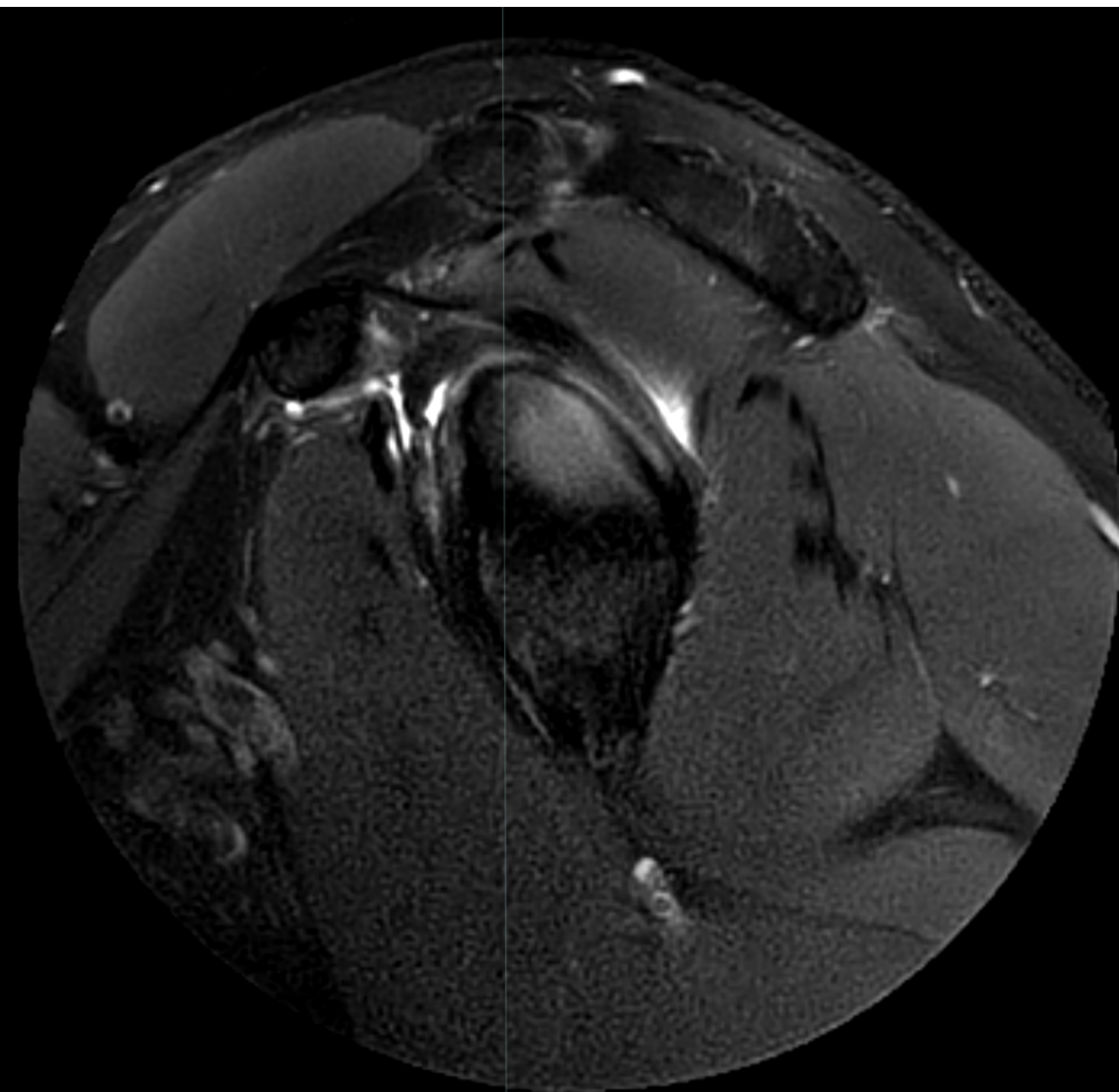
T2\_TSE\_SPAIR\_MV\_Cor

W:1865/L:1192 SI

# SLAP 2

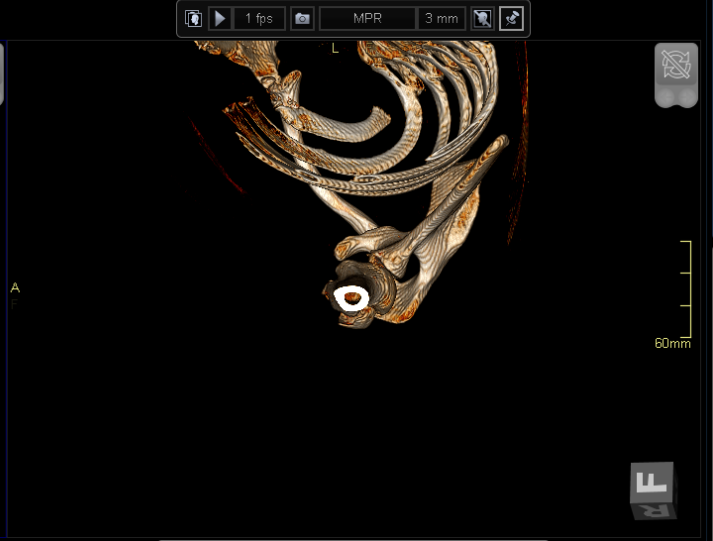
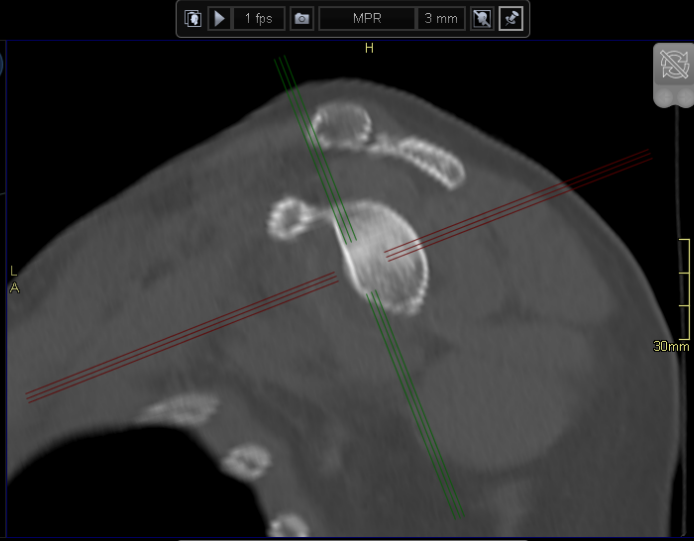
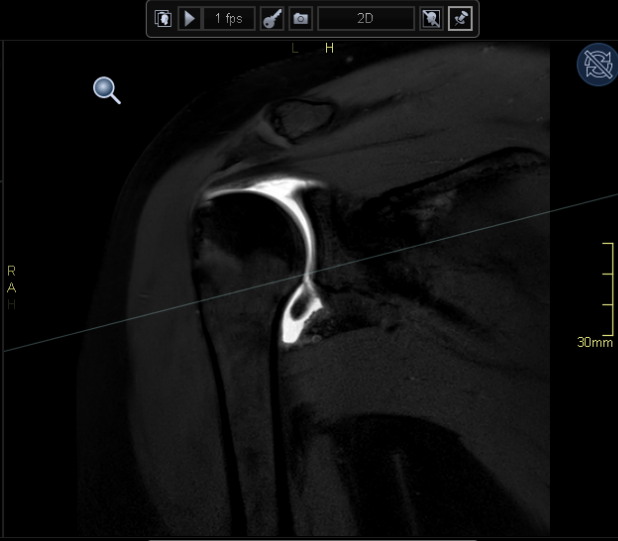
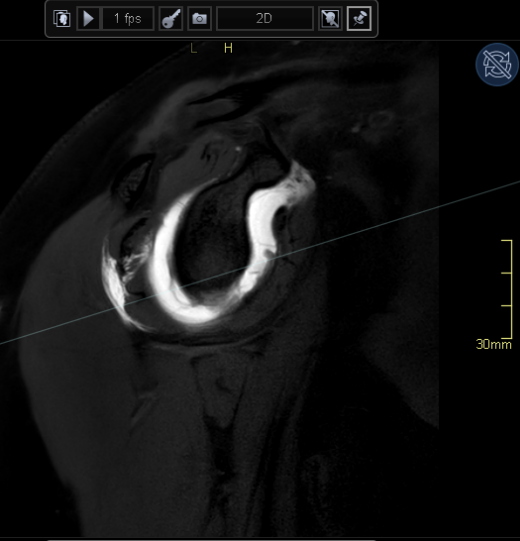
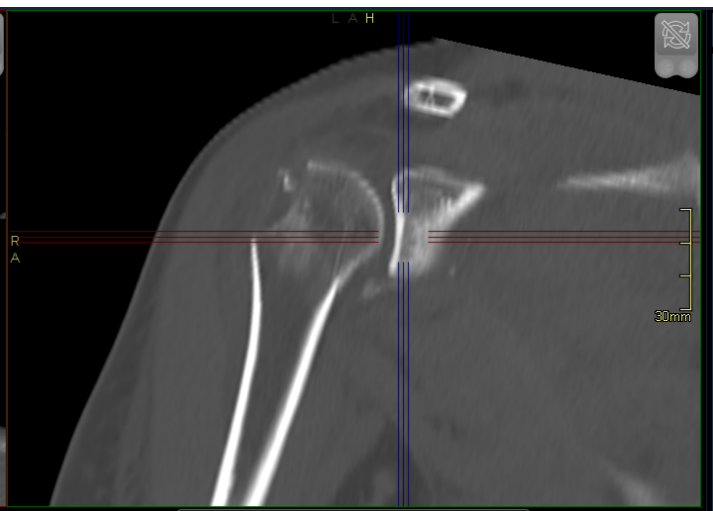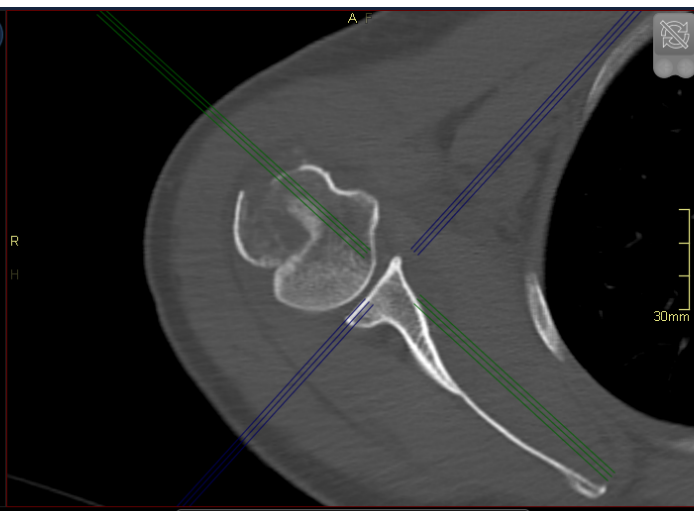
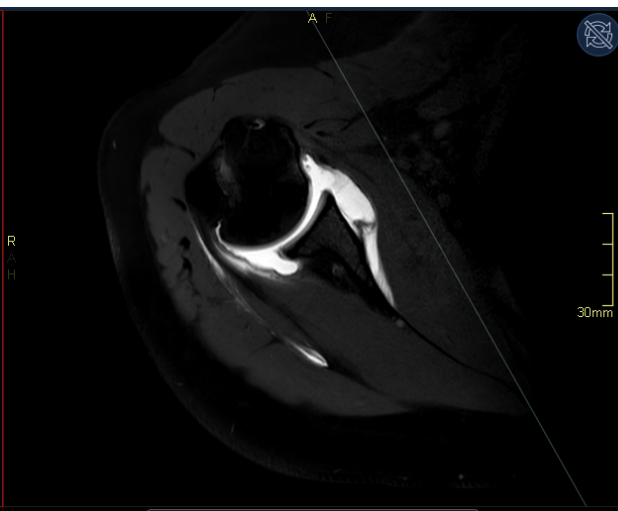
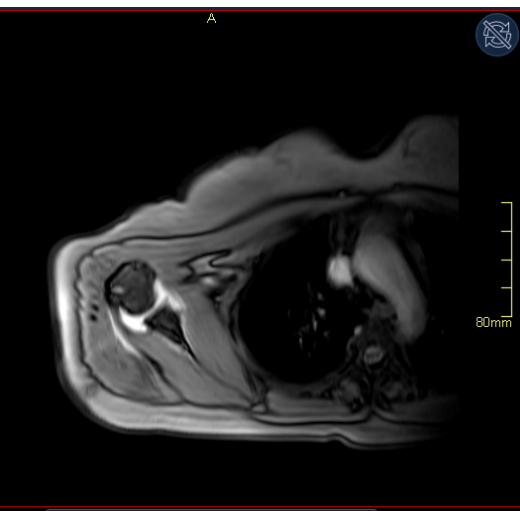


R  
A  
F  
15mm

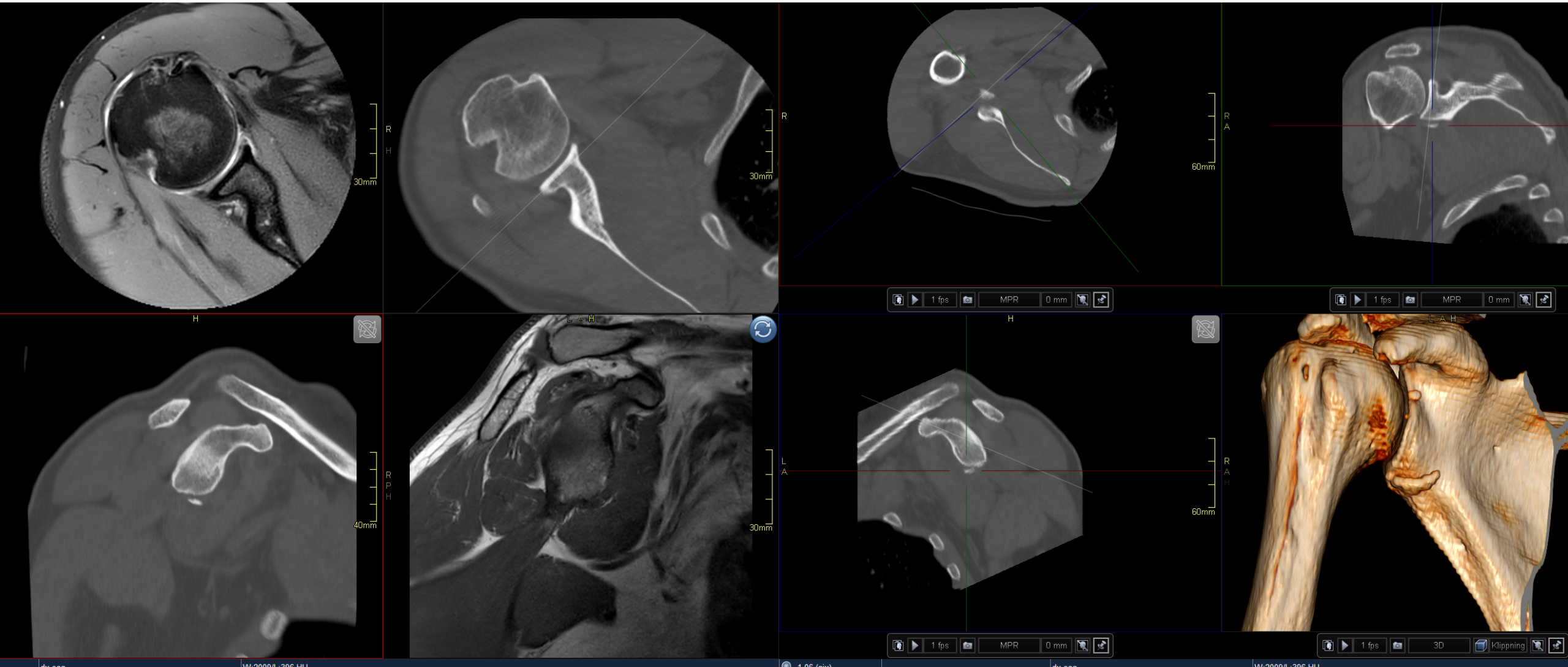


# Anterior instability

- In the vast majority of cases, ASI follows an acute xtraumatic event
- can also evolve as a result of cumulative stresses
- osseous lesions of the posterosuperior humeral head and anteroinferior glenoid inferior capsulolabral complex can demonstrate various injury patterns, including soft tissue Bankart lesion, Perthes lesion, anterior labroligamentous periosteal sleeve avulsion (ALPSA), glenolabral articular disruption (GLAD) lesion, and humeral avulsion of the glenohumeral ligament (HAGL) lesion

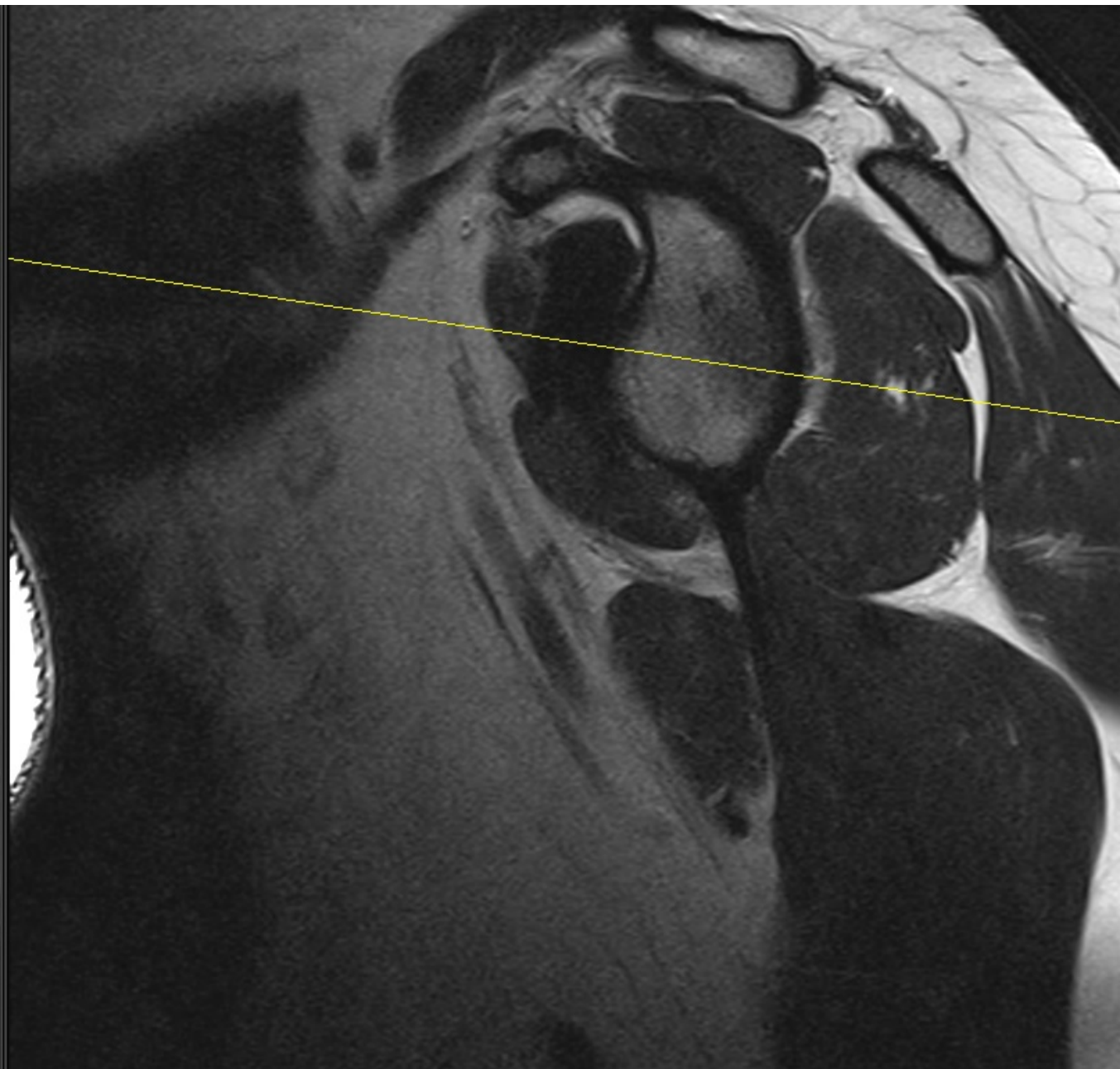
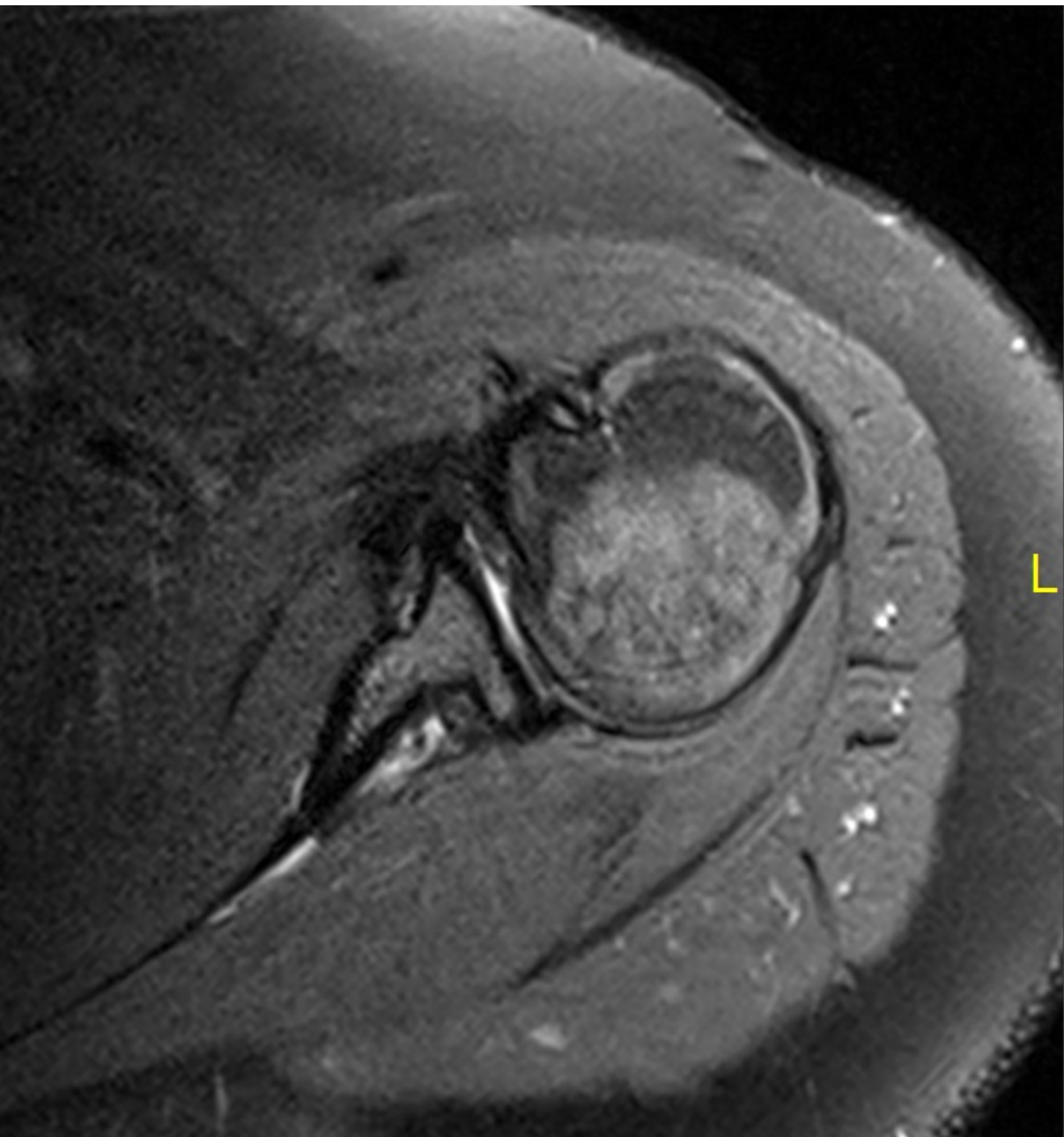


# Anterior instability



# Posterior shoulder dislocation

- is less common than anterior instability
- posterior dislocation generally is not the starting point of posterior instability as opposed to an anterior shoulder dislocation
- multidirectional shoulder instability or anatomic abnormalities involving the glenoid, humeral head, posterior capsule, and labrum, which can predispose to shoulder instability
- retroversion with respect to the scapular body ranging from 0 to 7 grades, superomedial to inferolateral ca 15 grades
- Glenoid dysplasia
- Posterior labral tears are less frequent in patients with posterior instability than anteroinferior labral tears in patients with anterior instability.



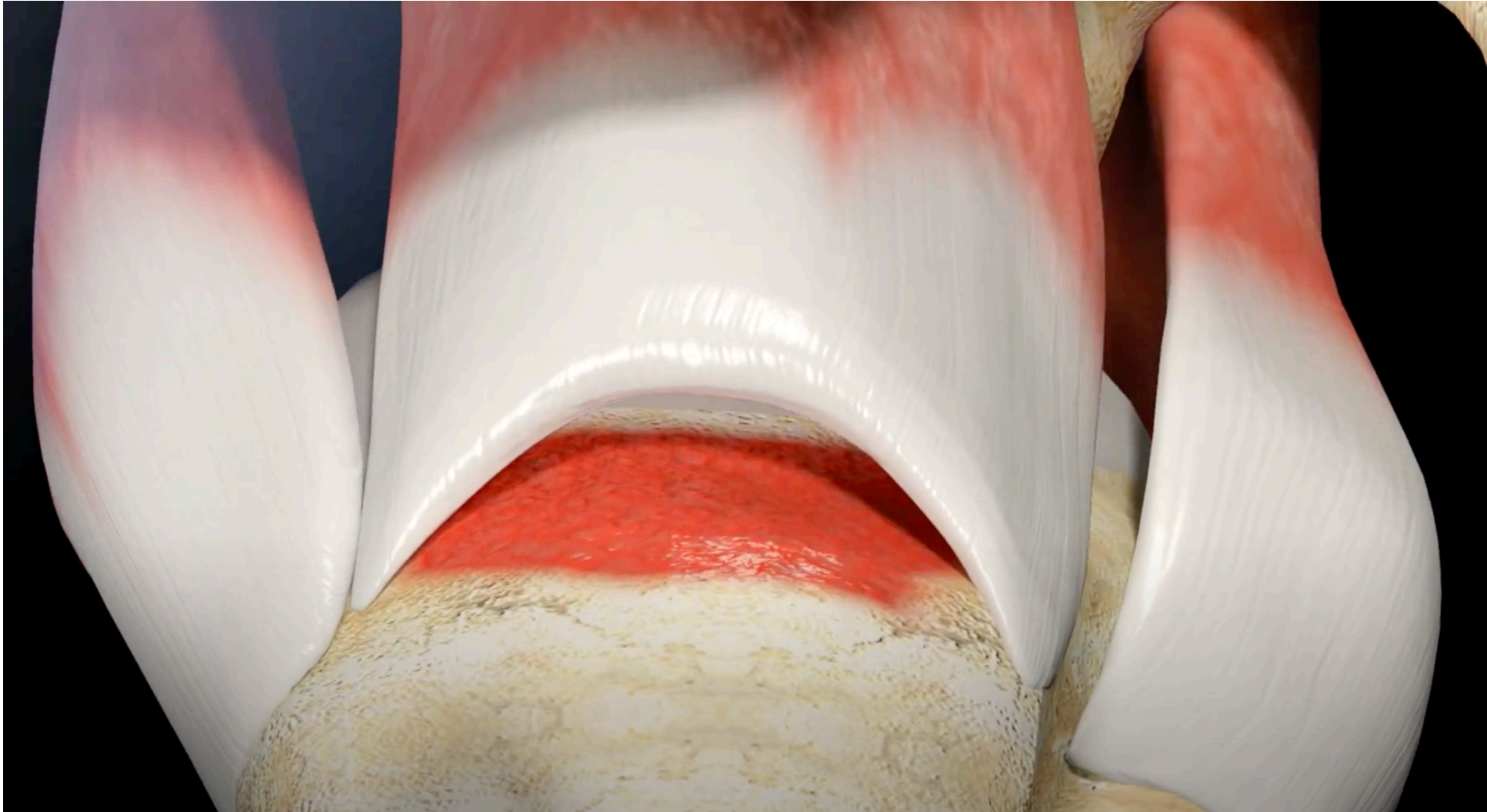
# Postoperative shoulder

## Structure

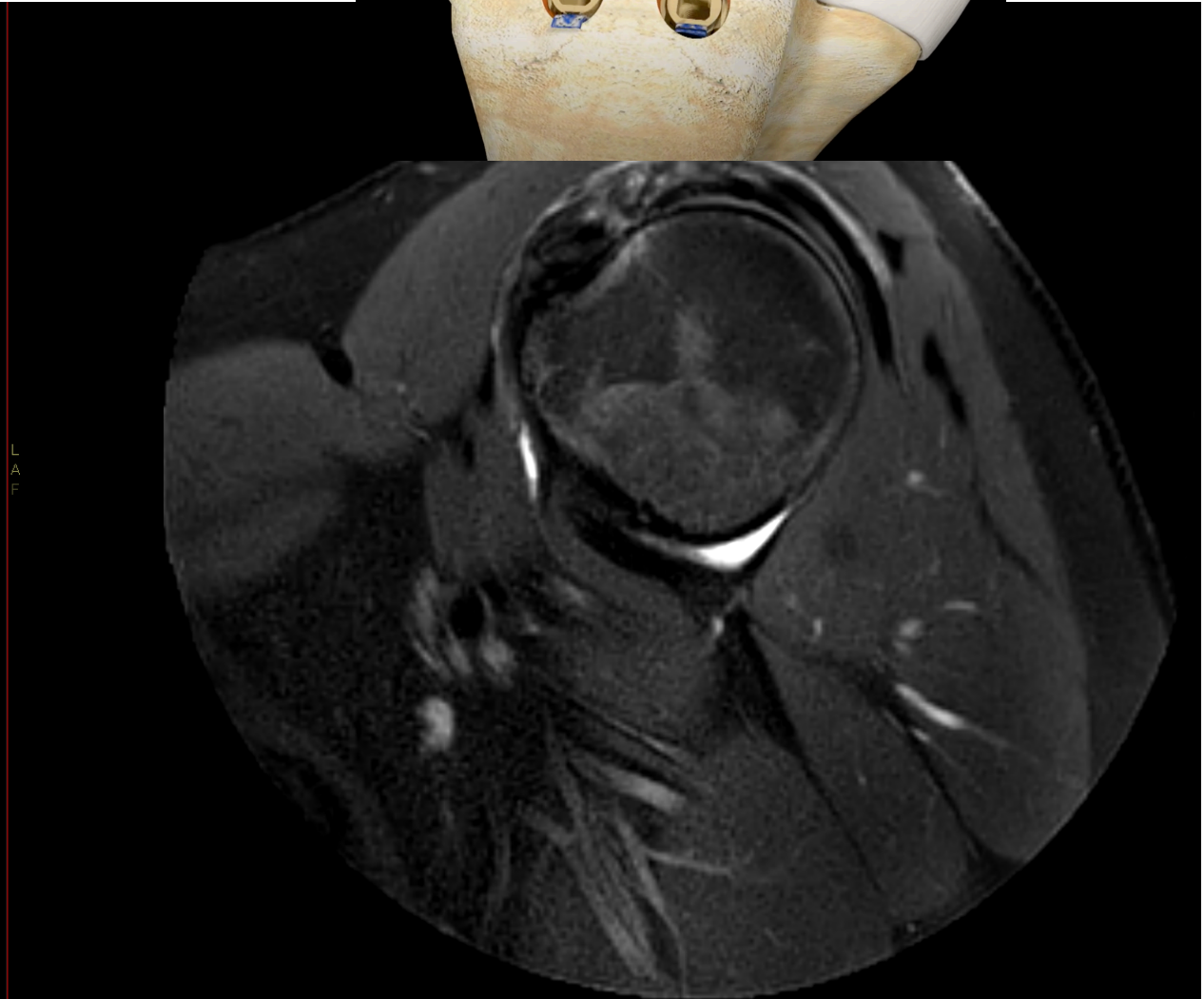
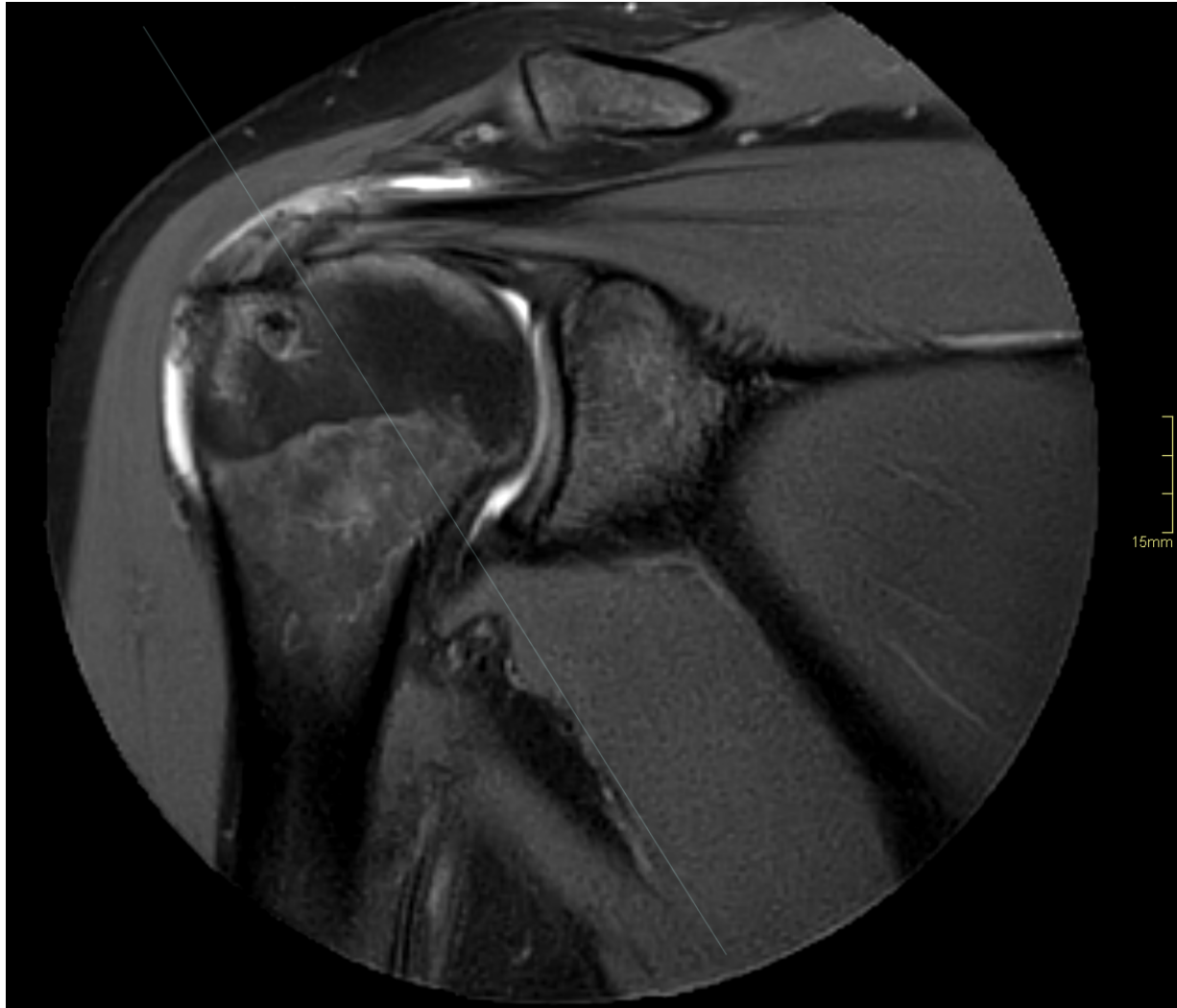
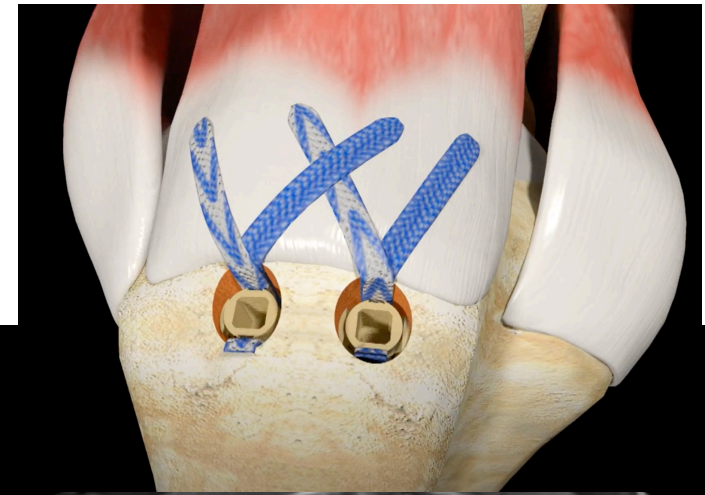
- Surgical disruption of watertight cuff is not rare
  - Communication between joint space and subacromial space is not rare
  - Defects or retears <1 cm usually do not correlate with clinical findings
  - Arthrography: contrast penetration from joint space to subacromial space
- Signal:
    - Returns to normal only in 1/10
    - Edema-like signal may be seen for as long as 5 years
    - Fibrosis/scarr
    - Granulation tissue



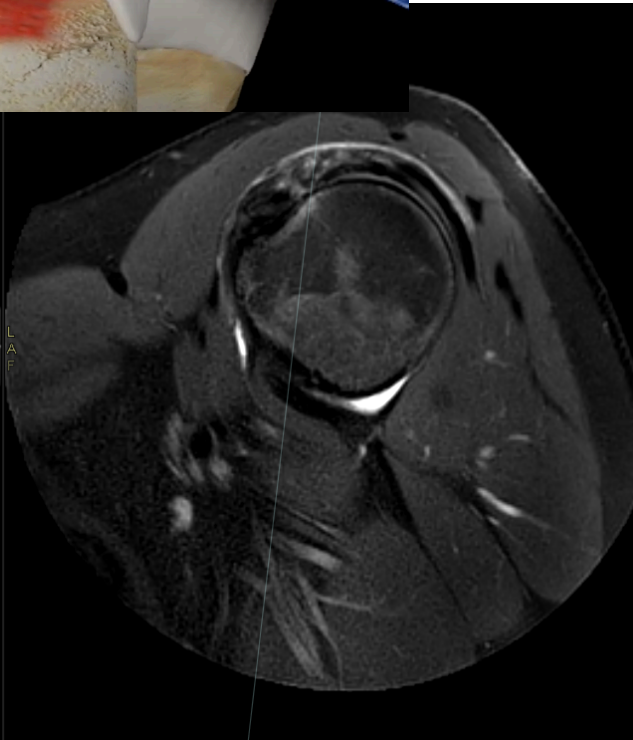
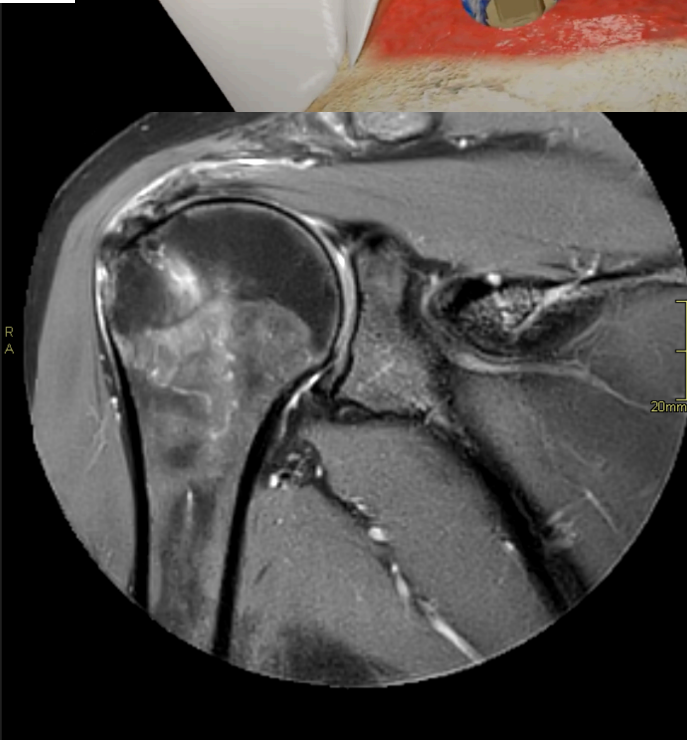
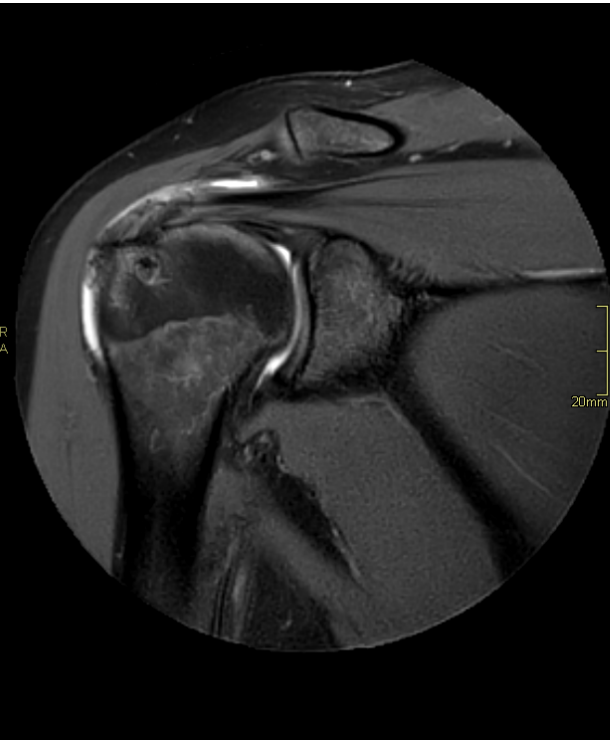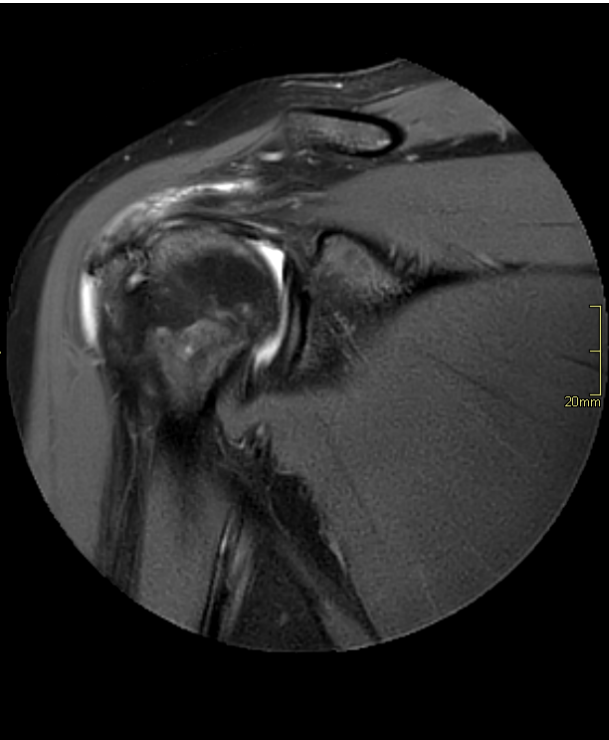
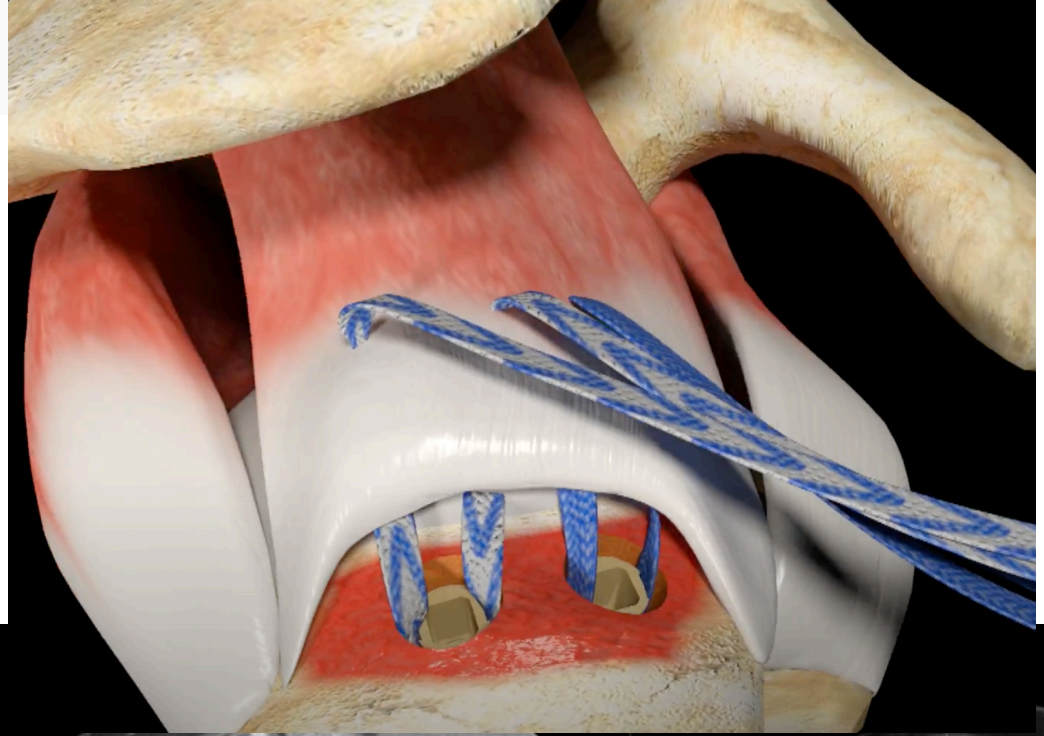
Post op



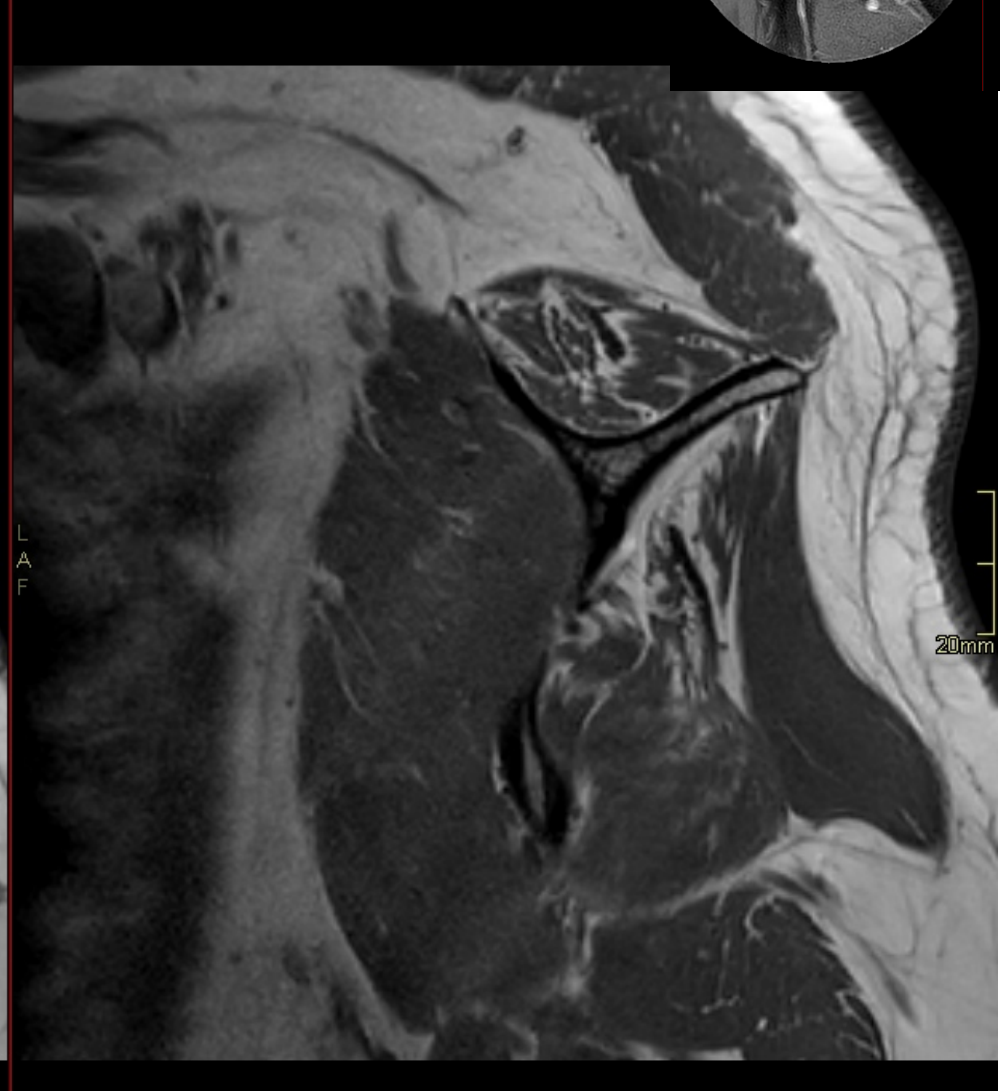
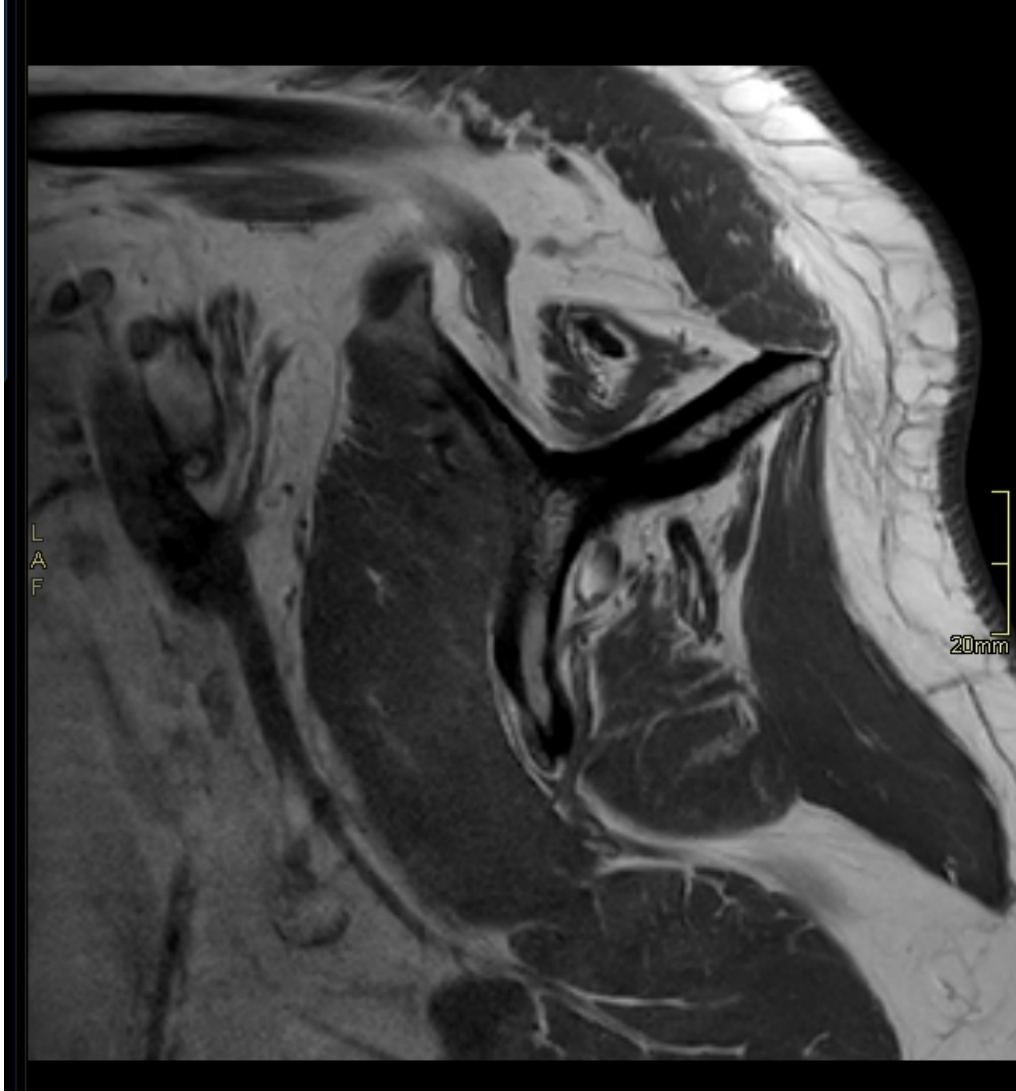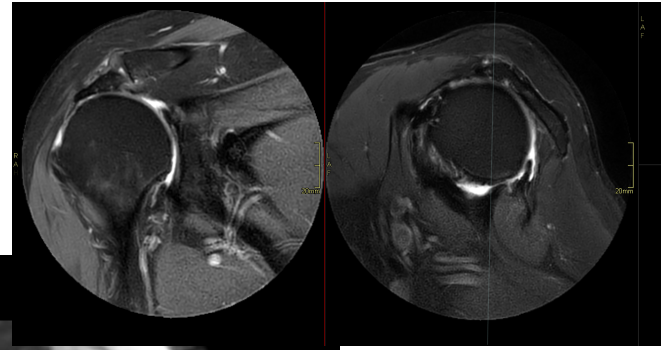
# Post operative cuff surgery



Post op

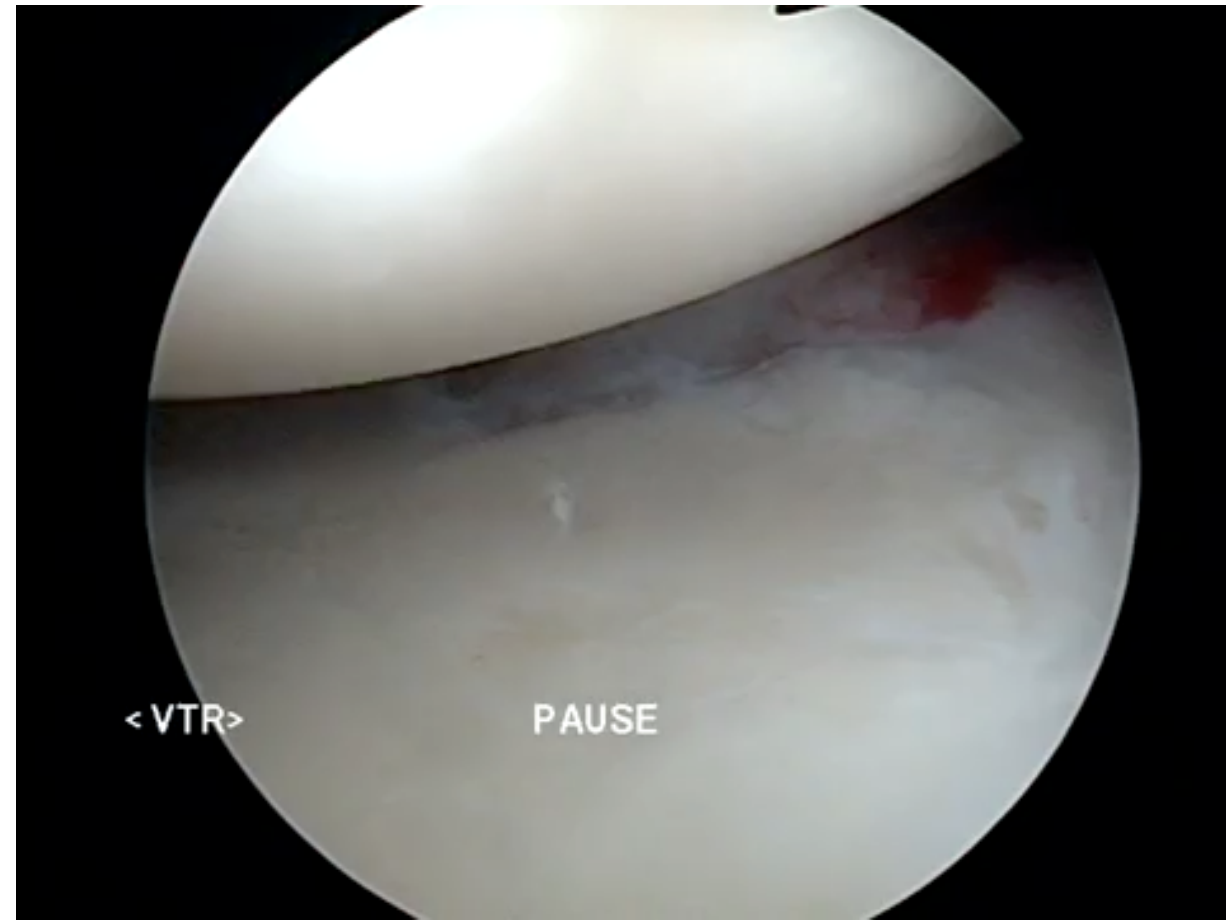
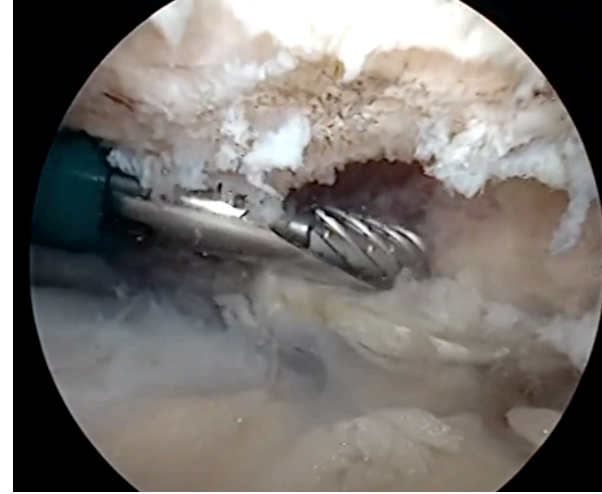

# Atrophy



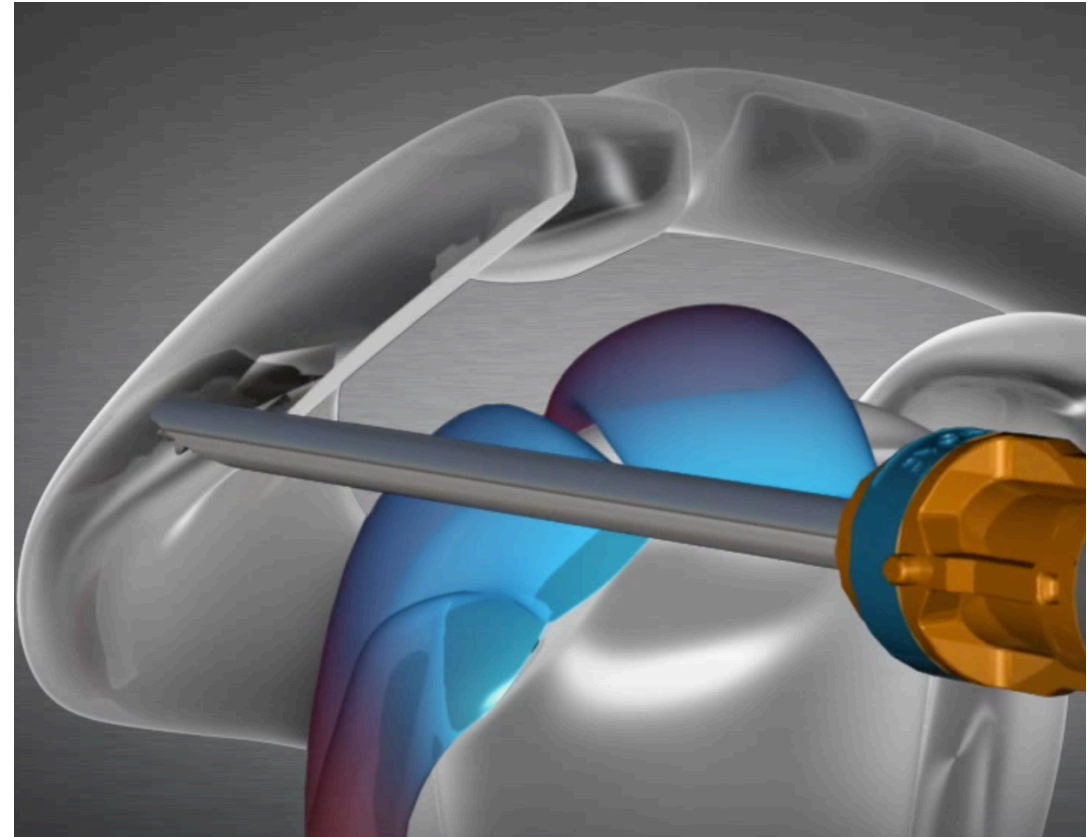
# Subacromial debridement

- Subacromial subdeltoid bursa is debrided or removed →
  - granulation tissue
  - Fluid



# Subacromial decompression

- Enlarging of subacromial space
- Osseus burring/excision of undersurface of the anterior acromion
- If arthrosis of AC is present distal clavicle resection is done
- Removal of: subacromia bursa and fat



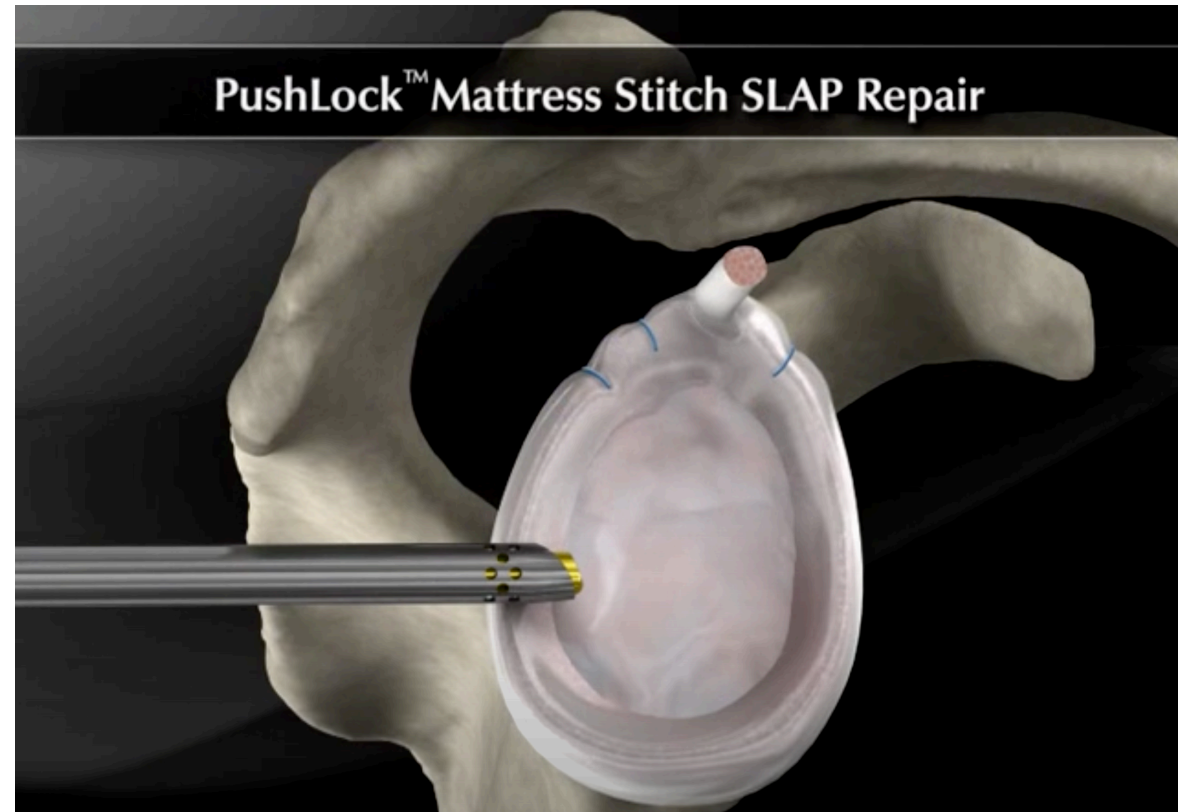[https://www.youtube.com/watch?v=Lw\\_wCAAtK\\_jM](https://www.youtube.com/watch?v=Lw_wCAAtK_jM)

# Labrum repair

## Arthrography

Extension of contrast into the labrum or in the connection labrum-cartilage

Normal postoperative labrum should be watertight



<https://www.youtube.com/watch?v=CYLvaiL6vW8>

[https://www.youtube.com/watch?v=\\_cBwzQKTL\\_M](https://www.youtube.com/watch?v=_cBwzQKTL_M)



Tack!

[pawel.szaro@vgregion.se](mailto:pawel.szaro@vgregion.se)



# Cases Shoulder

- case 1 Buford complex
- case 2 highr insertion of IGHL
- case 3 SLAP
- case 4 SLAP, impingement
- Case 5 impingement, partial rupture of SSP, Buford, complex
- Case 6 Rimrent
- Case 7 reverse Hill Sachs
- Case 8 Bony bankart
- Case 9 deltoideus signal
- Case 10 rupture: SSP, ISP, dissection of ISP, bifid LHB
- Case 11 paralabral ganglion

# Case ankle

- case 01 avulsion ATFL
- Case 02 ATFL CFL
- Case 03 ATFL
- Case 04 OCD
- Case 05 ATFL, CFL 2 st.
- Case 06 OCD
- Case 07 Achilles po post rekon
- Case 08 ATFL, Split rupture
- 09 OCD, ATFL g. 2, CFL, AiTFL
- 10 ATFL
- 11 lateral ligament rupture ATFL CFL
- 12 OCD g. 3